

Imaging Findings of Stones Left in the Abdominal Cavity Following Laparoscopic Cholecystectomy: A Series of Seven Cases and Literature Review

Juan Manuel Pérez¹, Arnaldo Andrés Brito Araújo², Carolina Pérez¹, Julián Forero¹, Paola Andrea Cifuentes Grillo³, Elkin Yasmany Cabrera Riascos³, Akram Kadamani⁴

1 Radiologist, Body Images, Department of Diagnostic Imaging at Fundación Cardio Infantil in Bogotá, Colombia.

2 Radiology Resident. Sanitas Organization in Bogotá, Colombia.

3 General Surgery Resident, Universidad de la Sabana in Bogotá, Colombia.

4 General Surgeon. Chief, General Surgery Department at Fundación Cardio Infantil in Bogotá, Colombia.

Correspondence: jmperez@cardioinfantil.org

Received: 26-09-16

Accepted: 28-07-17

Abstract

Laparoscopic cholecystectomy (LC) is the current surgical technique of choice for the treatment of symptomatic cholelithiasis. However, this procedure leads to certain complications, of which we highlight gallbladder perforation with the subsequent spillage of stones and bile into the peritoneal cavity, which may give rise to the formation of abdominal abscesses some time after the surgery.

For this reason, abandoned gallstones should be recognized as a potential source of intra-abdominal inflammatory processes, especially when there is a history of gallbladder perforation during the procedure, or in cases of conversion to open cholecystectomy and spillage of gallstones into the peritoneal cavity. Both radiologists as well as surgeons should be familiar with the imaging findings of the various diagnostic modalities such as ultrasound, CT and magnetic resonance imaging, as well as the various clinical manifestations that can present.

In this publication we present 7 cases of patients with a history of laparoscopic cholecystectomy who presented to our hospital's ER with abdominal pain and in whom the imaging findings showed the presence of perihepatic collections caused by spilled stones.

Keywords

Cholecystectomy, gallstone, cholecystitis, dropped gallstone.

INTRODUCTION

Laparoscopic cholecystectomy (LC) is the current surgical technique of choice for the treatment of cholelithiasis (1), which has decreased the number of complications compared with open cholecystectomy, associated with a reduced hospital stay and postoperative recovery period (2).

Complications of laparoscopic cholecystectomy are infrequent, although they entail a high morbidity for the patients in whom they present. One of the most common complications is gallbladder perforation with subsequent spillage of sometimes infected gallstones and bile into the peritoneal cavity, which may lead to the formation of

abscesses located anywhere from the liver subcapsule to the thorax and even expectoration of gallstones has been reported in some cases in the literature (1, 2, 3, 4, 5). Gallbladder perforation occurs in 15-40% of laparoscopic cholecystectomies (3, 6, 7, 8).

The radiologic findings of these complications have not been described much in the literature. However, there are various imaging findings which, along with clinical findings, and keeping in mind the history of LC, should alert the radiologist and the clinician to the possibility that the patient may be presenting an inflammatory reaction to abandoned gallstones, which in these cases behave like foreign bodies.

In this article we will present a series of 7 patients with a history of laparoscopic cholecystectomy who were subsequently readmitted to the emergency room at our institution presenting with abdominal pain and an intra-abdominal inflammatory process.

MATERIALS AND METHODS

This study consists of a case series of seven patients diagnosed with subcapsular hepatic abscess due to gallstones left in the cavity following laparoscopic cholecystectomy, who presented to the Fundación Cardio Infantil between 2010 and 2013. The date of the procedure as well as the date of consult for the complication was reported, noting the time lapse between the LC and the appearance of symptoms.

The medical charts of the seven patients were reviewed, including progress notes and diagnostic tests as well as microbiologic studies of abdominal fluid and blood cultures. All the imaging studies related to the diagnosis of intra-abdominal collection performed on each patient were compiled, including ultrasound (US), computerized tomography (CT) and magnetic resonance imaging (MRI).

All the ultrasounds focused on the abdominal region using GE Logiq P5 and Siemens X300 machines; the computerized tomographies were performed on Siemens Somatom Sensation 64 and Siemens Emotion 16 machines. The Philips Achieva 1.5T machine was used for the magnetic resonance imaging.

Likewise, the available surgical notes of patients undergoing surgery due to a suspected subcapsular hepatic collection secondary to abandoned gallstones were reviewed. Other notes could not be reviewed since the patients were operated on at another institution.

RESULTS

All the patients had a history of laparoscopic cholecystectomy due to cholelithiasis and cholecystitis described in the medical chart or as a prospective finding on the diagnostic imaging. In two cases the date of the LC was not obtained. In addition, the surgical descriptions of the LC were not available in any of the cases, since they were performed at other medical centers.

The range of time from LC to the appearance of symptoms was 3 months to 7 years, with a mean of 25.8 months; only one patient presented 7 years after the LC (Table 1). In 6 cases the patients presented with right upper quadrant abdominal pain; one patient presented with abdominal pain and a feeling of abdominal mass (Table 2). In no case was peritoneal irritation found on physical exam. The average time between the appearance of symptoms and diagnosis was 6 months.

Table 1. Time of symptom appearance after cholecystectomy.

Cases	Time to symptom appearance (in months)	Time from symptom appearance to definitive diagnosis (in months)
Case 1	3	1
Case 2	-	8
Case 3	18	18
Case 4	84	2
Case 5	12	-
Case 6	12	1
Case 7	-	-
Average	25,8	6

Table 2. Symptomatology

Chief complaint	No. of patients
Abdominal pain	6
Feeling of abdominal mass	1
History of hepatic abscess	2

In all 7 cases the diagnosis was made by images: 6 cases on ultrasound, 2 patients by CT scan and 2 patients with MRI. In two cases percutaneous drainage of the collection was carried out by the interventionist radiology group. However, both patients consulted again due to a recurrence of the collections. In the remaining cases percutaneous treatment was not carried out due to the precedent of relapse, and surgical management was preferred as the definitive treatment (Table 3).

Table 3. Treatment

Treatment	Number of patients
Percutaneous drainage	2
Diagnostic laparoscopy	2
Conversion to laparotomy	1
Exploratory laparotomy	2
Thoracentesis and pulmonary decortication	1

In the surgical descriptions of the repeat interventions, stones were only found in the collection of one patient; in the rest, only the presence of collections with a significant inflammatory reaction was described.

A sample of the collection was taken in all patients and sent for Gram stain and culture; the microorganisms isolated in the collection cultures were: *E. coli*, *Streptococcus viridans*, *S. aureus* and *Klebsiella oxytoca*. Microbiological data were not obtained in the remaining cases (Table 4). In one case the patient developed right thoracic empyema evidenced by cytological findings in the pleural liquid, which presented as a complication following an attempt

ted percutaneous drainage of the subhepatic collection. Cholecystectomy clips were not found in the abdominal cavity in any of the cases.

Table 4. Bacteriological isolation in collections.

Cases	Isolated microorganism
Case 1	E. Coli
Case 2	Streptococcus viridans
Case 3	N/A
Case 4	S. Aureus
Case 5	N/A
Case 6	Klebsiella oxytoca
Case 7	N/A

DISCUSSION

Beginning in 1992, the Instituto Nacional de Salud [National Health Institute] standardized laparoscopic cholecystectomy as the surgical procedure of choice for gallbladder pathologies, particularly cholelithiasis, acute cholecystitis, and biliary dyskinesia, among others. The advantages compared to open cholecystectomy are: lower postoperative pain, shorter hospital stay and rapid recovery. These characteristics give the laparoscopic approach a lower morbidity and make it more cost-effective (9).

The reported rate of complications in the world literature is 4.8%, the most morbid complication being bile duct lesions, with a rate of 0-2% (10, 11). Iatrogenic perforation of the gallbladder during laparoscopic cholecystectomy (LC) is relatively frequent, with an incidence ranging from 15% to 40%; it is associated with spillage of gallstones into the abdominal cavity, also known as abandoned gallstones, which is more common during LC compared to open cholecystectomy. The reported prevalence of abandoned gallstones during LC is 5-7% in the surgical literature. According to Fitzgibbons et al., they represent 0.1-0.8% of conversions to laparotomy (1, 2, 6, 7, 8, 12, 13).

The real incidence of major complications due to intra-peritoneal gallstones following a LC is difficult to determine due to scant reporting of gallbladder perforation in the surgical descriptions. In a recent review of 8 studies that included 24,936 laparoscopic cholecystectomies, Zehetner et al. concluded that the incidence of gallbladder perforation was 12-36%, with an incidence of gallstones spilled in the cavity of 5-19%, and a 2% frequency of lost gallstones (unrecovered). It is estimated that 8.5% of retained gallstones will lead to some complication (4, 14, 15).

Complications due to intra-peritoneal gallstones are not frequent, although on occasion they can lead to serious consequences and a high morbidity. Those most frequently associated with abandoned gallstones following laparoscopic

cholecystectomy are abdominal wall abscess 18% and intra-abdominal abscess 44%; in the latter group, subhepatic and subphrenic ones are the most frequent (Figure 1); much less frequent are thoracic ones 12% and about 10% are retroperitoneal. However, the spectrum of complications related to abandoned gallstones also includes: surgical wound infection, intestinal obstruction or perforation, cutaneous sinuses, adhesions, fistulas (bilio-cutaneous, colocutaneous, bilio colocutaneous, bilio-enteric) and jaundice (1, 4, 5, 7) (Figure 2).

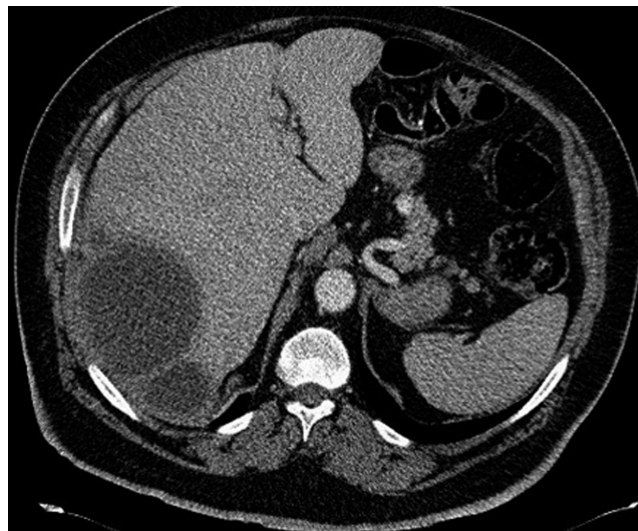

Figure 1. Abdominal CT scan with contrast. Note the subcapsular right posterior loculated fluid collection.

The time to onset of symptoms following gallstone spillage in the cavity is variable and according to a series in the literature ranges from a few months up to years, with clinical manifestations being very infrequent after 4 years. (3). In our series, the average time was 25.8 months and only one case presented after 7 years. Regarding the pathophysiology of abscess formation, it is considered that the abandoned gallstones act as foreign bodies that can be easily infected, leading to an inflammatory process which can result in the formation of abscesses in days to years following the cholecystectomy (16). Additionally, there are various known conditions that have been associated with a greater risk of gallbladder perforation during LC, especially the experience and learning curve of the surgeon, the presence of a distended gallbladder, gangrenous cholecystitis, and a long preoperative evolution of the process.

In addition, Brockman et al., in a review of 91 patients with abandoned gallstones in different locations, concluded that the risk factors for developing a complication secondary to abandoned gallstones were: acute cholecystitis with infected bile, spilling of pigmented gallstones, multiple gallstones (>15 stones), the size of the gallstones

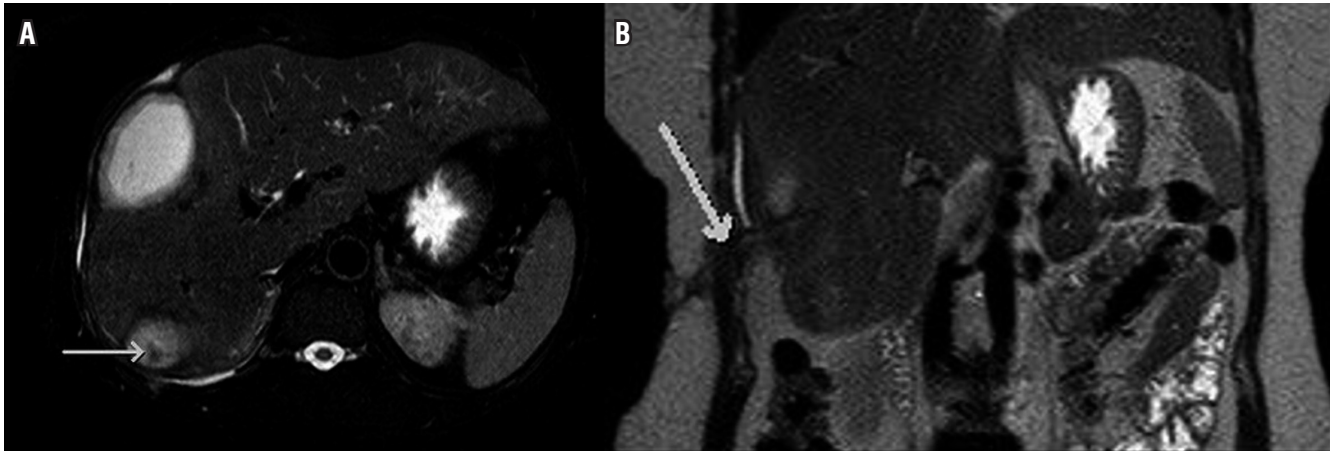


Figure 2. **A.** Axial T2 weighted with fat suppression (DRIVE) image. Notice perihepatic fluid collections with a small hypo intense defect within the posterior, likely representing spilled gallstone (arrow). **B.** Coronal T2 weighted scan, demonstrates irregular hypointensity across de lateral abdominal wall due to a fistulous tract (arrow).

(>1.5 cm), and older age. However, in a study published by Singh et al., there was no significant statistical difference between the size and number of gallstones with the occurrence of abscesses (1, 3, 6, 7, 13, 17, 18).

Likewise, numerous clinical and experimental publications have shown a greater risk of complications of abandoned gallstones, such as adhesions and intra-abdominal collections, when they are pigmented gallstones and in the presence of infected bile. Compared to cholesterol stones, pigmented gallstones are smaller and more numerous, which frequently lead to inflammation and the formation of adhesions with an increased risk of gallbladder perforation during LC and difficulties in the recovery of the spilled pigmented stones. Infectious complications are more likely to occur in bilirubinate stones because this type of stones often contains viable bacteria (1, 2, 3, 19).

The microorganisms which have been cultured and reported from stones left in the abdominal cavity associated with abscesses are *E. coli*, *Klebsiella pneumoniae*, *Streptococcus milleri*, *Pseudomonas aeruginosa*, *Serratia marcescens*, *Enterobacter cloacae*, *Hafnea alvei* or *Enterococcus faecalis*, microorganisms that may be found in the normal gastrointestinal tract flora (1, 18, 20, 21, 22). Unlike stones, dropped surgical clips seem to be a much less clinically significant finding since they are not associated with a higher risk of abscess formation and therefore do not require follow-up or surgical removal. Few cases of intra-abdominal abscesses secondary to LC surgical clips have been reported. Hussain reported two in a series of 7 patients, who presented recurrent subphrenic abscesses which had to be removed by laparotomy; this author concluded that their removal is not routinely considered due to the inert and sterile nature of these clips (2, 6, 23, 24) (Figure 3).

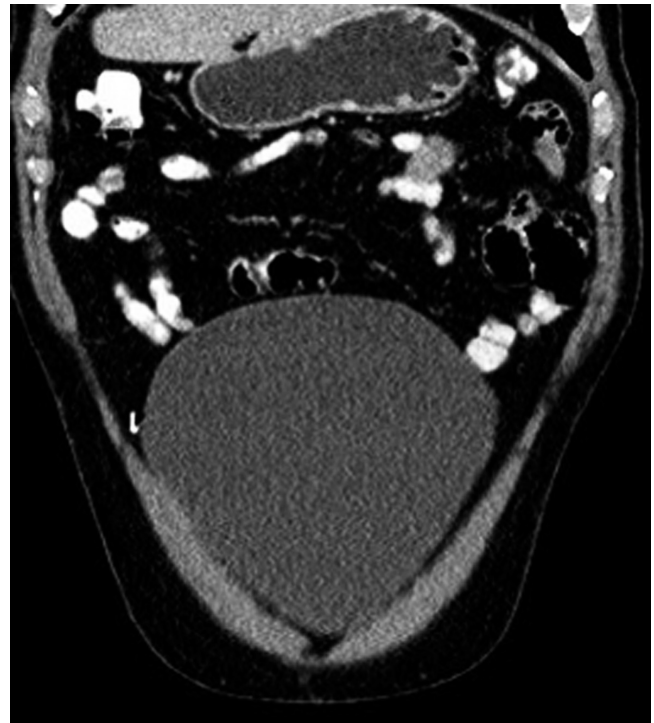


Figure 3. Coronal reconstruction in abdominal CT scan with contrast. Dropped laparoscopic metallic clip. Notice the absence of inflammatory reaction (arrow).

Regarding the imaging findings on ultrasound, the abandoned stones are seen as nodular or linear hyperechoic images with posterior acoustic shadowing (Table 5). It is known that all stones, regardless of the presence of calcium, cause this artifact on ultrasound (2, 3, 25) (Figure 4). There are only a few case series that describe the imaging characteristics on CT of stones abandoned following cholecys-

tectomy, such as heterogeneous hypodense lesions, with or without central calcification, and peripheral enhancement following the administration of contrast. They can also present as multiloculated perihepatic collections, often near Morrison's pouch or in the retroperitoneum below the subhepatic space, at times with a hyperdense image inside which corresponds to the stone (1, 6, 16, 25) (Figure 5).

Table 5. Imaging findings.

Diagnostic modality	Imaging findings of abandoned stones
Ultrasound	Nodular or linear hyperechoic images with posterior acoustic shadow of perihepatic localization. Perihepatic collection.
Abdominal tomography with contrast	Heterogeneous hypodense lesions, with or without central calcification (hyperdense) and peripheral enhancement after contrast administration. Multiloculated collections near the Morrison space or in the retroperitoneum inferior to the subhepatic space, with a hyperdense image inside, corresponding to the stones. Patterns of calcification in the abandoned stones (peripheral, central, diffuse and laminated).
Abdominal MRI with contrast	Low signal intensity focus, less than 1 cm in T1 echo gradient sequences. Hypointense lesions in the images enhanced in T2 and are iso- to hypointense in the T1-weighted images. Cholesterol stones show high signal in T1.

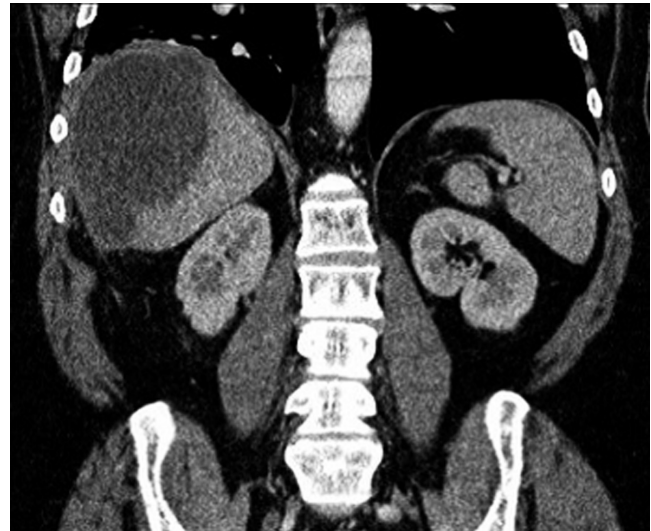

Figure 5. Coronal reconstruction of abdominal CT. Large right perihepatic fluid collection due to a dropped gallstone in a patient with history of pycholecysto and laparoscopic cholecystectomy four months ago.

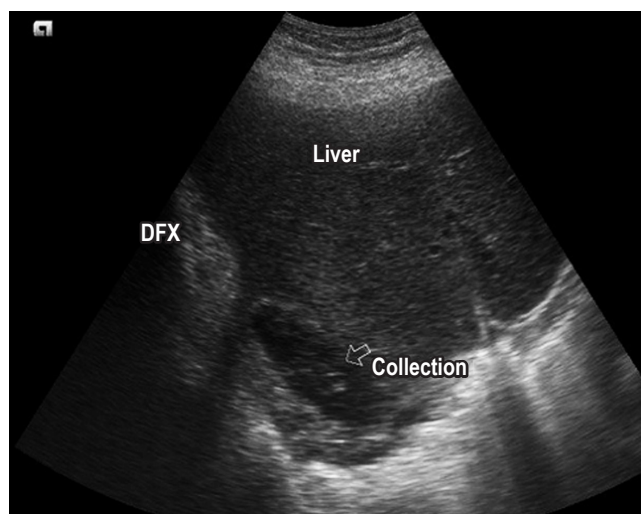


Figure 4. Abdominal ultrasound demonstrating sub phrenic fluid collection in a patient with history of dropped gallstones after laparoscopic cholecystectomy.

Pigmented stones with high calcium content are easily diagnosed with CT, while pure cholesterol stones and those with low calcium content may not be detected (25). Different calcification patterns may be seen in the abandoned stones (peripheral, central, diffuse, laminated), and they may mimic calcified peritoneal metastases (10) (Figure 6). On magnetic resonance they have been described as multiloculated subcapsular perihepatic collections, on occasion with involvement of the abdominal wall, which exhibit heterogeneous signal intensity on T2 potentiated images and on STIR sequences. A subsequent review of the MR images identified stones as a focus of low signal intensity, less than 1 cm in the T1 gradient echo sequences. Most stones are hypointense on T2 potentiated images and are iso to hypointense on T1 potentiated images, except cholesterol stones, which may show an elevated signal in T1 (3, 10, 26, 27) (Figure 7).

Various reports based on expert experience conclude that for cost and effectiveness reasons, it is advisable to perform an ultrasound or CT before an MR on a patient who develops a collection following a LC (3). The diagnosis of intra-abdominal abscesses due to stones may be confused with simple abscesses and hepatic actinomycosis. It has also been found that abscesses due to abandoned stones may mimic neoplastic processes, peritoneal metastatic disease or processes such as sclerosing peritonitis, which at times leads to a delay in diagnosis and treatment. However, the

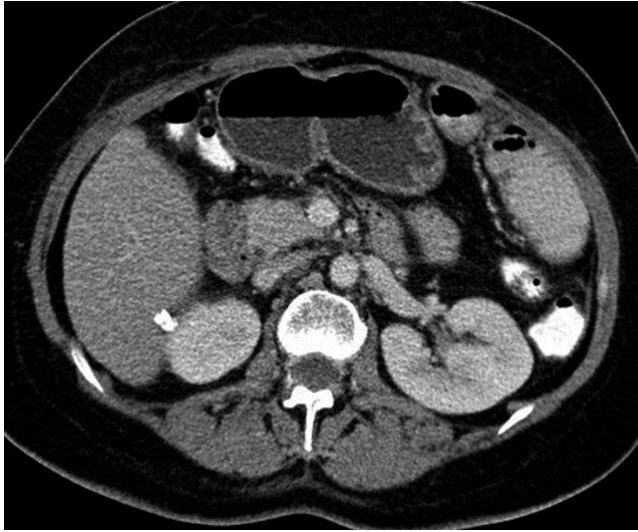


Figure 6. Abdominal CT image. Two hyper dense (*) dropped stones are seen in the hepatorenal space with no evidence of foreign body reaction.

history of laparoscopic cholecystectomy and the presence of calcification favor the diagnosis of an abandoned stone (1, 2, 3, 6, 13, 16) (Figure 8).

It is contradictory that there is no consensus on the management of stones abandoned in the abdominal cavity. This can be explained by the fact that some surgeons consider that the rate of complications is lower than the morbidity involved in the conversion of the procedure to laparotomy for the removal of the stones, when it is not technically possible to remove them via laparoscopy. Soper et al. analyzed 10,174 laparoscopic cholecystectomies where they showed that the mortality and incidence of serious complications

is significantly less than the conversion to laparotomy for removal of the stones (28). Turner et al. carried out a prospective study where they included 1528 patients who underwent laparoscopic cholecystectomy between 1992 and 2002. Gallbladder perforation and stones abandoned in the abdominal cavity occurred in 3.8% of the cases. Abandoned stones were documented in 49 patients, and 7 of these presented complications related to this event. Two of these patients presented pain or intestinal ileus that required medical management and 5 were diagnosed with intra-abdominal abscesses which were reoperated or drained percutaneously, resolving completely (29).

Rice et al. carried out a prospective study which included 1059 laparoscopic cholecystectomies, where they showed that gallbladder perforation and abdominal contamination with bile and stones was associated with a greater incidence of intra-abdominal abscesses (30). The treatment of complications related to abandoned gallstones depends, therefore, on the type of complication and symptoms they cause. However, in 90% of cases a surgical procedure is required to drain the intra-abdominal abscess and remove the stones (16, 25) (Figure 9). The rate of re-intervention due to intra-abdominal abscess recurrence is up to 32% of cases (31), which is why at our institution we consider that the ideal treatment is surgical, and percutaneous treatment is only used in those cases in which the morbidity and mortality of the surgical procedure is very high.

CONCLUSION

Abandoned stones should be recognized as a potential source of formation of intra-abdominal collections, secondary to a reaction to a foreign body, which on occasion may affect other structures such as the abdominal wall, the dia-

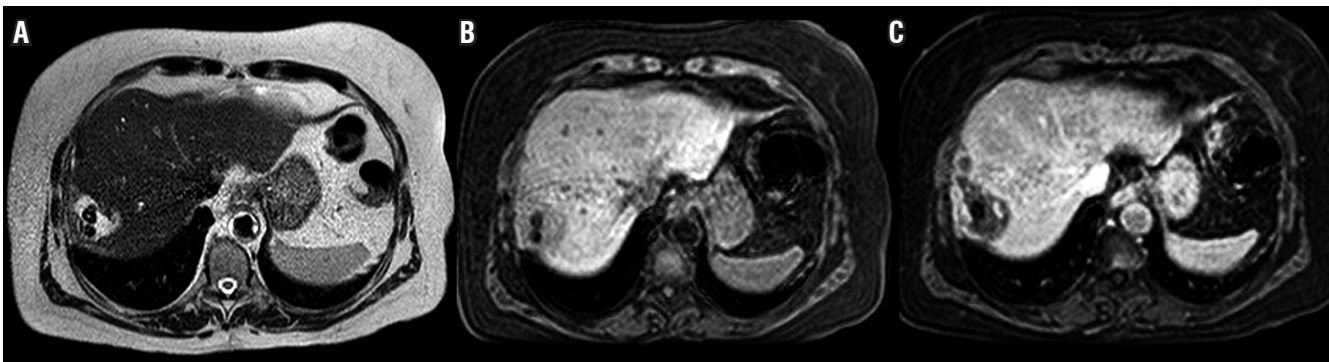


Figure 7. A-B. T1 and T2 W MRI. Perihepatic fluid collection with two hypo intense defects within it, corresponding to dropped gallstones. **C.** Post contrast MRI showing peripheral enhancement of the collection without enhancement of the stones.

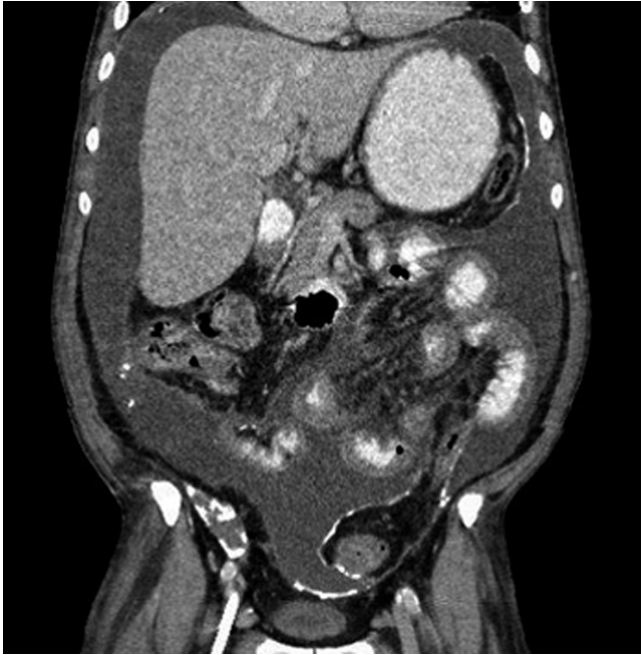

Figure 8. Coronal CT reconstruction in-patient with history of chronic renal disease. Multiple coarse peritoneal calcifications are identified secondary to retractile peritonitis.

phragm, or extend to the thorax. Although the symptoms are nonspecific, diffuse abdominal pain or right hypochondrial pain, abdominal distention in a patient with a history of LC several months or even years prior, with intra-abdominal collections, especially if they are peri-hepatic, should cause the clinician and the radiologist to suspect a reaction to a foreign body due to an abandoned stone, and there should be no doubt in cases in which the stone is identified inside a collection.

Due to the potential complications of free stones, it is essential for the surgeon to recognize a perforation during a cholecystectomy and attempt to remove all the free stones, as well as carry out an exhaustive washing of the abdominal cavity. In those patients who develop a complication to a foreign body we definitely consider that percutaneous drainage does not offer any advantage since it is not a definitive treatment due to the high incidence of recurrence. Therefore, surgical treatment with extensive washing of the cavity is the procedure of choice.

Financial support and disclosure

Nothing to disclose.

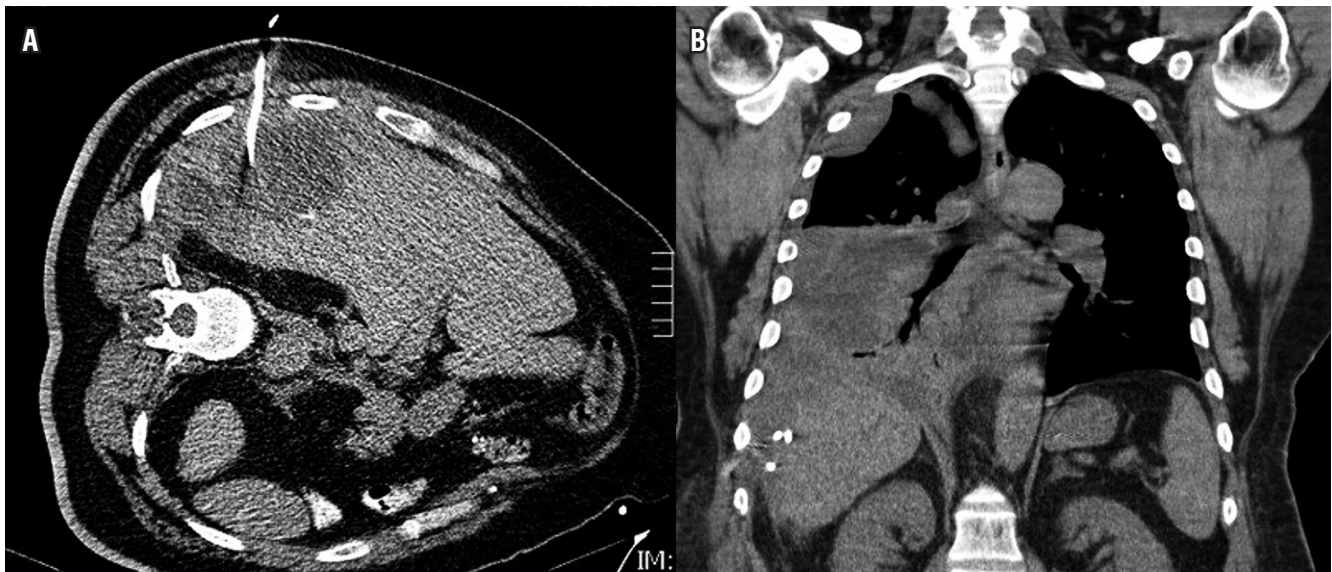

Figure 9. A. Failed percutaneous drainage in a patient with dropped gallstones and sup phrenic fluid collection. B. Chest CT performed 24 hours, demonstrates right pleural effusion after abdominal drainage. Notice the subcapsular location of the end of the pigtail (*).

REFERENCES

1. Castellón CJ, Fernández M, Morales S, et al. Absceso subhepático como complicación tardía de un cálculo intraperitoneal abandonado tras una colecistectomía laparoscópica. *Gastroenterol Hepatol.* 2004;27(10):568-72. Doi: <https://doi.org/10.1157/13069130> / [https://doi.org/10.1016/S0210-5705\(03\)70534-2](https://doi.org/10.1016/S0210-5705(03)70534-2)

toneal abandonado tras una colecistectomía laparoscópica. *Gastroenterol Hepatol.* 2004;27(10):568-72. Doi: <https://doi.org/10.1157/13069130> / [https://doi.org/10.1016/S0210-5705\(03\)70534-2](https://doi.org/10.1016/S0210-5705(03)70534-2)

2. Atri M, Bonifacio A, Ryan M, et al. Dropped gallstones post laparoscopic cholecystectomy mimicking peritoneal seeding: CT and ultrasound features. *J Comput Assist Tomogr.* 2002;26(6):1000-5. Doi: <https://doi.org/10.1097/00004728-200211000-00025>
3. Morrin MM, Kruskal JB, Hochman MG, et al. Radiologic features of complications arising from dropped gallstones in laparoscopic cholecystectomy patients. *AJR Am J Roentgenol.* 2000;174(5):1441-5. Doi: <https://doi.org/10.2214/ajr.174.5.1741441>
4. Zehetner J, Shamiyeh A, Wayand W. Lost gallstones in laparoscopic cholecystectomy: all possible complications. *Am J Surg.* 2007;193(1):73-8. Doi: <https://doi.org/10.1016/j.amjsurg.2006.05.015>
5. Werber YB, Wright CD. Massive hemoptysis from a lung abscess due to retained gallstones. *Ann Thorac Surg.* 2001;72:278-80. Doi: [https://doi.org/10.1016/S0003-4975\(00\)02563-7](https://doi.org/10.1016/S0003-4975(00)02563-7)
6. Singh AK, Levenson RB, Gervais DA, et al. Dropped gallstones and surgical clips after cholecystectomy: CT assessment. *J Comput Assist Tomogr.* 2007;31(5):758-62. Doi: <https://doi.org/10.1097/RCT.0b013e3180340358>
7. Zaliekas J, Munson JL. Complications of gallstones: the Mirizzi syndrome, gallstone ileus, gallstone pancreatitis, complications of "lost" gallstones. *Clin North Am.* 2008;88(6):1345-68. Doi: <https://doi.org/10.1016/j.suc.2008.07.011>
8. Suyapto D, Tian-Hui J. Complications of retained intraperitoneal gallstones from laparoscopic cholecystectomy. *Surg Laparosc Endosc Percutan Tech.* 2006;16(3):167-8. Doi: <https://doi.org/10.1097/00129689-200606000-00010>
9. Khan M, Khatri M, Oonwala Z. Knowledge and practices of general surgeons and residents regarding spilled gallstones lost during laparoscopic cholecystectomy: a cross sectional survey. *Patient Safety in Surgery.* 2013;7:27. Doi: <https://doi.org/10.1186/1754-9493-7-27>
10. Eikermann M, Siegel R, Broeders I, et al. Prevention and treatment of bile duct injuries during laparoscopic cholecystectomy: the clinical practice guidelines of The European Association for Endoscopic Surgery (EAES). *Surg Endosc.* 2012;26(11):3003-39. Doi: <https://doi.org/10.1007/s00464-012-2511-1>
11. Randal Pérez LJ, Fernando Parra J, Aldana Dimas G. The safety of early laparoscopic cholecystectomy (<48 hours) for patients with mild gallstone pancreatitis: a systematic review of the literature and meta-analysis. *Cir Esp.* 2013. Doi: <https://doi.org/10.1016/j.ciresp.2013.01.024>
12. Whiting J, Welch Nt, Hallissey MT. Subphrenic abscess caused by gallstones "lost" at laparoscopic cholecystectomy one year previously: Management by minimally invasive techniques. *Surg Laparosc Endosc.* 1997;7(1):77-8. Doi: <https://doi.org/10.1097/00019509-199702000-00022>
13. Fitzgibbons RJ, Annibaldi R, Litke BS. Gallbladder perforation and gallstone removal: open versus closed laparoscopy and pneumoperitoneum. *Am J Surg.* 1993;165:497-504. Doi: [https://doi.org/10.1016/S0002-9610\(05\)80949-3](https://doi.org/10.1016/S0002-9610(05)80949-3)
14. Karabulut N, Tavaslı B, Kiroğlu Y. Intra-abdominal spilled gallstones simulating peritoneal metastasis: CT and MR imaging features (2008: 1b). *Eur Radiol.* 2008;18(4):851-4. Doi: <https://doi.org/10.1007/s00330-007-0703-1>
15. Habib E, Elhadad A. Digestive complications of gallstones lost during laparoscopic cholecystectomy. *HPB (Oxford).* 2003;5(2):118-22. Doi: 10.1080/13651820310016463.
16. Gayer G, Petrovitch I, Jeffrey RB. Foreign objects encountered in the abdominal cavity at CT. *Radiographics.* 2011;31(2):409-28. Doi: <https://doi.org/10.1148/rg.312105123>
17. Dida K, Mostafa G. Complications of spilled gallstones after laparoscopic cholecystectomy. *Am Surg.* 2013;79(3):E106-7.
18. Brockmann JG, Kocher T, Senninger NJ, et al. Complications due to gallstones lost during laparoscopic cholecystectomy. *Surg Endosc.* 2002;16(8):1226-32. Doi: <https://doi.org/10.1007/s00464-001-9173-8>
19. Van Mierlo PJ, De Boer SY, Van Dissel JT, et al. Recurrent staphylococcal bacteraemia and subhepatic abscess associated with gallstones spilled during laparoscopic cholecystectomy two years earlier. *Neth J Med.* 2002;60(4):177-80.
20. Memon MA, Deek RK, Maffi TR, et al. The outcome of unretrieved gallstones in the peritoneal cavity during laparoscopic cholecystectomy. *Surg Endosc.* 1999;13:848-57. Doi: <https://doi.org/10.1007/s004649901118>
21. Schäfer M, Suter C, Klaiber Ch, et al. Spilled gallstones after laparoscopic cholecystectomy. A relevant problem? A retrospective analysis of 10,174 laparoscopic cholecystectomies. *Surg Endosc.* 1998;12:305-9. Doi: <https://doi.org/10.1007/s004649900659>
22. Horton M, Florence MG. Unusual abscess patterns following dropped gallstones during laparoscopic cholecystectomy. *Am J Surg.* 1998;175:375-9. Doi: [https://doi.org/10.1016/S0002-9610\(98\)00048-8](https://doi.org/10.1016/S0002-9610(98)00048-8)
23. Iannitti DA, Varker KA, Zaydfudim V, et al. Subphrenic and pleural abscess due to spilled gallstones. *JLS.* 2006;10(1):101-4.
24. Hussain S. Sepsis from dropped clips at laparoscopic cholecystectomy. *Eur J Radiol.* 2001;40(3):244-7. Doi: [https://doi.org/10.1016/S0720-048X\(00\)00163-7](https://doi.org/10.1016/S0720-048X(00)00163-7)
25. Nayak L, Menias CO, Gayer G. Dropped gallstones: spectrum of imaging findings, complications and diagnostic pitfalls. *Br J Radiol.* 2013;86(1028):20120588. Doi: <https://doi.org/10.1259/bjr.20120588>
26. Helme S, Samdani T, Sinha P. Complications of spilled gallstones following laparoscopic cholecystectomy: a case report and literature overview. *J Med Case Rep.* 2009;3:8626. Doi: <https://doi.org/10.4076/1752-1947-3-8626>
27. Birkitt DH. Spilled cells, spilled clips, spilled stones. Editorial. *Surg Endosc.* 1995;9:269-71. Doi: <https://doi.org/10.1007/BF00187766>
28. Soper NJ, Dunnegan DL. Does intraoperative gallbladder perforation influence the early outcome of laparoscopic cholecystectomy? *Surg Laparosc Endosc.* 1991;1:156-61.
29. Tumer A, Yüksek Y, Yastı A, et al. Dropped gallstones during laparoscopic cholecystectomy: the consequences. *World J Surg.* 2005;29:437-40. Doi: <https://doi.org/10.1007/s00268-004-7588-9>

30. Rice DC, Memon MA, Jamison RL, et al. Long-term consequences of intraoperative spillage of bile and gallstones during laparoscopic cholecystectomy. *J Gastrointest Surg.* 1997;1:85-91. Doi: <https://doi.org/10.1007/s11605-006-0014-x>
31. Castellón-Pavón C, Morales-Artero S, Martínez-Pozuelo A, et al. Complicaciones por cálculos y clips intraabdominales abandonados durante una colecistectomía laparoscópica. *Cir Esp.* 2008;84(1):3-9. Doi: [https://doi.org/10.1016/S0009-739X\(08\)70596-7](https://doi.org/10.1016/S0009-739X(08)70596-7)