

# Pouchitis, a complication associated with the surgical treatment of ulcerative colitis. Diagnosis and treatment. Review

William Otero-Regino,<sup>1\*</sup>  Lina Otero-Parra,<sup>2</sup> Guillermo Veitia.<sup>3</sup>

## OPEN ACCESS

### Citation:

Otero-Regino W, Otero-Parra L, Veitia G. Pouchitis, a complication associated with the surgical treatment of ulcerative colitis. Diagnosis and treatment. Review. Rev Colomb Gastroenterol. 2021;36(1):65-72. <https://doi.org/10.22516/25007440.426>

<sup>1</sup> Professor of Medicine, Universidad Nacional de Colombia.

<sup>2</sup> Internist, Gastroenterologist, Universidad Nacional de Colombia. Gastroenterologist, Centro de Enfermedades Digestivas.

<sup>3</sup> Head of Gastroenterology, Hospital Vargas de Caracas. Professor, Universidad Central de Venezuela.

\*Correspondence: William Otero.  
[waoteror@gmail.com](mailto:waoteror@gmail.com)

Received: 23/05/19

Accepted: 12/11/20



## Abstract

Between 20 % and 30 % of patients with ulcerative colitis (UC) undergo surgery because it is not treatable or because it is associated with a fulminant course, dysplasia, or colon cancer. The surgery of choice is proctocolectomy with ileal-anal pouch. However, 20 %-50 % of patients present with pouchitis 10 years after surgery. The diagnosis is made based on clinical manifestations, endoscopic alterations, and histology. The drugs used in the treatment of UC are not as effective in pouchitis and the first-line treatment is antibiotics administration. Depending on the initial response and clinical course of the condition, subsequent treatment will be chosen. This review discusses the most important aspects of the epidemiology, diagnosis, pathogenesis, and treatment of pouchitis.

## Keywords

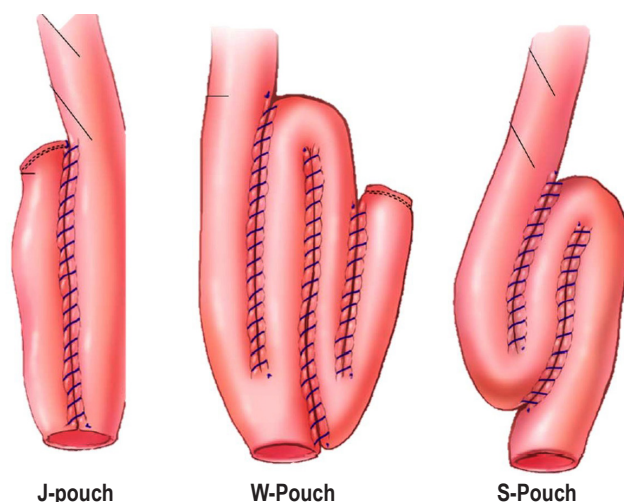
Ulcerative colitis, Pouchitis, Antibiotics, Prophylaxis.

## INTRODUCTION

Ulcerative colitis (UC) is an autoinflammatory, multifactorial disease that produces chronic inflammation of the colon mucosa, with frequent extraintestinal manifestations; besides it has a variable clinical course and relapse is common in these patients (1). The current therapeutic approach has reduced the need for surgery, somehow 20 % (2) to 30 % (3) of patients with UC must undergo surgery, either because of intractability, fulminant course, development of dysplasia or colon cancer (2, 3). Proctocolectomy

and ileoanal pouch is the surgery of choice (4). This procedure was first described by Park et al. in 1978 (5). A functioning pouch is observed in 93% of patients 30 years after surgery (6). “J-pouch”, “W-pouch” and “S-pouch” are the main types of pouch (**Figure 1**) (7), being “J-pouch” the most frequently performed (7).

After surgery, a persistent inflammation of the pouch, known as *pouchitis*, may occur, as well as non-inflammatory complications (**Table 1**) (4-6). The review conducted in this paper specifically focuses on pouchitis, as it is the most frequent complication associated with ileoanal pouch surgery (5, 6).



**Figure 1.** Main types of pouch. Modified from reference 7.

**Table 1.** Differential diagnosis of pouchitis

Inflammation of the remaining rectal mucosa (cuffitis)
Infectious diarrhea due to CMV or <i>C. difficile</i>
Pouch stricture
Pouch ischemia
Crohn's disease of the pouch (there will be inflammatory alterations in proximal areas)
Adhesions
Pelvic floor dysfunction
Poor absorption of bile salts
Pouch emptying alteration
Autoimmune pouchitis

## EPIDEMIOLOGY

The incidence of pouchitis varies over time. At 1, 5 and 10 years, its incidence is 20%, 40% and 50%, respectively (8). At 30 years after surgery, it may affect 80% of patients (6). These figures contrast with the low incidence of pouchitis (0-10%) described in patients who underwent the same surgery but due to familial adenomatous polyposis (9).

## PATHOGENESIS

The exact pathophysiological mechanisms that cause pouchitis are unknown. However, it is more likely to be a multifactorial disease involving genetic predisposition, bacterial overgrowth and dysbiosis in the ileal pouch, among others (9). Recently, it has been found that in acute pouchitis

cases there is an increase of species of the *Clostridia* genus and, reciprocally, its decrease is associated with response to antibiotic treatment (10). In contrast, in chronic pouchitis cases there is an increase in the amount of *Staphylococcus aureus* (10). Other factors involved in its development may include decreased short-chain fatty acids, nutritional deficiencies, ischemia or immune response alterations (10-13). In addition, other authors have considered that pouchitis may be a different inflammatory bowel disease (14) and that several factors increase the risk of developing it (15-18). The use of nonsteroidal anti-inflammatory drugs (NSAIDs) increases this risk 3.24 times (95 % confidence interval [CI] 1.71-6.13) (15).

Similar to ulcerative colitis, smoking has been found to have a negative association and smoking cessation increases the risk of pouchitis, however this does not mean that people should start smoking to avoid developing it, as smoking has multiple harmful effects on humans and recently it has been reported that active smoking does not prevent the occurrence of this complication (16). When primary sclerosing cholangitis and UC occur concurrently, there is a higher risk of pouchitis than when UC occurs alone (17). High levels of perinuclear fluorescence pattern anti-neutrophil cytoplasmic antibody (p-ANCA) represent a risk of pouchitis of 8.5 (17). According to a recent meta-analysis, the presence of p-ANCA was associated with increased risk of chronic pouchitis (Odds ratio [OR]: 1.8; 95 % CI: 1.2-2.6), but it was not associated with acute pouchitis (18). However, it should be noted that p-ANCA determination was performed after surgery in most of the studies included in said meta-analysis.

## DIAGNOSIS

Pouchitis diagnosis is made based on the combination of clinical manifestations, endoscopic alterations (pouchoscopy) and histological findings (19, 20). At least 7 points are required for its diagnosis (21). In terms of severity, it may be mild, moderate or severe (19). In some cases, imaging studies of the abdomen and pelvis are necessary (20, 22). There are no specific clinical manifestations of pouchitis (12). Clinically, there is an increase in the number of bowel movements, along with the presence of mucus, abdominal pain, tenesmus, incontinence and nocturnal symptoms (12, 22). Rectal bleeding is more suggestive of inflammation of the remaining rectal mucosa (cuffitis) (20). However, the inflammation of said rectal mucosa may actually be a recurrence of ulcerative colitis (20). Systemic manifestations such as fever, chills and weight loss most frequently suggest an infection of the pouch (infectious pouchitis) by *Clostridium difficile* or cytomegalovirus (CMV) (12, 20). Usually, patients with ileoanal pouch have 4 to 7

bowel movements per day (12, 22), and some even up to 20, so that the increased frequency of bowel movements alone is not suggestive of pouchitis. Its differential diagnosis includes several diseases (**Table 1**) (12, 20, 22).

Endoscopic findings include erythema, edema, friability, granularity, spontaneous bleeding or bleeding on contact with the endoscope, ulcers, inflammatory polyps, mucosal bridges and decreased distensibility (22). The presence of ulcers or erosions on the anastomosis alone is not suggestive of pouchitis (20). Biopsies should be performed by taking samples from the pouch and the proximal loop of the ileum; samples from the suture line must be avoided (20). Although the inflammation is located in the ileal pouch, sometimes it extends more proximally and affects the ileum proximal to the pouch (12, 20). The involvement of the ileum proximal to the pouch is known as pre-pouch ileitis, which was first described by Bell et al. (23) in a retrospective study conducted in patients with UC who had been treated surgically and had undergone total colectomy with ileoanal pouch. In said study, concomitant pouchitis was reported in half of the patients, and granulomas were found in one case according to the histopathology reported, which is a very important finding, since Crohn's disease can be erroneously diagnosed (23).

Inflammatory infiltrate with polymorphonuclear infiltrates, crypt abscesses and ulcers are found in biopsy reports (23, 24). Additionally, chronic changes, flattening of the ileal mucosa villi leading to villous atrophy (intestinal metaplasia), and chronic inflammatory infiltrate are also found (12, 20, 22). If there are no acute inflammatory changes, pouchitis cannot be diagnosed, since chronic stasis of fecal matter in the pouch produces chronic inflammatory changes (25, 26). Basophilic and eosinophilic inclusions are findings suggestive of CMV infection (12, 20). The final diagnosis of this infection is based on the positive detection of CMV by immunohistochemistry (20, 22). Apoptosis in the crypts is suggestive of autoimmune pouchitis (27). Non-homogeneous or asymmetric inflammation suggests ischemic pouchitis (12, 20, 27). When pouch stricture is identified, endoscopic balloon dilatation is the treatment of choice due to its efficacy and safety (28).

## RISK OF DYSPLASIA AND CANCER

The risk of dysplasia in the pouch is extremely rare when there is no neoplasia or dysplasia before undergoing this surgery (29). In this regard, a study reported that dysplasia occurred only in 1 % of patients 10 to 15 years after surgery (29); besides, according to a more recent research, the risk of cancer was 1.3% (30). On the other hand, when there is dysplasia or cancer before surgery, the risk of neoplasia increases substantially as follows: in the case of periopera-

tive dysplasia, the hazard ratio (HR) is 3.76 (95 % CI: 1.39-10.19), while in patients with previous cancer, it is 24.69 (95 % CI: 9.61-63.42) (30). In these patients, performing endoscopic surveillance of the pouch annually is recommended. On the other hand, the performance of endoscopic surveillance of the pouch, along with biopsies, every 1 to 3 years is recommended in patients with a 10-year history of UC before undergoing ileoanal pouch surgery and with one of following risk factors: chronic pouchitis, cuffitis, family history of colon cancer in first-degree relatives, and primary sclerosing cholangitis (20). If the aforementioned risk factors are not present, surveillance is performed every 3 years, starting 10 years after the UC diagnosis is reached (20).

## CLINICAL COURSE AND CLASSIFICATION

The classification of pouchitis based on endoscopic examination, histology, clinical course, duration, response to antibiotics, and number of episodes per year is shown in **Table 2** (22, 31, 32).

**Table 2.** Types of pouchitis

<b>Clinical course</b>	Acute: < 4 weeks Chronic: > 4 weeks, 10 %-15%
<b>Response to antibiotics</b>	Antibiotic responder Non-responder to antibiotics Antibiotic dependent (3 episodes per year) Antibiotic-refractory pouchitis
<b>Episodes per year</b>	Infrequent: 3 episodes per year Frequent: > 3 episodes per year
<b>Secondary to another disease</b>	Ischemia, CMV, autoimmune associated with IgG4, short-chain fatty acids deficiency, Crohn's disease, <i>C. difficile</i> , NSAID. These categories are not mutually exclusive.

IgG4: Immunoglobulin G 4.

## TREATMENT

Drugs typically used to treat ulcerative colitis do not have similar efficacy when used in the treatment of pouchitis (7, 22, 33, 34). Antibiotics are the cornerstone of the management of pouchitis, and the implementation of additional strategies depends on failure of this first-line therapy (7, 12-14, 20, 22). Considering its high incidence and clinical course, management can be divided into primary prophylaxis with probiotics, on the one hand, and treatment of acute pouchitis with antibiotics, on the other (7, 12-14, 20). According to their response to antibiotic therapy, patients are classified as antibiotic responders, antibiotic dependent (3 episodes per year) and refractory to antibio-

tics (12-14, 20, 22), being the latter treated with a step up combination of antibiotics: budesonide, biological therapy with anti-tumor necrosis factor agents (anti-TNF: infliximab, adalimumab) or anti-integrins (vedolizumab), and even long-term high-dose probiotics. 60-80 % of refractory patients benefit from this step up strategy. However, 1-2% end up with a permanent ileostomy (22).

Pouchitis management can be divided into primary prophylaxis, treatment of acute pouchitis, treatment of antibiotic-dependent pouchitis and treatment of chronic pouchitis.

### Primary prophylaxis

Several studies have looked into the efficacy of probiotics to prevent the occurrence of pouchitis. However, results are inconsistent and, therefore, there is no definitive evidence about their efficacy (31, 35-39). In this sense, two studies reported a lower incidence of pouchitis in the group of patients who were administered probiotics (34, 35, 40). In the study by Gionchetti (35), conducted in 40 individuals, pouchitis occurred in 10 % of patients receiving probiotics, compared to 40 % of those in the placebo group. In the study by Yasueda, (40), conducted in 17 patients, 1 patient out of 9 in the probiotic group developed pouchitis after a 2-year follow-up period, compared to 4 out of 8 in the placebo group. On the contrary, in another study conducted in 30 patients there were no significant differences between both groups (40).

### Treatment of acute pouchitis

Antibiotics are the cornerstone of the treatment of this type of pouchitis (7). Initial use of ciprofloxacin (500 mg every 12 hours for 14 days) is recommended (12, 14, 20, 22). Metronidazole or tinidazole (500 mg every 12 hours) are other options (12, 14, 22, 40). Most patients respond rapidly to this therapy. Ciprofloxacin use is preferred because of its greater efficacy and the fact it causes fewer side effects (12, 22). Most patients respond to this initial empirical therapy; however, at least 60% experience one episode of recurrence (22). Ciprofloxacin is more effective than metronidazole (100 % vs. 33 %) (22). Response to antibiotics supports the idea that dysbiosis may be involved in the development of pouchitis. Patients who fail to respond to the initial antibiotic therapy may receive a new course of the same antibiotics for 4 weeks, either based on culture results, or empirically by combining ciprofloxacin (500 mg every 12 hours) with metronidazole or tinidazole (each 500 mg every 12 hours), or with rifaximin (550 mg every 12 hours) (12, 20, 22, 40). Depending on their response or failure to respond to antibiotics, patients can be prospectively classified as described below.

### Antibiotic-dependent pouchitis

Patients who have an initial response to antibiotics, but have 3 or more relapses per year are considered to have this type of pouchitis. The recommended treatment for these patients consists of the permanent administration once or twice per day of antibiotics at low doses, such as ciprofloxacin 200 to 500 mg/day or rifaximin 200 to 550 mg. In a recent study, only 21% of patients who chronically received antibiotics experienced an improvement at one year of treatment, 28% experienced adverse effects associated with the use of antibiotics, and antimicrobial resistance was identified in 78% of patients (33). This low efficacy raises the need for different treatments, including the use of biologics and even probiotics with VSL # 3 at 6-9 g/day doses (12, 20, 22).

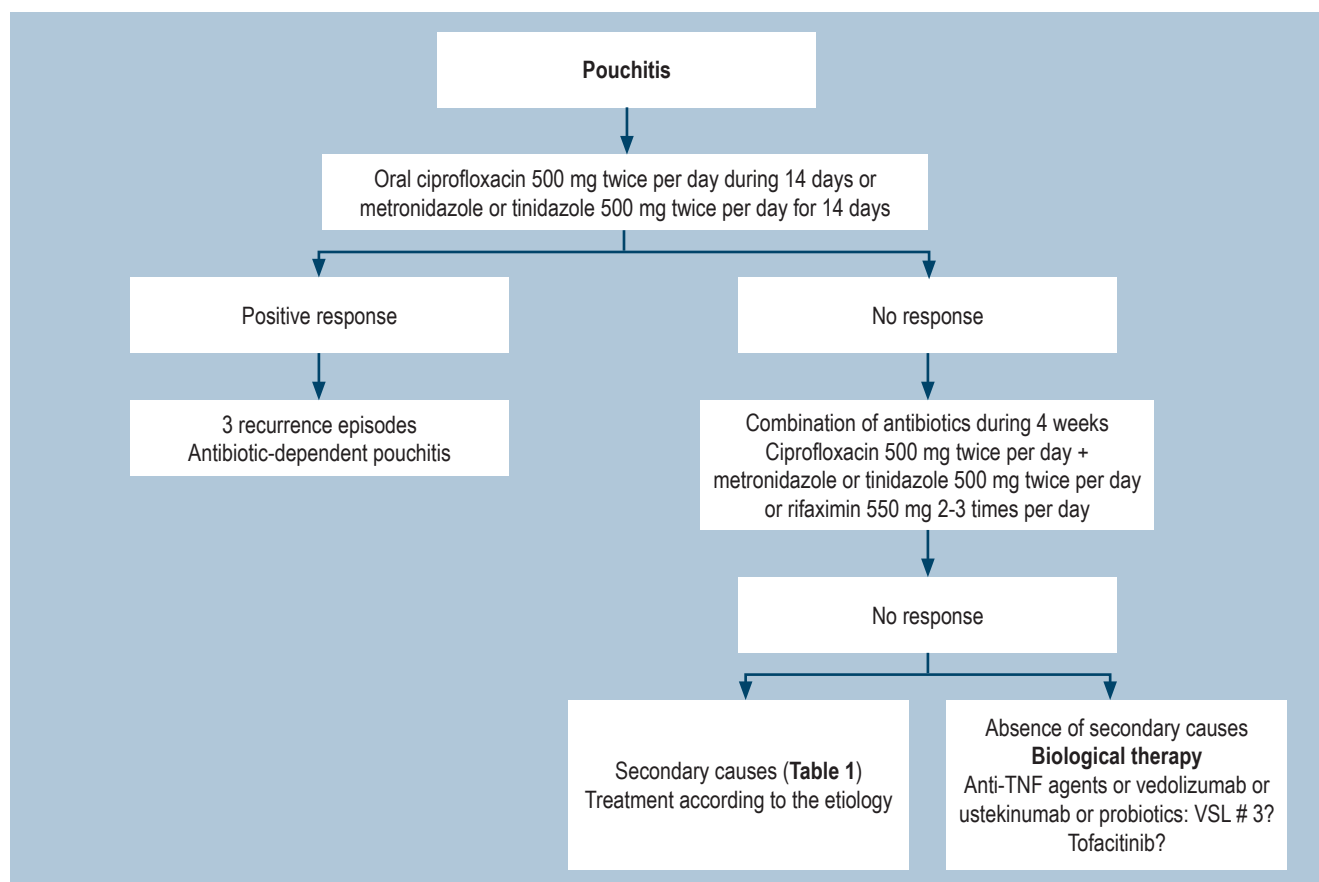
### Chronic antibiotic-refractory pouchitis

There is no unanimous definition of chronic antibiotic-refractory pouchitis. However, it is widely considered that patients with symptoms for at least 4 weeks and who have failed to respond to antibiotic management have this type of pouchitis. Chronic antibiotic-refractory pouchitis occurs in 10-15% of patients with pouchitis. In these cases, ruling out secondary non-inflammatory causes, including mechanical ones (ischemia, stenosis, fistulas, lack of the "J-pouch" tip, among others), is required (22). In addition, NSAIDs administration must be always suspended. In cases of CMV infection, treatment would consist of ganciclovir administration (22, 31). If there are no secondary causes, chronic antibiotic-refractory pouchitis can be managed with immunosuppressants such as budesonide or betamethasone (12, 22); biological therapies such as anti-TNF (infliximab or adalimumab) (41) or vedolizumab therapy (42) are another option for treating these patients, as well as those with antibiotic-dependent pouchitis. Some case reports have described benefits derived from the use of ustekinumab (43) and recently, benefits associated with tofacitinib use have been reported in antibiotic-refractory pouchitis cases (44).

When inflammation occurs in both the pouch and the proximal ileum, oral budesonide is the treatment of choice (12, 22). The clinical manifestations of cuffitis or inflammation of the remaining rectal mucosa are similar to those of pouchitis, with the exception that bleeding is more frequent (12, 20). The treatment of choice consists of topical 5-aminosalicylic acid (5-ASA) (suppositories) and, if the patient fails to respond to this therapy, adding oral mesalazine is recommended (20, 22). An algorithm of the general management of pouchitis is shown in **Figure 2**.

Surgical treatment is a salvage therapy option when medical treatment fails (34). The purpose of surgery is to resect the pouch (pouchectomy) and perform a permanent





**Figure 2.** Management of pouchitis.

ileostomy (7, 22, 34). The proportion of patients undergoing this surgery due to the loss of pouch is unknown, but it has been estimated that it may be necessary in 25% of patients (45, 46).

Cuffitis refractory to medical treatment can often be accompanied by ischemia and patients with these two

diseases, as well as those with collagenous cuffitis, are considered candidates for transanal mucosectomy or even dys-functionalization of the pouch (7, 22, 34).

Fecal transplantation has been used in cases of chronic refractory pouchitis; however, so far the available evidence is scarce and limited to case series (47).

## REFERENCES

1. Park H, Bourla AB, Kastner DL, Colbert RA, Siegel RM. Lighting the fires within: the cell biology of autoinflammatory diseases. *Nat Rev Immunol.* 2012;12(8):570-80. <https://doi.org/10.1038/nri3261>
2. Parragi L, Fournier N, Zeitz J, Scharl M, Greuter T, Schreiner P, Misselwitz B, Safroneeva E, Schoepfer AM, Vavricka SR, Rogler G, Biedermann L; Swiss IBD Cohort Study Group. Colectomy Rates in Ulcerative Colitis are Low and Decreasing: 10-year Follow-up Data From the Swiss IBD Cohort Study. *J Crohns Colitis.* 2018;12(7):811-818. <https://doi.org/10.1093/ecco-jcc/jjy040>
3. Frolkis AD, Dykeman J, Negrón ME, Debruyne J, Jette N, Fiest KM, Frolkis T, Barkema HW, Rioux KP, Panaccione R, Ghosh S, Wiebe S, Kaplan GG. Risk of surgery for inflammatory bowel diseases has decreased over time: a systematic review and meta-analysis of population-based studies. *Gastroenterology.* 2013;145(5):996-1006. <https://doi.org/10.1053/j.gastro.2013.07.041>

4. Parks AG, Nicholls RJ. Proctocolectomy without ileostomy for ulcerative colitis. *Br Med J*. 1978;2(6130):85-8. <https://doi.org/10.1136/bmj.2.6130.85>
5. Fazio VW, Kiran RP, Remzi FH, Coffey JC, Heneghan HM, Kirat HT, Manilich E, Shen B, Martin ST. Ileal pouch anal anastomosis: analysis of outcome and quality of life in 3707 patients. *Ann Surg*. 2013;257(4):679-85. <https://doi.org/10.1097/SLA.0b013e31827d99a2>
6. Lightner AL, Mathis KL, Dozois EJ, Hahnsloser D, Loftus EV Jr, Raffals LE, Pemberton JH. Results at Up to 30 Years After Ileal Pouch-Anal Anastomosis for Chronic Ulcerative Colitis. *Inflamm Bowel Dis*. 2017;23(5):781-790. <https://doi.org/10.1097/MIB.0000000000001061>
7. Quinn KP, Raffals LE. An Update on the Medical Management of Inflammatory Pouch Complications. *Am J Gastroenterol*. 2020;115(9):1439-1450. <https://doi.org/10.14309/ajg.0000000000000666>
8. Athayde J, Davies SC, Parker CE, Guizzetti L, Ma C, Khanna R, Feagan BG, Jairath V. Placebo Rates in Randomized Controlled Trials of Pouchitis Therapy. *Dig Dis Sci*. 2018;63(10):2519-2528. <https://doi.org/10.1007/s10620-018-5199-9>
9. Schieffer KM, Williams ED, Yochum GS, Koltun WA. Review article: the pathogenesis of pouchitis. *Aliment Pharmacol Ther*. 2016;44(8):817-35. <https://doi.org/10.1111/apt.13780>
10. Segal JP, Oke S, Hold GL, Clark SK, Faiz OD, Hart AL. Systematic review: ileoanal pouch microbiota in health and disease. *Aliment Pharmacol Ther*. 2018;47(4):466-477. <https://doi.org/10.1111/apt.14454>
11. Seril DN, Yao Q, Shen B. The association between autoimmunity and pouchitis. *Inflamm Bowel Dis*. 2014;20(2):378-88. <https://doi.org/10.1097/01.MIB.0000435761.82705.6a>
12. Shen B. Pouchitis: what every gastroenterologist needs to know. *Clin Gastroenterol Hepatol*. 2013;11(12):1538-49. <https://doi.org/10.1016/j.cgh.2013.03.033>
13. Rothenberger DA. Pouchitis and empiricism: can we progress? *Mayo Clin Proc*. 1994;69(5):491-2. [https://doi.org/10.1016/s0025-6196\(12\)61649-8](https://doi.org/10.1016/s0025-6196(12)61649-8)
14. Cheifetz A, Itzkowitz S. The diagnosis and treatment of pouchitis in inflammatory bowel disease. *J Clin Gastroenterol*. 2004;38(5 Suppl 1):S44-50. <https://doi.org/10.1097/01.mcg.0000124001.93146.ef>
15. Shen B, Fazio VW, Remzi FH, Brzezinski A, Bennett AE, Lopez R, Hammel JP, Achkar JP, Bevins CL, Lavery IC, Strong SA, Delaney CP, Liu W, Bambrick ML, Sherman KK, Lashner BA. Risk factors for diseases of ileal pouch-anal anastomosis after restorative proctocolectomy for ulcerative colitis. *Clin Gastroenterol Hepatol*. 2006;4(1):81-9; quiz 2-3. <https://doi.org/10.1016/j.cgh.2005.10.004>
16. Gorrepati VS, Stuart A, Deiling S, Koltun W, Tinsley A, Williams ED, Coates MD. Smoking and the Risk of Pouchitis in Ulcerative Colitis Patients With Ileal Pouch-Anal Anastomosis. *Inflamm Bowel Dis*. 2018;24(9):2027-2032. <https://doi.org/10.1093/ibd/izy097>
17. Fleshner PR, Vasiliauskas EA, Kam LY, Fleshner NE, Gaiennie J, Abreu-Martin MT, Targan SR. High level perinuclear antineutrophil cytoplasmic antibody (pANCA) in ulcerative colitis patients before colectomy predicts the development of chronic pouchitis after ileal pouch-anal anastomosis. *Gut*. 2001;49(5):671-7. <https://doi.org/10.1136/gut.49.5.671>
18. Singh S, Sharma PK, Loftus EV Jr, Pardi DS. Meta-analysis: serological markers and the risk of acute and chronic pouchitis. *Aliment Pharmacol Ther*. 2013;37(9):867-75. <https://doi.org/10.1111/apt.12274>
19. Shen B, Achkar JP, Lashner BA, Ormsby AH, Remzi FH, Bevins CL, Brzezinski A, Petras RE, Fazio VW. Endoscopic and histologic evaluation together with symptom assessment are required to diagnose pouchitis. *Gastroenterology*. 2001;121(2):261-7. <https://doi.org/10.1053/gast.2001.26290>
20. Barreiro-de Acosta M, Gutierrez A, Rodríguez-Lago I, Espín E, Ferrer Bradley I, Marín-Jimenez I, Beltrán B, Chaparro M, Gisbert JP, Nos P; en representación de GETECCU. Recommendations of the Spanish Working Group on Crohn's Disease and Ulcerative Colitis (GETECCU) on pouchitis in ulcerative colitis. Part 1: Epidemiology, diagnosis and prognosis. *Gastroenterol Hepatol*. 2019;42(9):568-578. <https://doi.org/10.1016/j.gastrohep.2019.08.001>
21. Sandborn WJ, Tremaine WJ, Batts KP, Pemberton JH, Phillips SF. Pouchitis after ileal pouch-anal anastomosis: a Pouchitis Disease Activity Index. *Mayo Clin Proc*. 1994;69(5):409-15. [https://doi.org/10.1016/s0025-6196\(12\)61634-6](https://doi.org/10.1016/s0025-6196(12)61634-6)
22. Shen BO. Management of acute and chronic pouchitis [internet]. Up To date; 2020 [acceso el 25 de julio de 2020]. Disponible en: <https://www.uptodate.com/contents/management-of-acute-and-chronic-pouchitis>
23. Bell AJ, Price AB, Forbes A, Ciclitira PJ, Groves C, Nicholls RJ. Pre-pouch ileitis: a disease of the ileum in ulcerative colitis after restorative proctocolectomy. *Colorectal Dis*. 2006;8(5):402-10. <https://doi.org/10.1111/j.1463-1318.2006.00954.x>
24. Shepherd NA, Jass JR, Duval I, Moskowitz RL, Nicholls RJ, Morson BC. Restorative proctocolectomy with ileal reservoir: pathological and histochemical study of mucosal biopsy specimens. *J Clin Pathol*. 1987;40(6):601-7. <https://doi.org/10.1136/jcp.40.6.601>
25. de Silva HJ, Millard PR, Kettlewell M, Mortensen NJ, Prince C, Jewell DP. Mucosal characteristics of pelvic ileal pouches. *Gut*. 1991;32(1):61-5. <https://doi.org/10.1136/gut.32.1.61>
26. Shepherd NA, Healey CJ, Warren BF, Richman PI, Thomson WH, Wilkinson SP. Distribution of mucosal pathology and an assessment of colonic phenotypic change in the pelvic ileal reservoir. *Gut*. 1993;34(1):101-5. <https://doi.org/10.1136/gut.34.1.101>
27. Jiang W, Goldblum JR, Lopez R, Lian L, Shen B. Increased crypt apoptosis is a feature of autoimmune-associated

- chronic antibiotic refractory pouchitis. *Dis Colon Rectum*. 2012;55(5):549-57. <https://doi.org/10.1097/DCR.0b013e31824ab7c6>
28. Fumery M, Patel NS, Boland BS, Dulai PS, Singh S, Sandborn WJ. Efficacy and Safety of Endoscopic Balloon Dilatation of Ileoanal Pouch Strictures. *Inflamm Bowel Dis*. 2018;24(6):1316-1320. <https://doi.org/10.1093/ibd/izy006>
  29. Thompson-Fawcett MW, Marcus V, Redston M, Cohen Z, McLeod RS. Risk of dysplasia in long-term ileal pouches and pouches with chronic pouchitis. *Gastroenterology*. 2001;121(2):275-81. <https://doi.org/10.1053/gast.2001.26442>
  30. Derikx LA, Kievit W, Drenth JP, de Jong DJ, Ponsioen CY, Oldenburg B, van der Meulen-de Jong AE, Dijkstra G, Grubben MJ, van Laarhoven CJ, Nagtegaal ID, Hoentjen F; Dutch Initiative on Crohn and Colitis. Prior colorectal neoplasia is associated with increased risk of ileoanal pouch neoplasia in patients with inflammatory bowel disease. *Gastroenterology*. 2014;146(1):119-28.e1. <https://doi.org/10.1053/j.gastro.2013.09.047>
  31. Pardi DS, D'Haens G, Shen B, Campbell S, Gionchetti P. Clinical guidelines for the management of pouchitis. *Inflamm Bowel Dis*. 2009;15(9):1424-31. <https://doi.org/10.1002/ibd.21039>
  32. Segal JP, Ding NS, Worley G, McLaughlin S, Preston S, Faiz OD, Clark SK, Hart AL. Systematic review with meta-analysis: the management of chronic refractory pouchitis with an evidence-based treatment algorithm. *Aliment Pharmacol Ther*. 2017;45(5):581-592. <https://doi.org/10.1111/apt.13905>
  33. Segal JP, Poo SX, McLaughlin SD, Faiz OD, Clark SK, Hart AL. Long-term follow-up of the use of maintenance antibiotic therapy for chronic antibiotic-dependent pouchitis. *Frontline Gastroenterol*. 2018;9(2):154-158. <https://doi.org/10.1136/flgastro-2017-100913>
  34. Barreiro-de Acosta M, Marín-Jimenez I, Rodríguez-Lago I, Guarner F, Espín E, Ferrer Bradley I, Gutiérrez A, Beltrán B, Chaparro M, Gisbert JP, Nos P; en representación de GETECCU. Recommendations of the Spanish Working Group on Crohn's Disease and Ulcerative Colitis (GETECCU) on pouchitis in ulcerative colitis. Part 2: Treatment. *Gastroenterol Hepatol*. 2020;43(10):649-658. <https://doi.org/10.1016/j.gastrohep.2020.04.004>
  35. Gionchetti P, Rizzello F, Helwig U, Venturi A, Lammers KM, Brigidi P, Vitali B, Poggioli G, Miglioli M, Campieri M. Prophylaxis of pouchitis onset with probiotic therapy: a double-blind, placebo-controlled trial. *Gastroenterology*. 2003;124(5):1202-9. [https://doi.org/10.1016/s0016-5085\(03\)00171-9](https://doi.org/10.1016/s0016-5085(03)00171-9)
  36. Gionchetti P, Rizzello F, Venturi A, Brigidi P, Matteuzzi D, Bazzocchi G, Poggioli G, Miglioli M, Campieri M. Oral bacteriotherapy as maintenance treatment in patients with chronic pouchitis: a double-blind, placebo-controlled trial. *Gastroenterology*. 2000;119(2):305-9. <https://doi.org/10.1053/gast.2000.9370>
  37. Gosselink MP, Schouten WR, van Lieshout LM, Hop WC, Laman JD, Ruseler-van Embden JG. Delay of the first onset of pouchitis by oral intake of the probiotic strain *Lactobacillus rhamnosus* GG. *Dis Colon Rectum*. 2004;47(6):876-84. <https://doi.org/10.1007/s10350-004-0525-z>
  38. Tomasz B, Zoran S, Jarosław W, Ryszard M, Marcin G, Robert B, Piotr K, Lukasz K, Jacek P, Piotr G, Przemysław P, Michał D. Long-term use of probiotics *Lactobacillus* and *Bifidobacterium* has a prophylactic effect on the occurrence and severity of pouchitis: a randomized prospective study. *Biomed Res Int*. 2014;2014:208064. <https://doi.org/10.1155/2014/208064>
  39. Pronio A, Montesani C, Butteroni C, Vecchione S, Mumolo G, Vestri A, Vitolo D, Boirivant M. Probiotic administration in patients with ileal pouch-anal anastomosis for ulcerative colitis is associated with expansion of mucosal regulatory cells. *Inflamm Bowel Dis*. 2008;14(5):662-8. <https://doi.org/10.1002/ibd.20369>
  40. Yasueda A, Mizushima T, Nezu R, Sumi R, Tanaka M, Nishimura J, Kai Y, Hirota M, Osawa H, Nakajima K, Mori M, Ito T. The effect of *Clostridium butyricum* MIYAIRI on the prevention of pouchitis and alteration of the microbiota profile in patients with ulcerative colitis. *Surg Today*. 2016;46(8):939-49. <https://doi.org/10.1007/s00595-015-1261-9>
  41. Huguet M, Pereira B, Goutte M, Goutorbe F, Dubois A, Bommelaer G, Buisson A. Systematic Review With Meta-Analysis: Anti-TNF Therapy in Refractory Pouchitis and Crohn's Disease-Like Complications of the Pouch After Ileal Pouch-Anal Anastomosis Following Colectomy for Ulcerative Colitis. *Inflamm Bowel Dis*. 2018;24(2):261-268. <https://doi.org/10.1093/ibd/izx049>
  42. Bär F, Kühbacher T, Dietrich NA, Krause T, Stallmach A, Teich N, Schreiber S, Walldorf J, Schmelz R, Büning C, Fellermann K, Büning J, Helwig U; German IBD Study Group. Vedolizumab in the treatment of chronic, antibiotic-dependent or refractory pouchitis. *Aliment Pharmacol Ther*. 2018;47(5):581-587. <https://doi.org/10.1111/apt.14479>
  43. Orfanoudaki E, Foteinogiannopoulou K, Koutroubakis IE. Use of vedolizumab in a patient with chronic and refractory pouchitis. *Ann Gastroenterol*. 2018;31(3):379. <https://doi.org/10.20524/aog.2018.0243>
  44. Okano S, Yoshimura N, Sako M, Takazoe M. A case of refractory chronic pouchitis successfully treated with tofacitinib. *Clin J Gastroenterol*. 2020;13(4):560-563. <https://doi.org/10.1007/s12328-020-01108-5>
  45. Helavirta I, Hyöty M, Huhtala H, Collin P, Aitola P. Long-term functional outcome after restorative proctocolectomy: a cross-sectional study. *Scand J Gastroenterol*. 2018;53(10-11):1245-1249. <https://doi.org/10.1080/00365521.2018.1518479>
  46. Shen B, Yu C, Lian L, Remzi FH, Kiran RP, Fazio VW, Kattan MW. Prediction of late-onset pouch failure in patients with restorative proctocolectomy with a nomo-

- gram. *J Crohns Colitis*. 2012;6(2):198-206. <https://doi.org/10.1016/j.crohns.2011.08.006>
47. Cold F, Kousgaard SJ, Halkjaer SI, Petersen AM, Nielsen HL, Thorlacius-Ussing O, Hansen LH. Fecal Microbiota

Transplantation in the Treatment of Chronic Pouchitis: A Systematic Review. *Microorganisms*. 2020;8(9):1433. <https://doi.org/10.3390/microorganisms8091433>