

Bronchoesophageal Fistula Secondary to Pulmonary Aspergillosis

Antonio M. Caballero-Mateos,^{1*} Mercedes López de Hierro-Ruiz,² Eduardo Redondo-Cerezo,²

OPEN ACCESS

Citation:

Caballero-Mateos AM, López de Hierro-Ruiz M, Redondo-Cerezo E. Bronchoesophageal Fistula Secondary to Pulmonary Aspergillosis. *Rev Colomb Gastroenterol.* 2020;35(4):558-559. <https://doi.org/10.22516/25007440.461>

1 Digestive System Service. Hospital Universitario Clínico San Cecilio. Granada, Spain.

2 Digestive System Service. Hospital Universitario Virgen de las Nieves. Granada, Spain.

*Correspondence: Antonio M. Caballero-Mateos. ogy1492@hotmail.com

Received: 12/12/19

Accepted: 14/12/20



Dear Editor:

A 61-year-old man was admitted to our center due to a 2-week history of dyspnea and dysphagia for solids and liquids. He had mucocutaneous pallor on examination and lab test results only showed slight anemia (hemoglobin [Hb]: 12.5 g/dL). Two months earlier, he had been diagnosed with acute myeloid leukemia and treatment with idarubicin had been started.

An upper gastrointestinal (GI) endoscopy was performed, finding a 0.8 cm whitish-to-yellow and whitish esophageal lesion was observed at about 29 centimeters from the dental arch. It did not seem to originate in the esophageal mucosa as it moved independently (**Figure 1**), suggesting the presence of an esophageal fistula. A computed tomography (CT) scan was performed, confirming the diagnosis of bronchoesophageal fistula associated with mediastinal mass (**Figure 2**). A subsequent bronchoscopy showed an obliterative and necrotic endobronchial mass with malignant pseudomembranes.

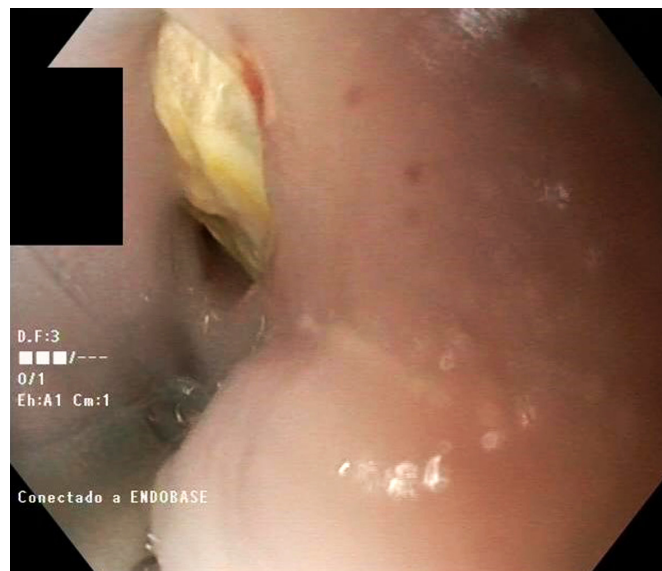

Figure 1. Endoscopic image of the esophageal fistula.

A bronchoalveolar lavage (BAL) and biopsies were performed. The mass was surgically removed. During the intervention, a new upper GI endoscopy was carried out and the fistula was successfully closed using an over-the-scope clip (Ovesco®) (Figure 3). Pathology results reported necrotic tissue and granulation, as well as large colonies of *Aspergillus* hyphae, with no malignant cells. Bronchoalveolar lavage galactomannan was positive ($I > 4$). Unfortunately, the patient died two days after the surgical procedure.

Aspergillosis is a rare finding in contexts such as immunosuppression, chemotherapy for blood disorders or transplanted patients (1). Fistula formation is a rare complication of pulmonary aspergillosis (2), and bronchopleural fistulas are the most frequently described. In the

last decade, Ovesco clip has been used during endoscopic procedures for gastrointestinal bleeding, fistulas, or perforations, with a clinical success rate between 64% and 91.7% (3-5). Chronic fistulas or previous radiation therapy are common in cases where treatment failed. The risks of using this system (bleeding, perforation, or aspiration) are rare when it is used correctly. Cases of tracheoesophageal fistulas successfully treated with Ovesco have been reported, although that is not the case for bronchoesophageal fistulas. The latter is an exceptional and underreported finding, which, in this case, was resolved using an Ovesco clip. However, in the clinical context of this patient, it was not enough because there was no opportunity to start a specific antifungal treatment.

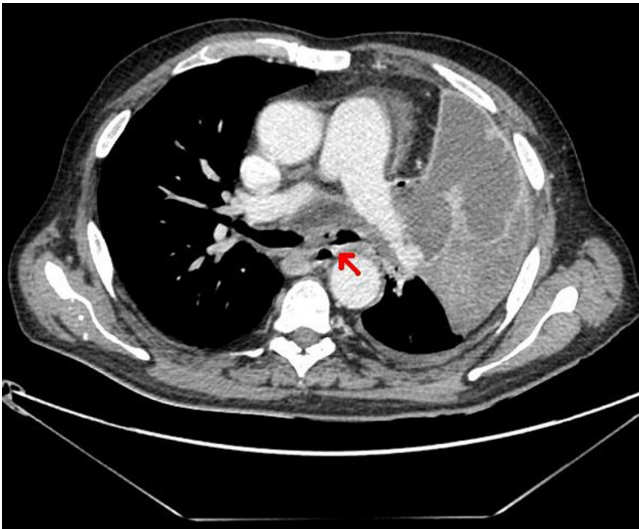


Figure 2. CT scan showing communication between the esophagus and the bronchus associated with a mediastinal mass.

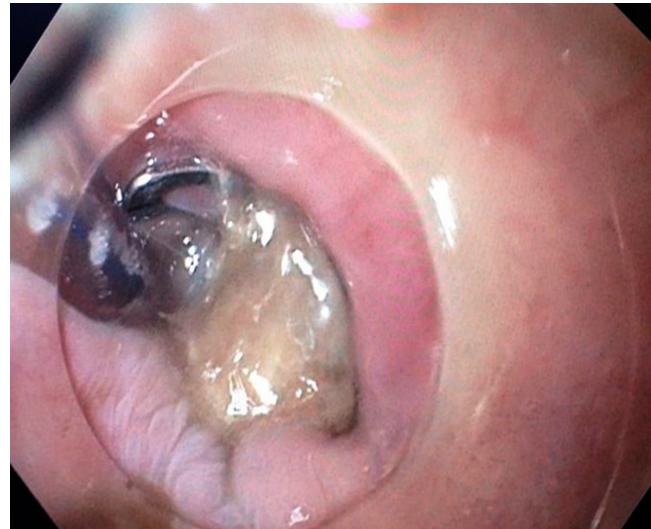

Figure 3. Endoscopic image after closing the fistula with the Ovesco clip.

REFERENCES

1. Yu Y, Zhu C, Qian X, Gao Y. Tracheoesophageal fistula induced by invasive pulmonary aspergillosis. *Annals of Translational Medicine*. 2016;4(18):345. <https://doi.org/10.21037/atm.2016.09.16>
2. Mineur P, Ferrant A, Wallon J, Otte JB, Michaux JL. Bronchoesophageal fistula caused by pulmonary aspergillosis. *Eur J Respir Dis*. 1985;66(5):360-6.
3. Goenka MK, Rai VK, Goenka U, Tiwary IK. Endoscopic Management of Gastrointestinal Leaks and Bleeding with the Over-the-Scope Clip: A Prospective Study. *Clin Endosc*. 2017;50(1):58-63. <https://doi.org/10.5946/ce.2016.028>
4. Morrell DJ, Winder JS, Johri A, Docimo S, Juza RM, Witte SR, Alli VV, Pauli EM. Over-the-scope clip management of non-acute, full-thickness gastrointestinal defects. *Surg Endosc*. 2020;34(6):2690-2702. <https://doi.org/10.1007/s00464-019-07030-3>
5. Mosquera-Klinger G, Torres-Rincón R, Jaime-Carvajal J. Endoscopic closure of gastrointestinal perforations and fistulas using the Ovesco Over-The-Scope Clip system at a tertiary care hospital center. *Rev Gastroenterol Mex*. 2019;84(2):263-266. <https://doi.org/10.1016/j.rgmx.2018.10.004>