ISSN 0120-9957
ISSN 2500-7440 (Online)
DOI: https://doi.org/10.22516/issn.2500-7440

RCG Revista Colombiana de Gastroenterología

Volume 39 - Number 3
July - September 2024

www.revistagastrocol.com
www.gastrocol.com · www.scielo.org.co





Editorial

Reasoning is not the same as problem solving

Original articles

Diaphragmatic Rehabilitation Therapy for the Management of Supragastric Belching: Case Series and Literature Review

Mortality from Colon, Rectal, and Anal Cancer in Barranquilla Between 1985 and 2020

Epidemiology of Acute Cholecystitis in Colombia: An Analysis of Official Records from the Ministry of Health

Real-Life Colonoscopy Preparation

Morbidity and Mortality in COVID-19 Patients With and Without Gastrointestinal Symptoms

Review articles

Obesity: The Role of the Gastroenterologist

Research and Publish. 3. How to Conduct a Statistical Analysis of Research

Disorders of Brain-Gut Interaction (Functional Gastrointestinal Disorders): Neuromodulators in Clinical Practice (Part II)

Case reports

Chronic Digestive Bleeding Caused by Hookworms Diagnosed via Capsule Endoscopy: Case Report

Capillary Hemangioma of the Jejunum as a Cause of Acute Bleeding: Case Report and Literature Review

Case Report of Intrahepatic Cholestasis Associated with ATP8B1 Gene Mutation in a Patient with Human Immunodeficiency Virus (HIV) Infection: A Diagnostic Challenge

Colonic Cystic Pneumatosis as a Manifestation of Colorectal Lymphoma: Case Report and Literature Review

Liver Abscess Due to Fish Bone: Case Report

Blue Rubber Bleb Nevus Syndrome in the Colon, Tongue, and Supraglottic Region: Case Report

A Forgotten Cause of Recurrent Abdominal Pain: Case Report

Response to Cetuximab in Squamous Cell Carcinoma of the Anal Canal After Multiple Lines of Chemotherapy and Immunotherapy

Letter to the editor

Analysis of additional risk factors for liver fibrosis in diabetic patients with end-stage chronic kidney disease

ASOCIACION COLOMBIANA DE GASTROENTEROLOGIA
1947

Volume 39 No. 3 | July - September 2024

Contents

RCG Revista Colombiana de Gastroenterología

Editorial

Reasoning is not the same as problem solving 251
Eduardo Valdivieso-Rueda.

Original articles

Diaphragmatic Rehabilitation Therapy for the Management of Supragastric Belching: Case Series and Literature Review 253
Adán Lúquez-Mindiola, Laura Moya-Valenzuela, Andrea Gómez-Rodríguez, Alfredo Acuña-Páramo, Luis Fernando Pineda-Ovalle.

Mortality from Colon, Rectal, and Anal Cancer in Barranquilla Between 1985 and 2020 260
Adalgisa Alcocer-Olaciregui, Paula Chamorro-Piñeros, Sara Niño-Castro, Stefanía Saucedo-Jiménez, Rusvelt Vargas-Moranth.

Epidemiology of Acute Cholecystitis in Colombia: An Analysis of Official Records from the Ministry of Health 267
Juan Felipe Otálora-Esteban, Juan S. Hernández-Meza, Diego Rosselli.

Real-Life Colonoscopy Preparation 274
Carlos Arturo Rojas-Rodríguez, Jorge Salazar, Nelson Rojas, Carlos Andrés Mejía, Michell González-Hurtado, Ana Fernanda Mejía, Eliana Manzi, Leidy Johanna Hurtado-Bermúdez, Wanda Zamary Colorado-Vásquez, Natalia Mena-Cabrera.

Morbidity and Mortality in COVID-19 Patients With and Without Gastrointestinal Symptoms 281
Margarita Rey-R., Gustavo Reyes, Belén Mendoza-de Molano, Cathalina Vergara-Cabra, Erika D. Pérez-Riveros, Juan Carlos Robayo, Mariana Vásquez-Roldán, Fernando Sierra-Arango.

Review articles

Obesity: The Role of the Gastroenterologist 287
Valeria Atenea Costa-Barney, Daniela Cáceres, Alfonso Kerguelen, Jesús Rodríguez, Andrés Rodríguez, Manoel Galvao.

Research and Publish. 3. How to Conduct a Statistical Analysis of Research 296
Gerardo Andrés Puentes-Leal.

Disorders of Brain-Gut Interaction (Functional Gastrointestinal Disorders): Neuromodulators in Clinical Practice (Part II) 302
David Benigno Páramo-Hernández, Luis Fernando Pineda-Ovalle, Laura Marcela Moya-Valenzuela, Alejandro Concha-Mejía, Juan David Páramo.

Case reports

Chronic Digestive Bleeding Caused by Hookworms Diagnosed via Capsule Endoscopy: Case Report **310**

César Pastás-Navarrete, Fredy A. Pazmiño.

Capillary Hemangioma of the Jejunum as a Cause of Acute Bleeding: Case Report and Literature Review **318**

Martín Alonso Gómez-Zuleta, Diego Alexánder Cardona-Botero, Juan Antonio Trejos-Naranjo, Felipe Vera-Polanía.

Case Report of Intrahepatic Cholestasis Associated with ATP8B1 Gene Mutation in a Patient with Human Immunodeficiency Virus (HIV) Infection: A Diagnostic Challenge **323**

Darwin Jhoan Ariza-Rodríguez, Valentina Dávila, Carmen Yanette Suárez-Quintero, Sandra Amado-Garzón.

Colonic Cystic Pneumatosis as a Manifestation of Colorectal Lymphoma: Case Report and Literature Review **328**

Juan Guillermo Cala-Noriega, Carlos E. Figueroa-Avendaño.

Liver Abscess Due to Fish Bone: Case Report **332**

Annar Aileen Cuesta-Pertuz, Óscar Alberto Mosquera-López, Isabel Cristina Palacios-Cuesta, Jesús Alberto Mosquera-López, Daniela Patricia De León-Valdés.

Blue Rubber Bleb Nevus Syndrome in the Colon, Tongue, and Supraglottic Region: Case Report **337**

Fabián Eduardo Puentes-Manosalva, Rubén Darío Londoño-López, Andrés Sánchez-Gil, Lázaro Antonio Arango-Molano.

A Forgotten Cause of Recurrent Abdominal Pain: Case Report **344**

Carlos Mauricio Martínez-Montalvo, David José Ramírez-Daza, Laura Catalina Gutiérrez-Rueda, David Felipe Olarte-Parra, Laura Otálora-González.

Response to Cetuximab in Squamous Cell Carcinoma of the Anal Canal After Multiple Lines of Chemotherapy and Immunotherapy **350**

Javier Mauricio Segovia, Sergio Osorio, Erick Andrés Cantor, Luis Eduardo Pino, Henry Alexánder Vargas, John Alejandro Murillo-Silva, Iván Camilo Triana, Valentina Navas-Cardona.

Letter to the editor

Analysis of additional risk factors for liver fibrosis in diabetic patients with end-stage chronic kidney disease **356**

Jazmín Medalit Lázaro-Sotelo.

Reply to the letter to the editor **358**

Ismael Yepes-Barreto, Diana Romero, Jorge Coronado-Daza.

Cover: *A. Retroflexion view as an optional maneuver for full visualization of the balloon during inflation with saline solution and methylene blue.*
B. Inflated balloon at the subcardial level observed with direct vision.
Article: Obesity: The Role of the Gastroenterologist
Courtesy by the authors: Valeria Atenea Costa-Barney, Daniela Cáceres, Alfonso Kerguelen, Jesús Rodríguez, Andrés Rodríguez, Manoel Galvao.

https://doi.org/10.22516/25007440.1281

Editorial

Reasoning is not the same as problem solving

Eduardo Valdivieso-Rueda.[1*]

OPEN ACCESS

Citation:
Valdivieso-Rueda E. Reasoning is not the same as problem solving. Revista. colomb. Gastroenterol. 2024;39(3):251-252.
https://doi.org/10.22516/25007440.1281

[1] General Surgeon, Gastrointestinal Surgeon, Gastroenterologist, and Endoscopist; Centro Internacional de Enfermedades Digestivas (CIED), FOSCAL. Bucaramanga, Colombia.

***Correspondence:** Eduardo Valdivieso-Rueda.
evaldivieso@gmail.com

Received: 29/08/2024
Accepted: 30/08/2024

The prestigious scientific journal *The Lancet* has recently published the most comprehensive and detailed report to date on the global issues of obesity and underweight[(1)]. This important global study included data from 1,537 adults and 385 Colombian children, who were probabilistically sampled from the five main cities in the country by the research team led by Dr. Carlos Olimpo Mendivil, coordinator of the Diabetes, Lipids, and Metabolism Laboratory at Universidad de los Andes.

The figures are striking: in adults, 36.2% are overweight, and 21.3% are obese, with women being the most affected. Children, too, are gaining weight: one in three exceeds the upper normal limit for their age in terms of body mass index (BMI). It is alarming to see how excess weight among Colombians has risen sharply compared to the 2015 findings of the Encuesta Nacional de Situación Nutricional de Colombia (ENSIN)[(2)].

To address this issue, the main article in our journal provides reliable data on therapeutic strategies available from both the digestive and neuroendocrine systems to treat a condition whose etiology is more likely rooted in behavioral and social factors. The field theory proposed by Kurt Lewin, recognized as the father of modern social psychology, left us with the concept of *frustration*, understood as the conflict arising from competing motives[(3)]. Based on this principle, he described four types of conflict, one of which is relevant for this editorial: the double approach-avoidance conflict, which refers to the tension an individual experiences when having to choose between two or more mutually exclusive options that have similar attractive positive outcomes and potentially avoidable negative consequences.

It is worth recalling this Gestalt principle of social psychology when considering the various therapeutic options available for treating obesity, with known effectiveness for surgery, and now also available through pharmacology and digestive endoscopy. At this point, the article by Dr. Costa Barney and colleagues provides what is necessary[(4)].

Reasoning is not the same as solving a problem, but given the circumstances, we are currently facing a significant issue with multiple solutions, each offering benefits and potential drawbacks, making it very difficult to make decisions based solely on the available evidence. As the saying goes, if there are many solutions to a single problem, it is because none are truly good enough. Thus, we are left with the option of reasoning through the most reliable data to design the best solution for each specific case.

© 2024 Asociación Colombiana de Gastroenterología

REFERENCES

1. NCD Risk Factor Collaboration (NCD-RisC). Worldwide trends in body-mass index, underweight, overweight, and obesity from 1975 to 2016: a pooled analysis of 2416 population-based measurement studies in 128·9 million children, adolescents, and adults. Lancet. 2017;390(10113):2627-2642. https://doi.org/10.1016/S0140-6736(17)32129-3
2. Ministerio de Salud y Protección Social. Encuesta nacional de la situación nutricional-ENSIN 2015 [Internet]. ICBF, MSPS, INS, Departamento Administrativo para la Prosperidad Social; 2015 [consultado el 27 de agosto de 2024]. Disponible en: https://www.minsalud.gov.co/sites/rid/Lists/BibliotecaDigital/RIDE/VS/ED/GCFI/documento-metodologico-ensin-2015.pdf
3. Lewin K. La teoría del campo en la ciencia social. Barcelona: Paidós Ibérica; 1988.
4. Costa-Barney VA, Cáceres D, Kerguelen A, Rodríguez J, Rodríguez A, Galvao M. Obesidad, el papel del gastroenterólogo. Rev Colomb Gastroenterol. 2024;39(3):287-295. https://doi.org/10.22516/25007440.1192

https://doi.org/10.22516/25007440.1123

Original article

Diaphragmatic Rehabilitation Therapy for the Management of Supragastric Belching: Case Series and Literature Review

Adán Lúquez-Mindiola,[1*] Laura Moya-Valenzuela,[2] Andrea Gómez-Rodríguez,[3] Alfredo Acuña-Páramo,[4] Luis Fernando Pineda-Ovalle.[5]

OPEN ACCESS

Citation:
Lúquez-Mindiola A, Moya-Valenzuela L, Gómez-Rodríguez A, Acuña-Páramo A, Pineda-Ovalle LF. Diaphragmatic Rehabilitation Therapy for the Management of Supragastric Belching: Case Series and Literature Review. Revista. colomb. Gastroenterol. 2024;39(3):253-259. https://doi.org/10.22516/25007440.1123

[1] Internal Medicine, Gastroenterology, Universidad Nacional de Colombia. Digestive Health Institute, GutMédica. Bogotá, Colombia.
[2] Internal Medicine, Universidad El Bosque. Gastroenterology, Universidad del Rosario. Digestive Health Institute, GutMédica. Bogotá, Colombia.
[3] Internal Medicine, Gastroenterology. Universidad del Rosario. Digestive Health Institute, GutMédica. Bogotá, Colombia.
[4] Internal Medicine, Gastroenterology, Universidad Militar Nueva Granada. Digestive Health Institute, GutMédica. Bogotá, Colombia.
[5] Internal Medicine, Gastroenterology, and Epidemiology. Professor of Gastrointestinal Motility Service, Universidad Nacional de Colombia. Scientific Director, Digestive Health Institute, GutMédica. Bogotá, Colombia.

***Correspondence:** Adán Lúquez-Mindiola.
ajluquezm@unal.edu.co

Received: 24/10/2023
Accepted: 25/01/2024

Abstract

Belching is a physiological event that allows air to be released from the esophagus or stomach to the pharynx. It can become excessive, bothersome, and difficult to control in some patients, making it a common reason for consultation with a gastroenterologist. This paper aims to present a series of cases from our experience at a gastrointestinal motility reference center in managing patients with supra gastric belching using diaphragmatic rehabilitation therapy and to conduct a literature review.

Keywords

Belching, Esophageal pH Monitoring, Diagnosis, Treatment.

INTRODUCTION

Belching is the audible release of air from the esophagus or stomach into the pharynx[1]. It is a physiological event that typically occurs up to 30 times a day[2]. Although common in the general population, it can be considered a disorder when it becomes excessive and bothersome[1]. Patients who are unable to control their belching in public may feel embarrassed, disrupting their social life and negatively impacting their quality of life[2,3]. These are the patients who most often seek medical consultation for their symptoms[3].

Studies report the prevalence of belching symptoms in the general population, with rates ranging between 6.7% and 28.8%[3]. One study found that approximately 3.4% of patients with upper gastrointestinal discomfort referred to a gastrointestinal physiology unit had supragastric belching (SB)[4]. However, the results can vary depending on the definition of excessive belching[3].

Belching can occur in isolation or be associated with other gastrointestinal complaints such as gastroesophageal reflux disease (GERD), rumination syndrome, or functional dyspepsia[2]. It has also been linked to psychological disorders such as anxiety and depression. The advent of technologies

and advances in impedance monitoring and high-resolution esophageal manometry have improved our understanding of belching[5]. The aim of this study is to present a case series from our experience at a gastrointestinal physiology referral center in managing patients with SB using diaphragm rehabilitation, alongside a review of the literature.

MATERIALS AND METHODS

Consecutive patients referred to the gastrointestinal motility laboratory at the GutMédica Institute in Bogotá, Colombia, from January to December 2021, aged 18 years or older, were included in this study. These patients underwent 24-hour esophageal pH-impedance monitoring (pH-IIM) without proton pump inhibitors (PPIs) due to frequent belching as their predominant symptom, whether or not it was associated with typical GERD symptoms. Patients who were taking PPIs or had a history of esophageal or gastric surgery were excluded. Prior to the test, typical symptoms (heartburn and regurgitation) and atypical symptoms (belching, dysphagia, cough, throat clearing, and globus sensation) were assessed using a standardized questionnaire. Patients presented for the exam after fasting for at least eight hours.

The lower esophageal sphincter (LES) was located manometrically, and a catheter with impedance sensors at 3, 5, 7, 15, and 17 cm, and a pH sensor 5 cm above the upper edge of the LES, was used. Monitoring lasted at least 20 hours, and patients were given a diary to record symptoms during the study period. They were instructed to maintain their daily activities, meal schedules, and normal sleep patterns.

Data from the impedance and pH channels were stored on portable equipment by Sandhill Scientific or Sierra. The traces were reviewed, and manual editing was performed by expert gastroenterologists who noted meal events and symptom recordings. Meal periods were excluded from the analysis. A supragastric belching (SB) event was defined by an increase in impedance moving in a caudal direction from the proximal to the distal channel, followed by a return to baseline, starting in a retrograde manner from the distal channel.

Patients with frequent SB underwent diaphragm biofeedback therapy, with a protocol of one to two sessions per week, each lasting 45 minutes. The sessions were individualized, focusing on the specific needs of each patient, and were conducted by the same clinician. The treatment included an assessment to identify the patterns triggering the belching. Next, patients were educated about the nature of their symptoms to promote awareness and understanding of the factors causing them. During the therapy, techniques were applied such as postural correction, manual therapy for diaphragm release aimed at restoring proper mobility during breathing phases, and respiratory pattern awareness with an emphasis on diaphragmatic breathing. This included phonorespiratory coordination, myofunctional exercises for phonoarticulatory muscles, glottis training, vocal orientation and training exercises, and swallowing exercises designed to limit air entry into the esophagus. All exercises were focused on controlling the air entry and exit from the esophagus during daily activities.

A symptom evaluation was performed before and after the therapy sessions via a telephone survey, using the Visual Analog Scale (VAS) with scores ranging from 0 to 10 (0-3: mild, 4-6: moderate, 7-10: severe). A significant response was defined as a VAS improvement from severe to mild, while a partial response was considered when the change was from severe to moderate or from moderate to mild.

CASE PRESENTATION

Fifteen patients (8 women), aged between 21 and 70 years, are presented. In 33% of the patients, reflux hypersensitivity was evident, while 66% did not have pathological acid reflux. On average, seven (range: 3-20) diaphragm biofeedback therapy sessions were conducted. A significant response was observed in 66% of the patients, with better outcomes reported as the number of therapy sessions increased. The characteristics of the patients are shown in **Table 1.**

Eighty-six percent of patients showed improvement in the symptom of excessive belching (**Figure 1**); 73% reported improvement in their family environment (**Figure 2**); 66% reported improvement in their work environment (**Figure 3**); 74% experienced improvement in their social environment (**Figure 4**); and 94% achieved self-control over their belching.

PHYSIOLOGY OF BELCHING

With each swallow, a variable volume of air is ingested and transported to the stomach[5]. During belching, the accumulated intragastric air is vented into the esophagus, after which it may be expelled through the mouth[5]. The motor events of belching consist of three independent phases that are coordinated with each other: the gastric gas escape phase, the upper barrier elimination phase, and the gas transport phase[6]. The gastric gas escape phase involves a gastro-LES inhibitory reflex, causing transient relaxations of the lower esophageal sphincter (LES), which is triggered by distention of stretch receptors in the proximal stomach[6]. The upper barrier elimination phase involves transient relaxation of the upper esophageal sphincter (UES) along with airway protection, activated by stimulation of rapidly adapting mechanoreceptors in the esophageal mucosa[6]. The gas transport phase is reverse esophageal peristalsis, mediated by elementary

Table 1. Characteristics of Patients with Supragastric Belching

Age	Sex	Esophageal pH-Impedance	AET	Number of Belches	Number of Therapy Sessions	Significant Response
51	M	Negative for pathological acid reflux	0.2%	10	7	Yes
60	F	Negative for pathological acid reflux	0.2%	33	9	Yes
32	M	Negative for pathological acid reflux	0.1%	17	3	No
32	M	Negative for pathological acid reflux	0.5%	27	5	Yes
60	M	Negative for pathological acid reflux	1.3%	38	7	Yes
26	M	Reflux hypersensitivity	1.1%	56	3	No
30	F	Reflux hypersensitivity	1.9%	16	3	No
21	F	Reflux hypersensitivity	0.5%	36	9	Yes
52	F	Negative for pathological acid reflux	0.1%	16	3	No
27	F	Negative for pathological acid reflux	0.1%	18	7	Yes
61	F	Negative for pathological acid reflux	0.1%	10	3	No
70	M	Negative for pathological acid reflux	0.4%	24	10	Yes
49	M	Negative for pathological acid reflux	0.3%	211	20	Yes
22	F	Reflux hypersensitivity	1.3%	27	5	Yes
31	F	Reflux hypersensitivity	0.1%	26	10	Yes

Author's own research.

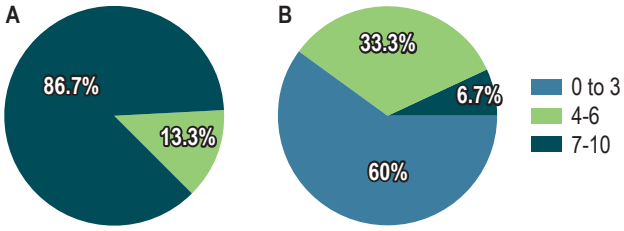

Figure 1. Symptom Discomfort. **A.** Discomfort before therapy. **B.** Discomfort after therapy. Author's own research.

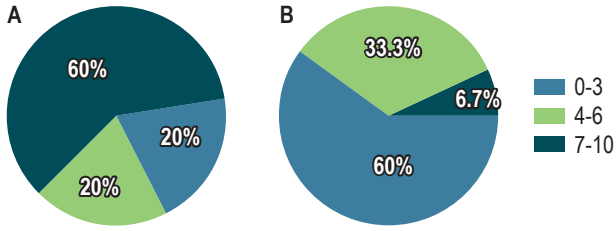

Figure 2. Discomfort in the Family Environment. **A.** Discomfort in the family environment before therapy. **B.** Discomfort in the family environment after therapy. Author's own research.

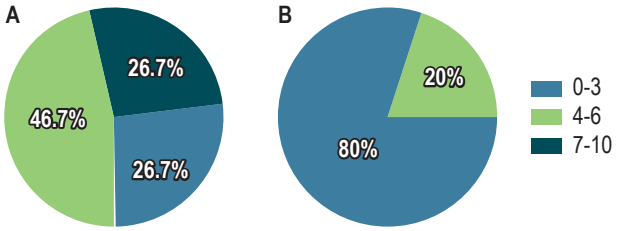

Figure 3. Work Environment Interference. **A.** Interference in the work environment before therapy. **B.** Interference in the work environment after therapy. Author's own research.

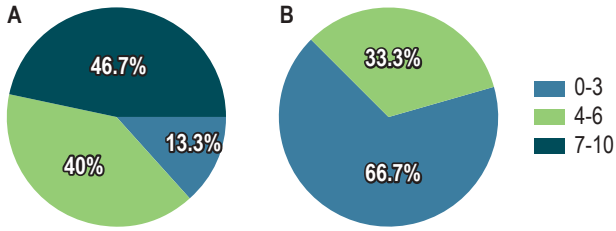

Figure 4. Interference in Social Activities. **A.** Interference in social activities before therapy. **B.** Interference in social activities after therapy. Author's own research.

reflexes, and is believed to be triggered by rapidly adapting tension receptors in the serosa[6].

CLASSIFICATION AND PATHOPHYSIOLOGY

There are two different types of belching: supragastric belching (SB) and gastric belching (GB). SB is considered an unintentional response to an uncomfortable sensation in the abdomen or retrosternal region, which does not occur during sleep, speech, or moments when the patient is distracted. Over time, SB can become a learned behavior for the patient[2].

In supragastric belching, air rapidly enters the esophagus, followed immediately by its quick expulsion. Two theories explain its mechanism:

- Air suction method: There is a movement of the diaphragm (in a proximal direction) that increases negative intrathoracic pressure, similar to what occurs during a deep inspiration. During SB, the upper esophageal sphincter (UES) relaxes, the glottis closes, and air flows from atmospheric pressure in the pharynx to subatmospheric pressure in the esophagus. This esophageal air is then expelled orally, with the patient perceiving it as a belch[6-8].
- Air injection method: There is a simultaneous increase in pressure in the pharynx that initiates air entry into the esophagus. The pressure gradient is caused by elevated pharyngeal pressure, without any change in intraesophageal pressure. This can be due to increased pressure or contractions at the base of the tongue, and esophageal peristalsis does not occur (no simultaneous contraction of the esophagus)[7,8].

GB is considered a physiological mechanism and occurs due to the rapid release of air from the stomach secondary to transient relaxation of the lower esophageal sphincter (LES). This mechanism prevents excessive abdominal distention from swallowed air[2].

DIAGNOSIS

The diagnosis is made through clinical evaluation and a thorough history taking. This helps to rule out the presence of red flags that may suggest organic causes, such as dysphagia or weight loss, and to assess the frequency and clinical pattern of the belching. Conditions such as GERD or anatomical abnormalities that may be involved must be ruled out[4,5]. In some cases, invasive investigations are unnecessary, as during the consultation, the patient may present with frequent and repetitive belching, suggestive of supragastric belching (SB). Gastric belching (GB) is neither rapid nor repetitive[1,8].

According to the Rome IV criteria, belching disorders are classified into two types: excessive SB and excessive GB (**Table 2**)[1]. The term aerophagia (frequent air swallowing), previously considered a mechanism of belching disorder under the Rome III criteria, was removed in the latest version of Rome IV because not all cases result from air swallowing[1].

Table 2. Diagnostic Criteria for Belching Disorders According to Rome IV Criteria

Belching Disorders
Diagnostic Criteria[a]
Must include all of the following:
- Belching from the esophagus or stomach occurring more than three days a week (severe enough to impact usual activities) Excessive supragastric belching (from the esophagus) Excessive gastric belching (from the stomach)
Supporting Comments
- Supragastric belching is supported by the observation of frequent and repetitive belching.
- Gastric belching has no established clinical correlation.
- Objective intraluminal impedance measurement can be used to distinguish supragastric belching from gastric belching.

[a]Criteria present for the previous three months with symptom onset at least six months before diagnosis. Adapted from: Stanghellini V, and colleagues. Gastroduodenal Disorders. Gastroenterology. 2016;150(6):1380-1392[1].

The gold standard for diagnosis and classification is 24-hour impedance-pH monitoring, which allows differentiation between the two types of belching and distinguishes them from GERD[9]. The esophageal impedance catheter is based on Ohm's law, which states that impedance to current flow is inversely related to the medium's electrical conductivity. As a result, this device can detect liquid or air refluxed into the esophagus based on changes in electrical conductivity, regardless of whether the content is acidic or non-acidic[9]. The transit of intraesophageal content can be detected through sequential changes in impedance along the catheter. Impedance monitoring plays a key role in the study of belching, as the conductivity of air is very low, and the presence of air between the electrodes results in an increase in impedance. Additionally, the direction of air flow must be evaluated. In GB, an impedance increase begins in the distal channel and progresses toward the more proximal channel, while in SB, the impedance increase begins in the proximal channel and progresses toward the distal channel (**Figures 5** and **6**)[7-10].

TREATMENT

The most important aspect is establishing a strong doctor-patient relationship, in which the mechanism behind the belching is clearly explained during the consultation. In most cases, patients expect an explanation of their condition and hope to find an organic cause; however, in the absence of an organic etiology, some patients may disagree with the information provided[4,5].

Currently, behavioral therapy and speech therapy are considered the most effective treatments for this condition[11-17]. Proper diagnosis with pH-impedance monitoring helps confirm that a behavioral disorder is present, which gives patients a clearer understanding of their symptoms and facilitates behavior modification and deconditioning[7,10]. The mechanism of air suction or injection into the esophagus should be explained to the patient to prevent its repetition and to achieve smooth breathing patterns. This is accomplished through exercises that train the glottis, vocal cords, and breathing[10]. Since SB is a learned behavior, behavioral therapy is useful. A recent clinical trial involving 42 patients with SB found that behavioral therapy reduced the frequency and intensity of belching at six months, with a 75% response rate to the therapy[13]. Cognitive-behavioral therapy has positive effects that persist for at least six to twelve months after treatment[14].

Additionally, speech therapy and biofeedback can help reduce excessive belching[15]. Abdominal breathing exercises can be taught by having the patient place a hand on their abdomen during breathing, ensuring that the hand moves throughout the respiratory cycle. This shifts attention from the belching to the behavior associated with it, fostering a cognitive process that is crucial for successful therapy. It is believed that 10 to 20 sessions are needed to achieve a

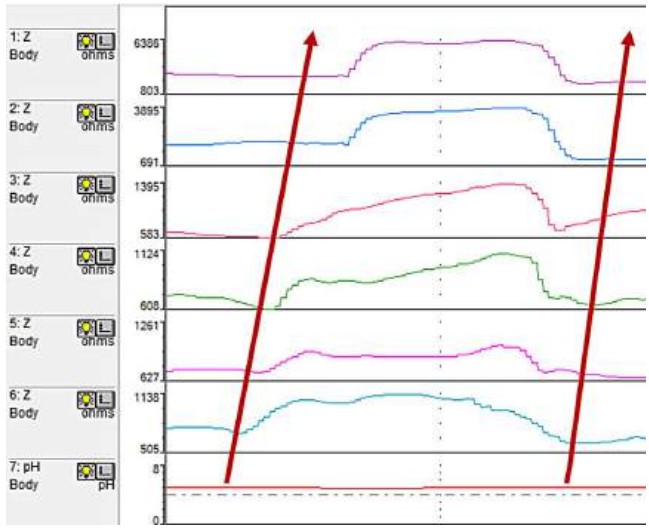

Figure 5. Gastric belching: Increase in impedance begins in the most distal channel and progresses toward the most proximal channel. Air is expelled from the esophagus in the oral direction, and impedance returns to baseline from the distal to the proximal channel (the arrows indicate the direction of airflow). Adapted from: Kessing BF, and colleagues. Am J Gastroenterol. 2014;109(8):1196-203[7].

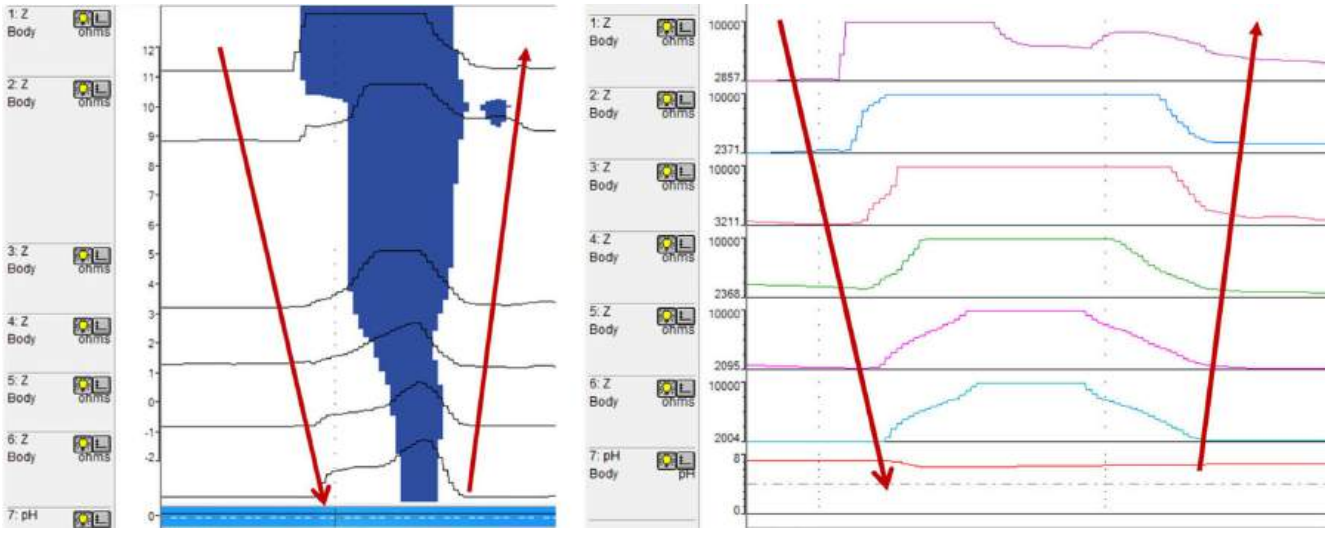

Figure 6. Supragastric belching: Increase in impedance begins in the proximal channel and progresses toward the distal channel. Air is expelled from the esophagus in the oral direction, and impedance returns to baseline starting from the distal and ending at the proximal channel (the arrows indicate the direction of airflow). Adapted from: Kessing BF, and colleagues. Am J Gastroenterol. 2014;109(8):1196-203[7].

significant reduction in belching complaints, although this is not yet standardized[7,8]. Conducting therapy guided by impedance monitoring may facilitate the correlation of symptoms with real-time visual information, helping to improve patient understanding and motivation. However, the catheter can be uncomfortable and might reduce adherence to therapy[10].

It is important to practice daily exercises that include breath-holding through glottic tension, with both laryngeal and oral closure, while redirecting the patient's attention away from the belching toward the actions that precede it. The patient can observe themselves in a mirror, or in some cases, videos can be used to document the events[10]. Exercises should be performed to improve abdominal breathing, ensuring that it is smooth and calm, avoiding sudden stops. These exercises should be practiced both at rest and while speaking. Additionally, in cases of severe, persistent belching, the technique of breathing with a finger between the teeth can be used, along with phonation exercises to reduce subglottic pressure and tension in the laryngeal muscles, and appropriate diaphragmatic breathing. The laryngeal-cricopharyngeal-lingual complex is also studied to unlearn ineffective actions like movements of the tongue, larynx, and upper esophagus, through jaw relaxation exercises, laryngeal manipulation, effective articulation, and vocal techniques. If suboptimal swallowing is present, activities are performed to improve oral preparation, optimize the transport phase, and coordinate swallowing with breathing[10,15].

Another behavioral therapy method involves teaching the patient to breathe with the mouth open and the tongue positioned behind the upper incisors, combined with slow, conscious diaphragmatic breathing in 3-second inhalation and exhalation cycles. These exercises should be practiced at least twice daily for three to four minutes in both the supine and upright positions. After this initial process, the exercises should be performed daily and as frequently as possible to prevent belching by recognizing warning signs of when belching might occur. The response to these therapies is subjectively recorded using visual analog scales (VAS) and quality-of-life questionnaires, which have shown improvements in perceived belching severity and quality of life in more than 50% of published studies[11]. Sustained glottic opening can improve by up to 75% at three months, and the therapy can be performed in the office[10,16]. This therapy involves slow, diaphragmatic breathing with the mouth open, starting in the supine position and then sitting to prevent belching. If successful, the patient is advised to repeat this sequence at home[16]. Finally, hypnotherapy has been used anecdotally with good results[18].

The only pharmacological treatment that has shown efficacy is baclofen, sometimes in combination with pregabalin. By reducing transient lower esophageal sphincter relaxations, it also decreases reflux events and may influence the mechano- and chemosensitivity of the esophagogastric junction. However, these medications can cause excessive drowsiness, and due to their side effects, they are infrequently used[19,20].

CONCLUSION

Belching is a physiological event; however, for some patients, it can become a medical issue due to its excessive or difficult-to-control occurrence. Belching may occur in isolation or be associated with other gastrointestinal disorders such as GERD, rumination syndrome, or functional dyspepsia. Impedance monitoring assists in the accurate classification of belching. The most important aspect is a strong doctor-patient relationship, where the mechanism behind the belching is clearly explained to the patient. Psychoeducation is a therapeutic option since SB is a learned behavior. For the treatment of SB, diaphragmatic biofeedback therapy is an effective strategy. Other available alternatives include behavioral and speech therapy.

Conflict of Interest

No conflicts of interest were declared.

Acknowledgments

The authors declare no conflicts of interest.

Funding Sources

None declared by the authors.

REFERENCES

1. Stanghellini V, Chan FK, Hasler WL, Malagelada JR, Suzuki H, Tack J, et al. Gastroduodenal Disorders. Gastroenterology. 2016;150(6):1380-1392. https://doi.org/10.1053/j.gastro.2016.02.011
2. Zad M, Bredenoord AJ. Chronic Burping and Belching. Curr Treat Options Gastroenterol. 202018(1):33-42. https://doi.org/10.1007/s11938-020-00276-0

3. Sawada A, Fujiwara Y, Sifrim D. Belching in Gastroesophageal Reflux Disease: Literature Review. J Clin Med. 2020;9(10):3360. https://doi.org/10.3390/jcm9103360
4. Koukias N, Woodland P, Yazaki E, Sifrim D. Supragastric Belching: Prevalence and Association With Gastroesophageal Reflux Disease and Esophageal Hypomotility. J Neurogastroenterol Motil. 2015;21(3):398-403. https://doi.org/10.5056/jnm15002
5. Kessing BF, Bredenoord AJ, Smout AJ. The pathophysiology, diagnosis and treatment of excessive belching symptoms. Am J Gastroenterol. 2014;109(8):1196-1203. https://doi.org/10.1038/ajg.2014.165
6. Lang IM. The Physiology of Eructation. Dysphagia. 2016;31(2):121-133. https://doi.org/10.1007/s00455-015-9674-6
7. Kessing BF, Bredenoord AJ, Smout AJ. The pathophysiology, diagnosis and treatment of excessive belching symptoms. Am J Gastroenterol. 2014;109(8):1196-203. https://doi.org/10.1038/ajg.2014.165
8. Salazar Quero JC, Moya Jiménez MJ, Rubio Murillo M, Roldán Pérez S, Rodríguez Martínez A, Valverde Fernández J. Supragastric belches. An entity to know. Gastroenterol Hepatol. 2017;40(6):396-397. https://doi.org/10.1016/j.gastrohep.2016.05.004
9. Ravi K, Katzka DA. Esophageal Impedance Monitoring: Clinical Pearls and Pitfalls. Am J Gastroenterol. 2016;111(9):1245-1256. https://doi.org/10.1038/ajg.2016.256
10. Ooi JL, Vardar R, Sifrim D. Supragastric belching. Curr Opin Gastroenterol. 2016;32(4):302-309. https://doi.org/10.1097/MOG.0000000000000276
11. Glasinovic E, Wynter E, Arguero J, Ooi J, Nakagawa K, Yazaki E, et al. Treatment of supragastric belching with cognitive behavioral therapy improves quality of life and reduces acid gastroesophageal reflux. Am J Gastroenterol. 2018;113(4):539-547. https://doi.org/10.1038/ajg.2018.15
12. Velosa M, Sergeev I, Sifrim D. Management of supragastric belching. Neurogastroenterol Motil. 2022;34(2):e14316. https://doi.org/10.1111/nmo.14316
13. Punkkinen J, Nyyssönen M, Walamies M, Roine R, Sintonen H, Koskenpato J, et al. Behavioral therapy is superior to follow-up without intervention in patients with supragastric belching-A randomized study. Neurogastroenterol Motil. 2022;34(2):e14171. https://doi.org/10.1111/nmo.14171
14. Sawada A, Anastasi N, Green A, Glasinovic E, Wynter E, Albusoda A, et al. Management of supragastric belching with cognitive behavioural therapy: factors determining success and follow-up outcomes at 6-12 months post-therapy. Aliment Pharmacol Ther. 2019;50(5):530-537. https://doi.org/10.1111/apt.15417
15. Ten Cate L, Herregods TVK, Dejonckere PH, Hemmink GJM, Smout AJPM, Bredenoord AJ. Speech Therapy as Treatment for Supragastric Belching. Dysphagia. 2018;33(5):707-715. https://doi.org/10.1007/s00455-018-9890-y
16. Katzka DA. Simple office-based behavioral approach to patients with chronic belching. Dis Esophagus. 2013;26(6):570-573. https://doi.org/10.1111/dote.12006
17. Moshiree B, Drossman D, Shaukat A. AGA Clinical Practice Update on Evaluation and Management of Belching, Abdominal Bloating, and Distention: Expert Review. Gastroenterology. 2023:S0016-5085(23)00823-5. https://doi.org/10.1053/j.gastro.2023.04.039
18. Riehl ME, Kinsinger S, Kahrilas PJ, Pandolfino JE, Keefer L. Role of a health psychologist in the management of functional esophageal complaints. Dis Esophagus. 2015;28(5):428-36. https://doi.org/10.1111/dote.12219
19. Kunte H, Kronenberg G, Fink K, Harms L, Hellweg R. Successful treatment of excessive supragastric belching by combination of pregabalin and baclofen. Psychiatry Clin Neurosci. 2015;69(2):124-5. https://doi.org/10.1111/pcn.12223
20. Blondeau K, Boecxstaens V, Rommel N, Farré R, Depeyper S, Holvoet L, et al. Baclofen improves symptoms and reduces postprandial flow events in patients with rumination and supragastric belching. Clin Gastroenterol Hepatol. 2012;10(4):379-84. https://doi.org/10.1016/j.cgh.2011.10.042

https://doi.org/10.22516/25007440.1172

Original article

Mortality from Colon, Rectal, and Anal Cancer in Barranquilla Between 1985 and 2020

Adalgisa Alcocer-Olaciregui,[1] Paula Chamorro-Piñeros,[2] Sara Niño-Castro,[2] Stefanía Saucedo-Jiménez,[2] Rusvelt Vargas-Moranth.[3*]

OPEN ACCESS

Citation:
Alcocer-Olaciregui A, Chamorro-Piñeros P, Niño-Castro S, Saucedo-Jiménez S, Vargas-Moranth R. Mortality from Colon, Rectal, and Anal Cancer in Barranquilla Between 1985 and 2020. Revista. colomb. Gastroenterol. 2024;39(3):260-266.
https://doi.org/10.22516/25007440.1172

[1] Systems Engineer, Master in Epidemiology. Faculty Member of the Medicine Program, Universidad Libre. Barranquilla, Colombia.
[2] Medical Student, Universidad Libre. Barranquilla, Colombia.
[3] Physician, Master in Public Health, PhD in Biomedical Sciences, Universidad Libre. Centro Cancerológico del Caribe. Barranquilla, Colombia.

***Correspondence:** Rusvelt Vargas-Moranth.
rusphd@gmail.com

Received: 19/01/2024
Accepted: 22/04/2024

Abstract

Introduction: Colorectal cancer is the third most common neoplasm worldwide, and Colombia is no exception. It is essential to study mortality from this condition in specific regions, as variations have been found even within the same country. The objective is to describe the mortality trends from colorectal cancer in the district of Barranquilla between 1985 and 2020. **Methodology:** A descriptive and retrospective study. Non-fetal death records with colorectal cancer as the underlying cause of death were analyzed from the National Administrative Department of Statistics (DANE) website for residents in Barranquilla between 1985 and 2020. Crude mortality rates were calculated for the years studied, along with the annual percentage changes in these rates. **Results:** A total of 3,201 deaths from colorectal cancer were recorded, with 59.6% in women and 21.7% in individuals aged 80 years or older. There was an increase in the age-adjusted mortality rate (per 100,000), from 5.1 to 12.7. Overall, there was an upward trend in the annual percentage changes in mortality rates. **Conclusion:** An increase in colorectal cancer mortality was observed in the district of Barranquilla. It is necessary to continue this line of research and investigate factors related to this trend.

Keywords

Mortality, Cancer, Colon, Rectum, Anus.

INTRODUCTION

Colon, rectal, and anal cancer (CRAC) is one of the most significant malignancies worldwide. According to the Global Cancer Observatory (GLOBOCAN), in 2020, there were 1,931,590 new cases, accounting for 10% of global cancer incidence, making it the third most common tumor after breast and lung cancer. Just over 50% of these incident cases occurred in men. Regarding mortality, this cancer accounts for 9.4% of all cancer-related deaths, second only to lung cancer, which accounts for 18%[1].

Early detection through screening and the removal of adenomatous polyps[2,3], as well as advances in treatment and increased survival rates for CRAC[4,5], may partly explain the declining mortality trends in high-income countries[6]. In contrast, most transitioning countries face significant challenges in achieving such trends due to limited resources, inadequate healthcare infrastructure, and consequently, a lack of effective screening[7], along with difficulties in accessing oncology services and appropriate care[8].

In Colombia, according to data from the High-Cost Account (CAC in Spanish), colon and rectal cancer ranks

© 2024 Asociación Colombiana de Gastroenterología

as the third most common tumor nationally. In 2019, 3,420 new cases of this pathology were identified, with a distribution of 47.87% in men and 52.13% in women. That same year, 2,384 deaths from colorectal cancer were recorded across Colombia[9]. In 2012, guidelines for the Integrated Health Care Pathway for the Promotion and Maintenance of Health for the early detection of colon and rectal cancer were introduced in Resolution 4505, later amended by Resolution 3280 in 2018[10].

In Barranquilla, some risk management indicators tracked by the CAC may be showing challenges in implementing the Integrated Health Care Pathway for the Promotion and Maintenance of Health. The proportion of patients with *in situ* CRAC is within a low compliance range (1.32%), lower than the national figure of 1.76%[11]. This highlights the limited intervention in the primary care of the disease and the lack of preventive measures, such as identifying patients with risk factors for developing CRAC and those eligible for diagnostic tests aimed at detecting primary or suggestive lesions of first-degree cancer, such as in situ *CRAC*.

Given the above, and considering the need to understand mortality trends for CRAC over an extended period, as well as the absence of similar published studies concerning Barranquilla, a key city in the Colombian Caribbean, the aim of this study was to determine the mortality trends from colorectal cancer in the Barranquilla district between 1985 and 2020.

MATERIALS AND METHODS

This is a descriptive, retrospective study. The study population consisted of non-fetal deaths that occurred in Barranquilla between 1985 and 2020. The sample included all records in which the underlying cause of death was CRAC, from non-fetal deaths occurring in Barranquilla, using ICD-10 codes: C18-C20 and ICD-9 codes: 153.0-154.1. Incomplete records, or those lacking data on sex, age, or habitual residence, were excluded.

The sources of information for the research were secondary. Databases of anonymized non-fetal death records were downloaded from the website of the National Administrative Department of Statistics (DANE). The data were filtered for residents of Barranquilla to obtain the relevant sample. Population projections and retro-projections based on the 2018 DANE Census were also downloaded for the years covered in the study. Age-adjusted mortality rates were calculated using the direct method, with the SEGI population as the reference[12]. The relative variation of the age-adjusted mortality rate was calculated by year.

This research was approved by the Ethics Committee of Universidad Libre, Barranquilla branch. It is supported by the legal framework of Resolution 8430 of 1993, Article 5, which primarily considers the criteria of respect, dignity, and protection of human rights. According to this classification, the present study is risk-free, as it only involves retrospective documentary research techniques and methods[13].

RESULTS

A total of 3,201 deaths from colorectal cancer (CRC) occurred during the observation period. In both men and women, the number of deaths increased over the years. In 1985, 28 deaths were recorded, while in 2006, the numbers surpassed 100; in 2017, the figure reached 208, with a peak of 214 deaths occurring in 2020. Also, in most years, the percentage of cases was higher among women, reaching its peak in 2008 with 69.2% (**Figure 1**).

Regarding the distribution by age groups (**Figure 2**), a trend of increasing deaths was found as age increased, with a peak in those over 80 years old, representing 21.74% of the deaths. It is noteworthy that the age group 15 to 19 years had a percentage of 5.62%.

In terms of the age-adjusted mortality rate for CRC, 2017 recorded the highest rate, with 13.8 deaths per 100,000 inhabitants. This year also showed the highest mortality rate among women during the study period, with 13.26 deaths per 100,000 women. Among men, the highest rate was recorded in 2020, with 17.2 deaths per 100,000 (**Table 1**).

The mortality rate showed an increase of 147.4% between 1985 and 2020. Regarding the annual percentage changes in mortality (**Figure 3**), there was an increase, particularly between 1988 and 1989, with a 71.8% rise. On the other hand, the largest decrease occurred between 1986 and 1987, with a negative variation of 39.6%.

DISCUSSION

The analysis of CRAC incidence worldwide reveals a significant increase over the years, which has been linked to various factors such as dietary habits, obesity, tobacco and alcohol consumption, and lack of physical activity, among others[14].

Despite this rise in incidence, it is interesting to note that it does not always directly translate into a higher mortality rate. According to Wong and colleagues[15], mortality can be significantly influenced by access to early detection services and advanced therapies. This finding is supported by Breugom and collaborators[16], who demonstrated that in Europe, the mortality rate has decreased thanks to improvements in staging, access to effective treatments, standardization of care, and the implementation of surgical audits.

In contrast to these results, a different scenario emerges in Barranquilla. Firstly, there is a notable trend of a steady increase in the number of deaths throughout the study period, which may be attributed to various determinants,

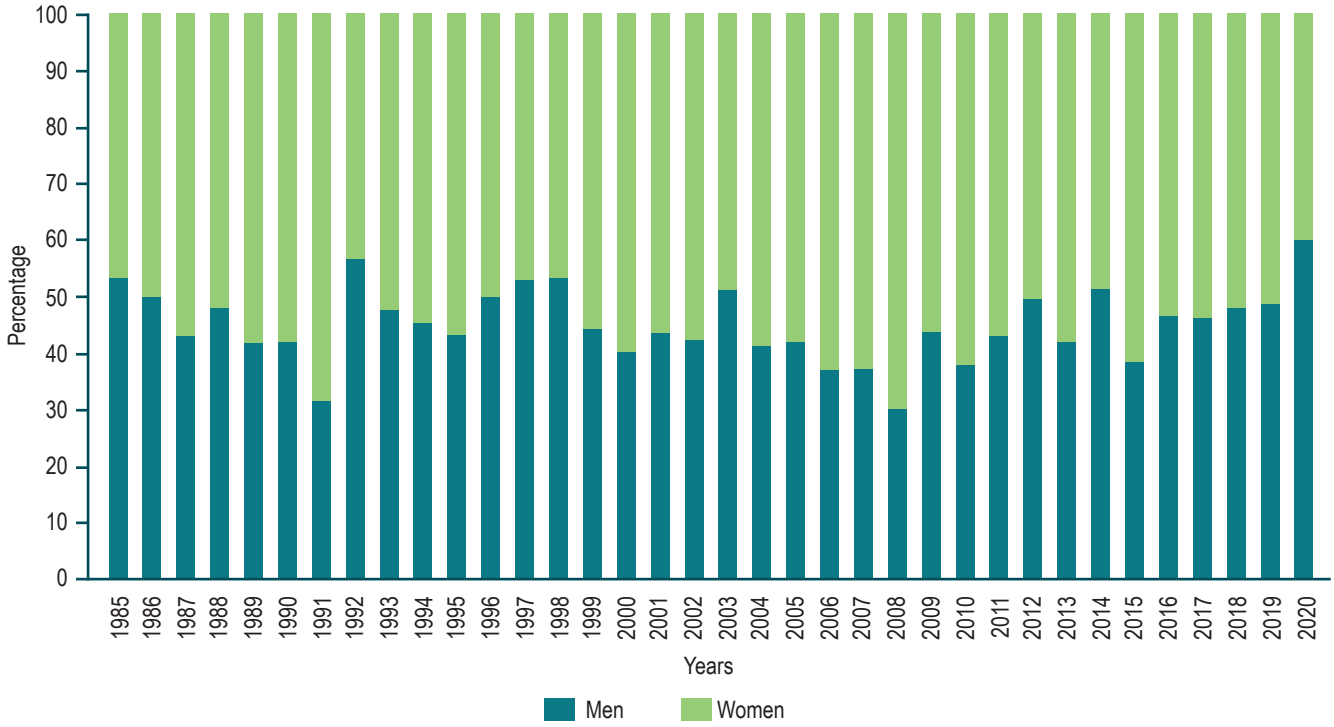

Figure 1. Percentage distribution of deaths from colon, rectal, and anal cancer in Barranquilla between 1985 and 2020, by sex. Prepared by the authors using DANE, Vital Statistics data.

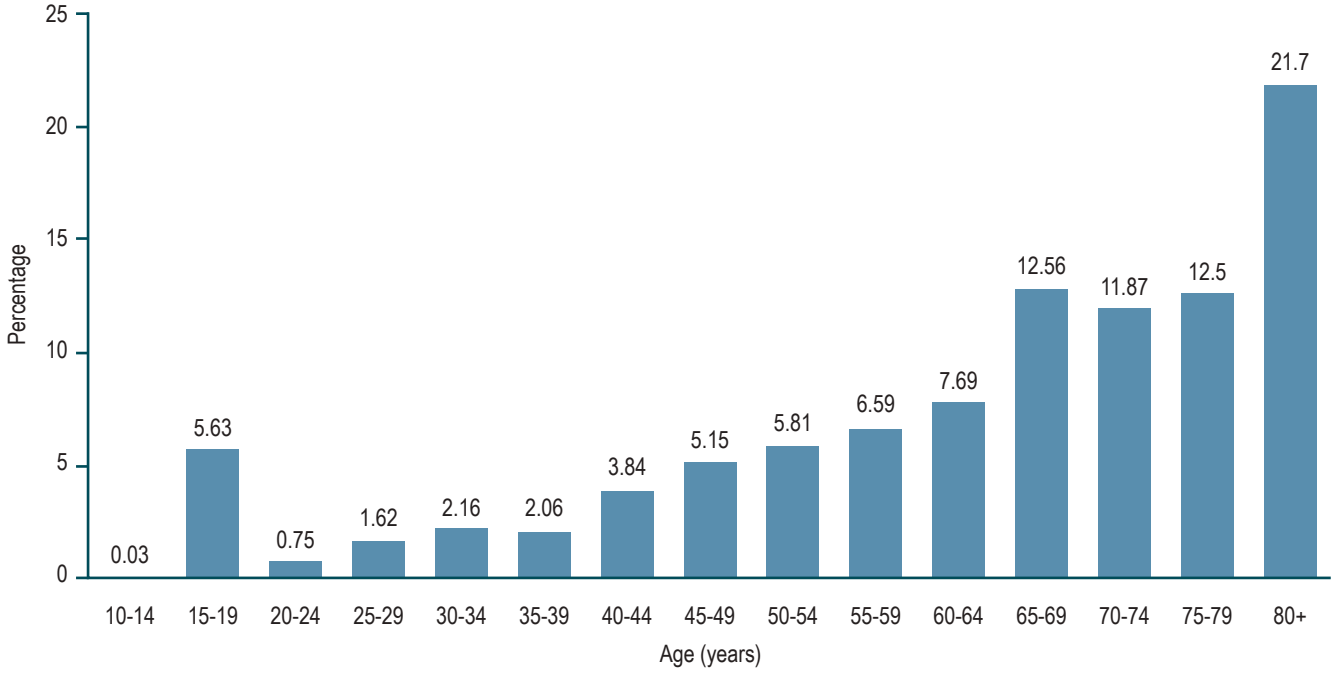

Figure 2. Percentage distribution of deaths from colon, rectal, and anal cancer in Barranquilla between 1985 and 2020, by age groups. Prepared by the authors using DANE, Vital Statistics data.

Table 1. Age-adjusted mortality rates (AAMR) for colon, rectal, and anal cancer in Barranquilla between 1985 and 2020

Year	Age-Adjusted Rate per 100,000			Year	Age-Adjusted Rate per 100,000		
	Men	Women	Total		Men	Women	Total
1985	5.74	4.60	5.11	2003	9.39	7.05	8.10
1986	6.56	5.54	6.01	2004	7.33	8.34	7.91
1987	3.91	3.36	3.63	2005	5.79	5.37	5.59
1988	4.16	3.66	3.86	2006	7.48	10.38	8.98
1989	5.92	7.11	6.62	2007	6.87	7.83	7.45
1990	4.32	5.12	4.74	2008	6.44	10.87	9.00
1991	3.80	7.18	5.66	2009	9.29	9.44	9.38
1992	5.58	3.48	4.41	2010	7.54	9.63	8.71
1993	6.90	5.97	6.39	2011	7.14	6.79	6.92
1994	6.94	7.55	7.24	2012	11.15	8.48	9.66
1995	5.96	6.85	6.47	2013	8.16	8.17	8.18
1996	7.40	5.52	6.41	2014	12.63	8.74	10.42
1997	8.93	6.61	7.60	2015	9.15	11.38	10.41
1998	9.22	5.92	7.39	2016	12.62	10.31	11.32
1999	7.84	8.14	8.10	2017	14.74	13.26	13.88
2000	7.05	8.38	7.89	2018	14.60	11.98	13.16
2001	6.20	6.25	6.22	2019	12.70	10.89	11.60
2002	6.64	6.97	6.90	2020	17.21	9.39	12.68

Prepared by the authors using DANE, Vital Statistics data.

ranging from changes in detection and diagnostic patterns to possible risk factors within the population.

Another notable finding is the higher predisposition of women to die from CRC. In 2008, the highest number of deaths among females was recorded. However, it is important to note that this predisposition does not remain consistent over time. By age group, there is a trend of increasing risk of death as age advances, similar to global patterns[15], which underscores the importance of early detection and medical care in older adult populations. Surprisingly, the age group of 15 to 19 years also shows a significant percentage. This unusual finding warrants further investigation to better understand its underlying causes.

Despite efforts and strategies implemented by the Colombian government through the Ministry of Health to improve the situation, mortality has continued to rise in this city. This raises questions about the effectiveness of the measures taken. Risk management indicators show a low percentage of patients with CRAC classified as *in situ* (1.32%), and only 75.76% of patients are stratified according to the TNM staging system. These, along with other indicators, highlight the difficulties in implementing the Integrated Health Care Pathway for the Promotion and Maintenance of Health. This suggests that medical care in Barranquilla may not be meeting the desired standards.

However, determining the reasons for the increase in mortality in the city is beyond the scope of this study. Particularly, with a steady rise in the number of deaths throughout the study period, a variety of factors could be involved, ranging from changes in detection and diagnostic patterns to potential risk factors in the population. Therefore, it is considered appropriate to link mortality

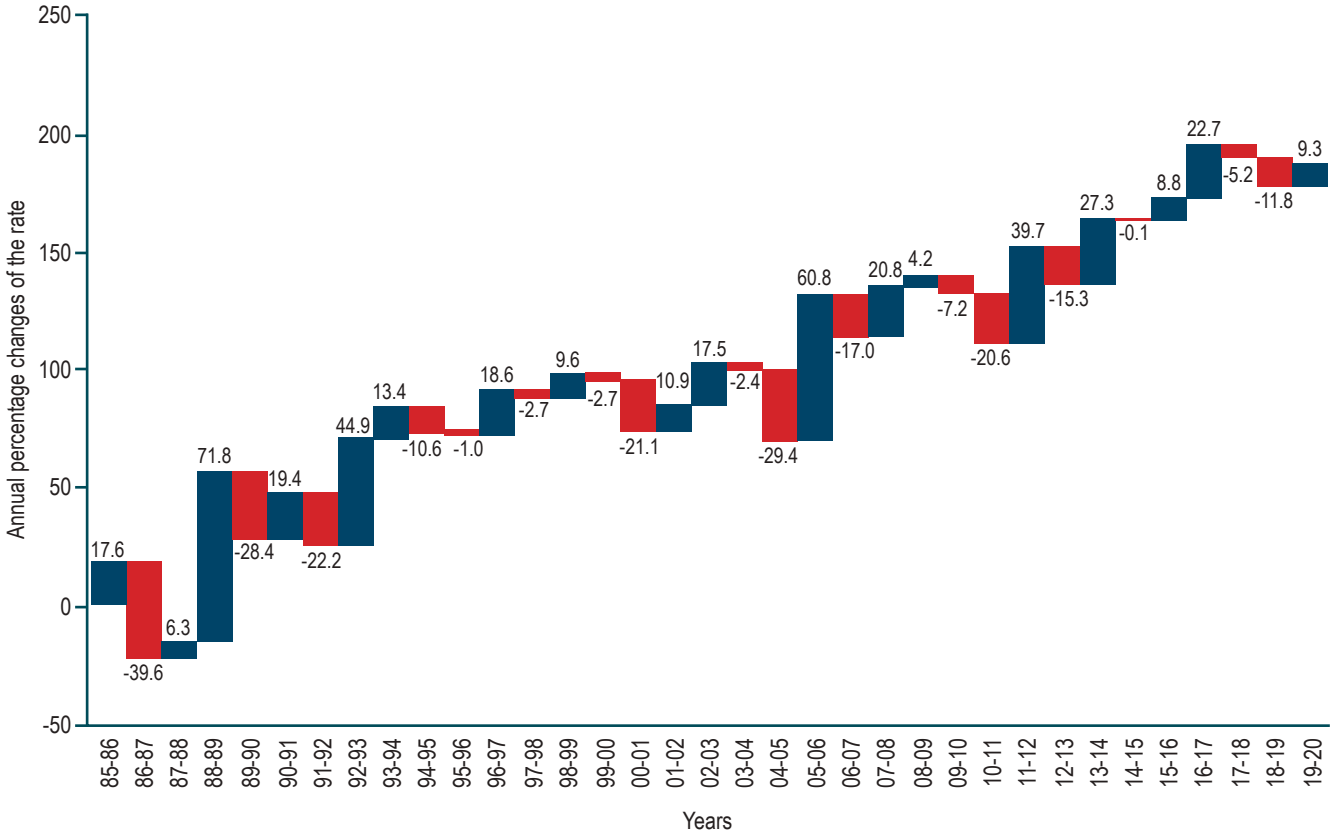

Figure 3. Annual percentage changes (APC) (%) in mortality from colon, rectal, and anal cancer in Barranquilla between 1985 and 2020. Prepared by the authors using DANE, Vital Statistics data.

with rates of premalignant lesions, the number of units equipped to provide early detection and diagnostic services, the percentages of colonoscopies ordered and performed, the timeliness of care, and the level of knowledge among healthcare professionals on the subject.

Additionally, the type of treatment received should be reviewed, as mortality increases when surgery is the only option available without complementary therapy[17-19]. Delays in diagnosis, referral, and treatment, along with cultural beliefs and financial limitations, can also account for most of the mortality[20].

As a limitation, it is important to mention that there may have been underreporting of mortality, especially in the early years studied, when a death certificate was not required to access funeral services. Additionally, it should be noted that population-based indicators require knowledge of the number of individuals in the area. Population censuses are a mechanism to determine the number of inhabitants; however, due to the costs involved, the country conducts them every ten years. Projections are made based on this data to estimate population sizes until a new census is conducted, and these projections are adjusted with retroprojections based on past censuses. These changes affect the behavior of the indicators, as the risk estimates, such as mortality from CRAC, could be under- or overestimated prior to census adjustments.

CONCLUSIONS

The global increase in the incidence of CRAC and its relationship with various risk factors highlights the importance of early detection strategies and advanced treatments. However, despite governmental efforts, mortality from CRAC in Barranquilla has increased, potentially indicating deficiencies in healthcare and in the implementation of disease prevention and control programs.

Overall, these results provide a comprehensive picture of the evolution of CRC mortality in Barranquilla over the decades. These findings could be critical for formulating public health strategies focused on early detection and education about the disease across all age groups and sexes.

REFERENCES

1. Sung H, Ferlay J, Siegel R, Laversanne M, Soerjomataram I, Jemal A, et al. Global cancer statistics 2020: GLOBOCAN estimates of incidence and mortality worldwide for 36 cancers in 185 countries. CA Cancer J Clin. 2021; 71(3):209-249. https://doi.org/10.3322/caac.21660
2. Shaukat A, Kahi C, Burke C, Rabeneck L, Sauer B, Rex D. ACG clinical guidelines: colorectal cancer screening 2021. Am J Gastroenterol. 2021;116(3):458-479. https://doi.org/10.14309/ajg.0000000000001122
3. Davidson K, Barry M, Mangione C, Cabana M, Caughey A, Davis E, et al. Screening for colorectal cancer: US Preventive Services Task Force recommendation statement. JAMA. 2021;325(19):1965-1977. https://doi.org/10.1001/jama.2021.6238
4. Rawla P, Sunkara T, Barsouk A. Epidemiology of colorectal cancer: incidence, mortality, survival, and risk factors. Prz Gastroenterol. 2019;14(2):89-103. https://doi.org/10.5114/pg.2018.81072
5. Biller L, Schrag D. Diagnosis and treatment of metastatic colorectal cancer: a review. JAMA. 2021;325(7):669-685. https://doi.org/10.1001/jama.2021.0106
6. Araghi M, Soerjomataram I, Bardot A, Ferlay J, Cabasag C, Morrison D, et al. Changes in colorectal cancer incidence in seven high-income countries: a population-based study. Lancet Gastroenterol Hepatol. 2019;4(7):511-518. https://doi.org/10.1016/S2468-1253(19)30147-5
7. Carethers J, Doubeni C. Causes of socioeconomic disparities in colorectal cancer and intervention framework and strategies. Gastroenterology. 2020;158(2):354-367. https://doi.org/10.1053/j.gastro.2019.10.029
8. Sharma R. An examination of colorectal cancer burden by socioeconomic status: evidence from GLOBOCAN 2018. EPMA J. 2020;11(1):95-117. https://doi.org/10.1007/s13167-019-00185-y
9. Cuenta de Alto Costo. HIGIA, Indicadores de la gestión del riesgo [Internet]. CAC; 2023 [consultado el 3 de marzo de 2023]. Disponible en: https://cuentadealtocosto.org/investigaciones/boletin-3-indicadores-de-la-gestion-del-riesgo/
10. Ministerio de Salud y Protección Social. Resolución 3280 de 2018, por medio de la cual se adoptan los lineamientos técnicos y operativos de la Ruta Integral de Atención para la Promoción y Mantenimiento de la Salud y la Ruta Integral de Atención en Salud para la Población Materno Perinatal y se establecen las directrices para su operación. Colombia: Ministerio de Salud y Protección social; 2018.
11. Cuenta de Alto Costo. HIGIA, Indicadores demográficos [Internet] CAC; 2023 [consultado el 3 de marzo de 2023]. Disponible en: https://cuentadealtocosto.org/site/higia/cancer-indicadores-demografico/
12. Organización Panamericana de la Salud. La Estandarización: Un Método Epidemiológico Clásico para la Comparación de Tasas. Boletín Epidemiológico. 2002;23(3):9-12.
13. Ministerio de Salud y Protección Social. Resolución Número 8430 de 1993, por la cual se establecen las normas científicas, técnicas y administrativas para la investigación en salud. Colombia: Ministerio de Salud; 1993.
14. Araghi M, Soerjomataram I, Jenkins M, Brierley J, Morris E, Bray F, et al. Global trends in colorectal cancer mortality: projections to the year 2035. Int J Cancer. 2019;144(12):2992-3000. https://doi.org/10.1002/ijc.32055
15. Wong M, Huang J, Lok V, Wang J, Fung F, Ding H, et al. Differences in incidence and mortality trends of colorectal cancer worldwide based on sex, age, and anatomic location. Clin Gastroenterol Hepatol. 2021;19(5):955-966. https://doi.org/10.1016/j.cgh.2020.02.026
16. Breugom A, Bastiaannet E, Dekker JWT, Wouters MWJM, van de Velde CJH, Liefers GJ. Decrease in 30-day and one-year mortality over time in patients aged ≥75 years with stage I-III colon cancer: A population-based study. Eur J Surg Oncol. 2018;44(12):1889-1893. https://doi.org/10.1016/j.ejso.2018.08.010
17. Shi J, Sun Z, Gao Z, Huang D, Hong H, Gu J. Radioimmunotherapy in colorectal cancer treatment: present and future. Front Immunol. 2023;14(1):1105180. https://doi.org/10.3389/fimmu.2023.1105180
18. Sveen A, Kopetz S, Lothe R. Biomarker-guided therapy for colorectal cancer: strength in complexity. Nat Rev Clin Oncol. 2020; 17(1): 11-32. https://doi.org/10.1038/s41571-019-0241-1
19. Hossain M, Karuniawati H, Jairoun A, Urbi Z, Ooi D, John A, et al. Colorectal cancer: a review of carcinogenesis, global epidemiology, current challenges, risk factors, preventive and treatment strategies. Cancers (Basel). 2022;14(7):1732. https://doi.org/10.3390/cancers14071732
20. Barrios C, Werutsky G, Mohar A, Ferrigno A, Müller B, Bychkovsky B, et al. Cancer control in Latin America and the Caribbean: recent advances and opportunities to move forward. Lancet Oncol. 2021;22(11):e474-e487. https://doi.org/10.1016/S1470-2045(21)00492-7

https://doi.org/10.22516/25007440.1166

Original article

Epidemiology of Acute Cholecystitis in Colombia: An Analysis of Official Records from the Ministry of Health

Juan Felipe Otálora-Esteban,[1*] Juan S. Hernández-Meza,[1] Diego Rosselli.[2]

OPEN ACCESS

Citation:
Otálora-Esteban JF, Hernández-Meza JS, Rosselli D. Epidemiology of Acute Cholecystitis in Colombia: An Analysis of Official Records from the Ministry of Health. Revista. colomb. Gastroenterol. 2024;39(3):267-273.
https://doi.org/10.22516/25007440.1166

[1] Physician, Medical School, Pontificia Universidad Javeriana. Bogotá, Colombia.
[2] Professor, Department of Clinical Epidemiology and Biostatistics, Pontificia Universidad Javeriana. Bogotá, Colombia.

***Correspondence:** Juan Felipe Otálora-Esteban.
otalorajuanf@javeriana.edu.co

Received: 27/12/2023
Accepted: 06/06/2024

Abstract

Introduction: Acute cholecystitis is one of the most common complications of cholelithiasis. In Colombia, there are no studies on its prevalence or the sociodemographic characteristics of the affected population. **Objectives:** To establish the prevalence of acute cholecystitis in Colombia and describe the associated sociodemographic characteristics. **Materials and Methods:** A descriptive cross-sectional study was conducted using data from the individual service provision records (RIPS) from 2018 to 2022. **Results:** A total of 343,254 cases of acute cholecystitis were identified in Colombia, with a prevalence of 681 cases per 100,000 inhabitants and a female-to-male ratio of 2.3:1. The highest number of reported cases was in the 34 to 39-year age group. The departments with the most cases are located in the southeast of the country, including Nariño, Valle del Cauca, Caquetá, and Tolima. **Conclusion:** This study presents epidemiological and sociodemographic information on acute cholecystitis in Colombia. There are few epidemiological studies on this disease in Latin America, however, the prevalence found is similar to that reported in countries like the United States.

Keywords

Cholelithiasis, Acute Cholecystitis, Prevalence, Epidemiology.

INTRODUCTION

In 2018, cholelithiasis and cholecystitis ranked as the second most common gastrointestinal diagnosis in hospitals in the United States, with a total of 316,200 hospitalizations per year and a visit rate of 99.2 per 100,000 people. Additionally, they were identified as the fifth leading cause of readmissions in emergency services[1,2]. Gallbladder disorders are particularly important in the differential diagnosis of abdominal pain, which is the primary reason for emergency consultations among the adult population. Similarly, acute cholecystitis is one of the main conditions that may require surgical intervention[3].

The majority of cholelithiasis cases develop asymptomatically[4], and many are discovered incidentally during diagnostic imaging studies. However, the presence of symptoms and a lack of timely treatment can lead to significant complications such as acute cholecystitis, choledocholithiasis, cholangitis, or acute pancreatitis. Among these complications, acute cholecystitis stands out as one of the most common and is considered a leading cause of complicated intra-abdominal infections according to data from the World Society of Emergency Surgery (WSES)[5]. Although cholelithiasis is more common in women, the associated complications are more frequent in men[6].

In Colombia, there are isolated epidemiological reports of the prevalence of cholelithiasis in patients with functional dyspepsia[7], cholecystitis in histopathological studies[8,9], and hospital records[9]; however, there are no studies on the national prevalence of this condition. The Individual Records of Health Service Provision (RIPS in Spanish), which document more than 500 million patient contacts with the health system each year[10], have been widely used both to estimate the prevalence of numerous conditions such as rheumatoid arthritis[11] or Sjögren's syndrome[12], and for studies on the burden of disease attributable to obesity and overweight[13] or gastric cancer[14].

Given its frequent presentation and the significant morbidity burden it represents, the objective of this study was to establish the prevalence of acute cholecystitis and describe the sociodemographic characteristics of patients in Colombia using the RIPS data.

METHODS

This is a descriptive cross-sectional study using information from the Individual Records of Health Service Provision (RIPS). The sociodemographic information (sex, age, and location of care) of all individuals diagnosed with acute cholecystitis and cholelithiasis across the entire country, covering all health system enrollment schemes between 2018 and 2022, was extracted from the records. The filter "persons attended" was applied using the International Classification of Diseases (ICD-10) codes for acute cholecystitis and cholelithiasis (codes K800, K801, K804, K810, K818, and K819), and data on procedures were also gathered according to the Unified Classification of Health Procedures (CUPS in Spanish) for cholecystectomy (code 5121). A database was created in Microsoft Excel 2016, where the data were categorized by sex, age in years and in five-year age groups, and geographical divisions by department. For prevalence calculations, the official data from the National Administrative Department of Statistics (DANE) for 2019, projected from the 2018 national census, were used as the denominator. A description of the data obtained, including frequencies and prevalence rates per 100,000 inhabitants, was then conducted.

Since this was a secondary analysis of consolidated, anonymized, and publicly accessible data, it was deemed unnecessary to seek approval from a research ethics committee.

RESULTS

Between January 2018 and December 2022, a total of 599,250 individuals were diagnosed with cholelithiasis without cholecystitis (449,918 women, 75.1%), which represents 1.18% of the general population. There were 343,254 cases of acute cholecystitis (240,193 women, 69.9%), with an unadjusted prevalence of 681 cases per 100,000 inhabitants (942 per 100,000 women, 414 per 100,000 men), resulting in a female-to-male ratio of 2.3:1. Of these patients, 24,876 (7.2%) had associated choledocholithiasis. Additionally, 92,964 cholecystectomies were performed in patients with acute cholecystitis (accounting for 27.1% of these patients); however, during the same period, a total of 278,386 cholecystectomies were recorded.

On a national level, the departments with the highest prevalence of acute cholecystitis were Nariño with 1,035 per 100,000 inhabitants, Valle del Cauca (1,027 per 100,000), followed by Caquetá (917 per 100,000) and Tolima (844 per 100,000), all located in the southwestern region of the country. The number of cases per department is shown in **Table 1**.

The prevalence of acute cholecystitis by sex was 942 per 100,000 inhabitants for women and 414 per 100,000 inhabitants for men. The female sex showed a higher number of cases in all departments and age groups for each of the years analyzed. The age group with the highest number of cases was the 35-39 age group, with 32,858 cases, followed by the 30-34 age group (31,876 cases) and the 40-44 age group (30,748 cases). However, the prevalence of the disease consistently increased across all age groups, with the highest prevalence found in those over 80 years old (2,788 per 100,000 inhabitants). Cases in the pediatric population (aged 0 to 14 years) represented 2.3% of all reported acute cholecystitis cases during the period analyzed, with a prevalence of 63 per 100,000 inhabitants. The number of cases by age group and sex is shown in **Table 2**. The prevalence data by department during the period from 2018 to 2022 are illustrated in **Figure 1.**

DISCUSSION

According to official records from the Ministry of Health, nearly 600,000 people were diagnosed with cholelithiasis in Colombia over the five-year period from 2018 to 2022, with 70% of them being women. This finding aligns with reports in the literature, which describe that women are almost twice as likely as men to develop gallstones. The main established risk factors include female sex hormones (which explains the reduction in cases after menopause), parity, the use of oral contraceptives, and estrogen replacement therapy. The pathophysiological explanation is that estrogens increase cholesterol secretion and reduce bile salt secretion, while progestins decrease bile salt secretion and alter gallbladder emptying, which can lead to stasis[2].

Traditionally, it is described that cholelithiasis and cholecystitis are more common in women around the age of 40, during their reproductive years, and in those with obesity. Although the results show a higher number of cases in

Table 1. Number of Cases of Acute Cholecystitis and Prevalence per 100,000 Inhabitants by Department for the Five-Year Period 2018-2022

Department	Cases	Prevalence
Amazonas	504	632
Antioquia	42.493	628
Arauca	1336	489
Atlántico	17.332	673
Bogotá	61.890	747
Bolívar	8894	405
Boyacá	8432	657
Caldas	6750	678
Caquetá	4608	917
Casanare	2306	604
Cauca	10.227	717
Cesar	8087	750
Chocó	409	79
Córdoba	9199	507
Cundinamarca	14.892	523
Guainía	123	279
Guaviare	654	557
Huila	10.061	831
La Guajira	5530	518
Magdalena	8642	658
Meta	6310	610
Nariño	18.949	1.035
Norte de Santander	11.252	802
Putumayo	1973	542
Quindío	4542	785
Risaralda	4871	501
San Andrés	165	209
Santander	15.020	715
Sucre	6049	683
Tolima	12.018	844
Valle del Cauca	49.337	1.027
Vaupés	59	130
Vichada	246	311
Total	**343.254**	**681**

Source: Individual Records of Health Service Provision (RIPS), official SISPRO data.

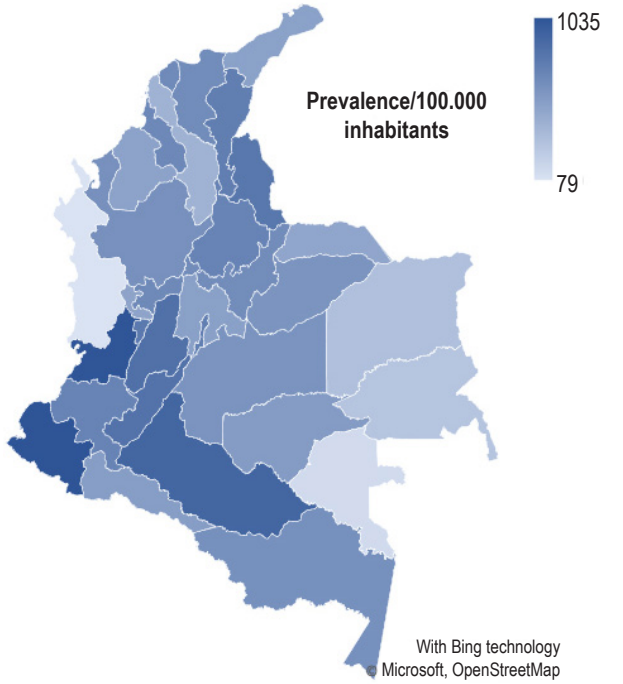

Figure 1. Prevalence by Department of Acute Cholecystitis per 100,000 Inhabitants in Colombia between 2018 and 2022. Source: Individual Records of Health Service Provision (RIPS), official SISPRO data.

women (with a ratio of 2.3 to 1 compared to men), and the highest prevalence in the 35-39 age group, the prevalence of the disease increases with age, a finding similar to that reported in international literature[15].

One noteworthy point is that, according to this registry, the pediatric population accounts for 2.3% of all acute cholecystitis cases in Colombia. Several studies have shown that this condition has been increasing in children over the past 20 years, and the acalculous variant accounts for 50% to 70% of all reported cases. In 2016 alone, pancreatobiliary diseases were the fourth most common cause of pediatric gastrointestinal emergency visits in U.S. hospitals, with cholelithiasis and cholecystitis comprising the largest group, totaling 10,948 cases, with an average hospitalization cost of USD 37,607[2]. This is even more significant considering the association of acalculous cholecystitis in this age group with viral infections (such as Epstein-Barr and hepatitis A), systemic lupus erythematosus, and Kawasaki disease[16]. The cause of the increasing prevalence of cholecystitis in this population remains under investigation. Some studies suggest the global rise in childhood obesity, as well as the earlier onset of puberty, which in females triggers an earlier hormonal influence, thereby increasing the risk of developing this disease[17,18].

Table 2. Number of Individuals Diagnosed with Acute Cholecystitis in Colombia and Prevalence per 100,000 by Five-Year Age Groups and Sex between 2018 and 2022

Age (years)	Cases		Prevalence		
	Men	Women	Men	Women	Total
0 to 4	1357	2222	61	104	82
5 to 9	681	725	31	35	33
10 to 14	1316	1825	61	88	74
15 to 19	2178	7048	100	338	216
20 to 24	3418	16.752	156	798	470
25 to 29	5407	23.655	253	1154	695
30 to 34	6832	25.044	355	1318	834
35 to 39	8361	24.497	501	1396	960
40 to 44	8823	21.925	589	1372	993
45 to 49	8715	20.590	645	1398	1038
50 to 54	9367	21.011	700	1417	1077
55 to 59	9745	20.032	813	1494	1173
60 to 64	9126	17.046	964	1569	1287
65 to 69	8525	13.704	1,201	1653	1444
70 to 74	7389	10.76	1,475	1764	1634
75 to 79	6226	8577	1,946	2047	2003
80 or more	8713	12.949	2,782	2793	2788
Total	**103.061**	**240.193**	**414**	**942**	**681**

Source: Individual Records of Health Service Provision (RIPS), official SISPRO data.

Additionally, ethnicity appears to play an important role not only in the prevalence of cholelithiasis but also in the type of gallstones. Cholesterol gallstones are more common in developed Western countries, while brown pigment stones in the bile ducts have historically been more prevalent in Asia. However, in developing Asian countries, there has been a shift from pigment stones to cholesterol stones, which has been attributed to a lower rate of chronic biliary infections and the adoption of a more Westernized diet[19].

As previously mentioned, acute cholecystitis is a common condition worldwide, representing the most frequent complication of cholelithiasis and contributing to increased global mortality from other causes such as cardiovascular diseases and cancer[20]. The presence of gallstones has been associated with a higher risk of gallbladder cancer, bile duct cancer, and ampullary cancer[21].

Notably, the percentage of cholecystectomies performed on patients with acute cholecystitis (27.1%) is below the average reported in other countries, where this procedure can be performed in up to 60% of patients with this diagnosis[1,22]. However, when reviewing the total number of cholecystectomies performed regardless of the associated diagnosis, the numbers increase significantly, suggesting that the majority of these procedures are likely performed on an outpatient basis in Colombia, similar to reports from other countries. In 2019, gallstone disease contributed to approximately 2.2 million outpatient visits in the United States, and 935,000 cholecystectomies were performed, most of them laparoscopic and outpatient (605,000), compared to laparoscopic procedures in hospitalized patients (280,000). This shift in management is due to more efficient intervention in treating this condi-

tion, which has contributed to reducing mortality rates by up to 70%[4].

According to some studies, the prevalence of the disease has increased globally in recent years. This rise has been linked to a greater number of patients with obesity, insulin resistance, and metabolic syndrome[23]. Our study results show a similar increase in prevalence over the years, except for 2020, where a decrease in the number of cases was observed. This finding is related to the COVID-19 pandemic, during which there was a global reduction in consultations for non-communicable diseases due to social isolation measures[24]. In our study, the total number of records of people seen for all causes decreased in 2020, with a 14% reduction compared to 2019.

Despite being a highly prevalent disease globally, there were no national epidemiological data on its sociodemographic distribution in Colombia. Previous national epidemiological studies were based on hospital records or histopathological studies[8,9]. Among the limitations of this study are the common weaknesses in the analysis of administrative databases, including the potential for misclassification of ICD-10 diagnostic codes in medical records by healthcare personnel[25]. Additionally, codes such as "other cholecystitis" may include cases of chronic disease. Another limitation in estimating prevalence and its changes over the years is the increase in the number of care records each year, which may overestimate the disease rate. However, a larger number of annual care records at the departmental level ensures higher quality information and a more reliable report on the disease.

CONCLUSION

This study provides epidemiological information on acute cholecystitis in Colombia, drawn from the Ministry of Health's database. The sociodemographic data align with the sex and age distribution reported in global literature, with the exception of the proportion of cholecystectomies performed, which is lower than the average in other countries. The higher prevalence observed in the southwestern part of the country warrants further studies and opens the door to population-based interventions targeting these regions.

Acknowledgments

Not applicable.

Funding Sources

No funding was received from any organization or individual.

Conflict of Interest

The authors declare no conflict of interest.

REFERENCES

1. Unalp-Arida A, Ruhl CE. Increasing gallstone disease prevalence and associations with gallbladder and biliary tract mortality in the US. Hepatology. 2023;77(6):1882-95. https://doi.org/10.1097/HEP.0000000000000264
2. Peery AF, Crockett SD, Murphy CC, Jensen ET, Kim HP, Egberg MD, et al. Burden and Cost of Gastrointestinal, Liver, and Pancreatic Diseases in the United States: Update 2021. Gastroenterology. 2022;162(2):621-44. https://doi.org/10.1053/j.gastro.2021.10.017
3. Weiss AJ, Jiang HJ. Most frequent reasons for emergency department visits, 2018 [Internet]. HCUP; 2021 [consultado el 11 de noviembre de 2023]. Disponible en: https://hcup-us.ahrq.gov/reports/statbriefs/sb286-ED-Frequent-Conditions-2018.pdf
4. Unalp-Arida A, Ruhl CE. Burden of gallstone disease in the United States population: Prepandemic rates and trends. World J Gastrointest Surg. 2024;16(4):1130-48. https://doi.org/10.4240/wjgs.v16.i4.1130
5. Sartelli M, Coccolini F, Kluger Y, Agastra E, Abu-Zidan FM, Abbas AE, et al. WSES/GAIS/Sis-E/WSIS/AAST Global Clinical Pathways for patients with intra-abdominal infections. World Journal of Emergency Surgery. 2021;16(1). https://doi.org/10.1186/s13017-021-00387-8
6. Bailey KS, Marsh W, Daughtery L, Hobbs G, Borgstrom D. Sex disparities in the presentation of gallbladder disease. Am Surg. 2022;88(2):201-4. https://doi.org/10.1177/0003134821989044
7. Gómez Martín O, Otero W, Rincón J. Frecuencia de colelitiasis en dispepsia funcional, enfermedad por reflujo gastro-esofágico y en pacientes asintomáticos. Rev Colomb Gastroenterol. 2007;22(3):164-72.
8. Fuentes-Díaz OG, Camelo-Pilonieta Y, Selim K, López D. Prevalencia de colecistitis por estudios histopatológicos de los pacientes sometidos a colecistectomía de urgencia con diagnóstico de cólico biliar en el Hospital Militar Central [Tesis de posgrado]. Bogotá D.C.: Universidad Militar Nueva Granada; 2019.
9. Gaitán JA, Martínez VM. Enfermedad litiásica biliar, experiencia en una clínica de cuarto nivel, 2005-2011. Rev Colomb Cir. 2014;29(3):188-96.

10. Rosselli D, Pantoja-Ruiz C. SISPRO: The administrative database of the Colombian healthcare system. Acta Neurol Colomb. 2022;38(4):187-190. https://doi.org/10.22379/24224022426
11. Fernández-Ávila DG, Rincón-Riaño DN, Bernal-Macías S, Gutiérrez-Dávila JM, Rosselli D. Prevalence of rheumatoid arthritis in Colombia based on information from the Ministry of Health registry. Rev Colomb Reumatol. 2019;26(2):83-87. https://doi.org/10.1016/j.rcreu.2019.01.003
12. Fernández-Ávila DG, Rincón-Riaño DN, Bernal-Macías S, Gutiérrez-Dávila JM, Rosselli D. Prevalence and demographic characteristics of Sjögren's syndrome in Colombia, based on information from the official Ministry of Health registry. Reumatol Clín. 2020;16(4):286-89. https://doi.org/10.1016/j.reuma.2018.09.005
13. Gil-Rojas Y, Garzón A, Hernández F, Pacheco B, González D, Campos J, et al. Burden of disease attributable to obesity and overweight in Colombia. Value Health Reg Issues. 2019;20:66-72. https://doi.org/10.1016/j.vhri.2019.02.001
14. Triana JJ, Aristizábal-Mayor JD, Plata MC, Medina M, Baquero L, Gil-Tamayo S, et al. Disease burden of gastric cancer in disability-adjusted life years in Colombia. Rev Colomb Gastroenterol. 2017;32(4):326-31. https://doi.org/10.22516/25007440.175
15. Aerts R, Penninckx F. The burden of gallstone disease in Europe. Aliment Pharmacol Ther. 2003;18:49-53. https://doi.org/10.1046/j.0953-0673.2003.01721.x
16. Poddighe D, Sazonov V. Acute acalculous cholecystitis in children. World J Gastroenterol. 2018;24(43):4870-79. https://doi.org/10.3748/wjg.v24.i43.4870
17. Greer D, Heywood S, Croaker D, Gananadha S. Is 14 the new 40: Trends in gallstone disease and cholecystectomy in Australian children. Pediatric Surgery International. 2018;34(8):845–9. https://doi.org/10.1007/s00383-018-4300-y
18. Krawczyk M, Kułaga Z, Niewiadomska O, Jankowska I, Lebensztejn D, Więcek S, et al. Are children with gallstone disease more overweight? results of a matched case-control analysis. Clin Res Hepatol Gastroenterol. 2023;47(8):102204. https://doi.org/10.1016/j.clinre.2023.102204
19. Figueiredo JC, Haiman C, Porcel J, Buxbaum J, Stram D, Tambe N, et al. Sex and ethnic/racial-specific risk factors for gallbladder disease. BMC Gastroenterology. 2017;17(1): 53. https://doi.org/10.1186/s12876-017-0678-6
20. Ruhl CE, Everhart JE. Gallstone disease is associated with increased mortality in the United States. Gastroenterology. 2011;140(2):508-16. https://doi.org/10.1053/j.gastro.2010.10.060.
21. Huang D, Joo H, Song N, Cho S, Kim W, Shin A. Association between gallstones and the risk of biliary tract cancer: a systematic review and meta-analysis. Epidemiol Health. 2021;43:e2021011. https://doi.org/10.4178/epih.e202101
22. Riall TS, Zhang D, Townsend CM, Kuo Y-F, Goodwin JS. Failure to perform cholecystectomy for acute cholecystitis in elderly patients is associated with increased morbidity, mortality, and cost. J Am Coll Surg. 2010;210(5):668-77, 677-9. https://doi.org/10.1016/j.jamcollsurg.2009.12.031
23. Yuan S, Gill D, Giovannucci EL, Larsson SC. Obesity, type 2 diabetes, lifestyle factors, and risk of gallstone disease: A Mendelian randomization investigation. Clin Gastroenterol Hepatol. 2022;20(3):e529-e537. https://doi.org/10.1016/j.cgh.2020.12.034
24. Yock-Corrales A, Soto-Roldan J, Corella-Elizondo D. Tendencias en las consultas a los servicios de emergencias durante la pandemia por covid-19. Acta Med Costarric. 2021;63(3):169-77. https://doi.org/10.51481/amc.v63i3.1138
25. Arrué-Hernández KA, Soto-Cáceres VA, Fernández-Mogollón JL. Características del registro y codificación diagnóstica de los pacientes hospitalizados en un hospital del seguro social de Chiclayo. Rev Cuerpo Méd HNAAA. 2019;12(1):13-18.

https://doi.org/10.22516/25007440.1153

Original article

Real-Life Colonoscopy Preparation

Carlos Arturo Rojas-Rodríguez,[1*] Jorge Salazar,[1] Nelson Rojas,[2] Carlos Andrés Mejía,[2] Michell González-Hurtado,[3] Ana Fernanda Mejía,[4] Eliana Manzi,[5] Leidy Johanna Hurtado-Bermúdez,[4,6] Wanda Zamary Colorado-Vásquez,[7] Natalia Mena-Cabrera.[7]

OPEN ACCESS

Citation:
Rojas-Rodríguez CA, Salazar J, Rojas N, Mejía CA, González-Hurtado M, Mejía AF, Manzi E, Hurtado-Bermúdez LJ, Colorado-Vásquez WZ, Mena-Cabrera N. Real-Life Colonoscopy Preparation. Revista. colomb. Gastroenterol. 2024;39(3):274-280.
https://doi.org/10.22516/25007440.1153

[1] Gastroenterologist, Endoscopy and Gastroenterology Service, Fundación Valle del Lili. Cali, Colombia.
[2] Physician, School of Health Sciences, Universidad ICESI. Internal Medicine Resident, Department of Internal Medicine, Fundación Valle del Lili. Cali, Colombia.
[3] Physician, Research Assistant, Clinical Research Center, Fundación Valle del Lili. Cali, Colombia.
[4] Epidemiologist, Department of Public Health and Community Medicine, School of Health Sciences, Universidad ICESI. Cali, Colombia.
[5] Genetic Biologist, Specialist in Applied Statistics. Research Specialist, Clinical Research Center, Fundación Valle del Lili. Cali, Colombia.
[6] Statistician, Master's in Epidemiology. Research Specialist, Clinical Research Center, Fundación Valle del Lili. Cali, Colombia.
[7] Medical Student, School of Health Sciences, Universidad ICESI. Cali, Colombia.

***Correspondence:** Carlos Arturo Rojas-Rodríguez.
crojo16@yahoo.com

Received: 20/11/2023
Accepted: 08/04/2024

Abstract

Introduction: The quality of a colonoscopy is a key factor in clinical outcomes and largely depends on the bowel cleanliness achieved through proper preparation. The type of agent, adherence, and tolerability are factors that can influence the quality of bowel preparation and, consequently, the results of the procedure. This study aims to evaluate the factors that determine the choice of preparation agent and its impact on the quality of colonoscopy. **Methodology:** A cross-sectional observational study was conducted with a sample of 530 patients. Agents evaluated included polyethylene glycol (PEG), sodium picosulfate, and sodium-potassium-magnesium sulfate (Na-K-Mg sulfate), with their continuous and split-dose regimens, depending on the case. The reasons for selection and tolerability were assessed through a survey. Bowel cleanliness was determined by the endoscopist using the Boston scale. **Results:** The average age was 52.7 years (±13.4), with 60% being women. The most selected agent was PEG (81.9%) in the full-dose regimen (74.5%). The main determining factor was the availability of the drug, at 42.6%. Unwanted symptoms were reported in 62.6% of patients, however, 99.4% achieved adequate preparation (Boston ≥6). **Conclusion:** The primary factor related to the selection of the bowel preparation agent is availability. Objective tolerability does not significantly affect the quality of bowel cleanliness or the success of the procedure.

Keywords

Colonoscopy, Bowel preparation, Polyethylene Glycol, Sodium Picosulfate, Sodium-Potassium-Magnesium Sulfate.

INTRODUCTION

Colonoscopy is a key diagnostic and therapeutic procedure in medical practice, particularly for the prevention of colorectal cancer. Its use as a screening strategy and intervention for premalignant lesions has resulted in a 52% reduction in incidence and a 62% decrease in mortality associated with this neoplasm[(1)]. The success of this procedure, especially for screening purposes, relies on achieving proper visualization of the mucosa, which, in addition to the operator's expertise, requires a clean bowel without visual barriers during evaluation.

The type of agent used, patient adherence, and its tolerability are factors that determine the quality of the colonoscopy. A procedure is considered adequate with an adenoma detection rate (ADR) above 25% in individuals over 50 years of

© 2024 Asociación Colombiana de Gastroenterología

age, a global cecal intubation rate (CIR) over 90% and above 95% in screening procedures, a withdrawal time of six minutes or more, and a Boston scale score of six or higher[2]. In the United States and Western Europe, it is estimated that between 25% and 40% of colonoscopies have inadequate preparation, leading to early repeat procedures, which presents a challenge for both physicians and patients[3,4].

In our region, several agents are available for bowel preparation, each with different mechanisms of action. The most commonly used are polyethylene glycol (PEG), sodium picosulfate, and Na-K-Mg sulfate. PEG and Na-K-Mg sulfate are considered osmotic laxatives as they increase luminal water and, consequently, hydrostatic pressure, stimulating peristalsis. In contrast, stimulant or contact laxatives, like sodium picosulfate, promote intestinal motility by activating the enteric nervous system. According to the literature, the main factors influencing the choice of agent include tolerance, the volume to be ingested, taste, patient comorbidities, and the occurrence of adverse effects. The most common side effects are nausea, vomiting, sleep disturbances, abdominal distension, and electrolyte and water imbalances[5-8].

PEG passes through the intestines without net absorption or secretion, avoiding significant fluid and electrolyte shifts[3,9]. It is considered safe, even in patients at risk for electrolyte imbalances, particularly those with chronic liver disease, kidney failure, or heart failure, making it the most commonly used agent[9]. Its main drawbacks are poor palatability and the need to dissolve it in a large volume of water (four liters in the traditional regimen). The primary adverse effects are pain, abdominal distension, nausea, vomiting, headache, and sleep disturbances, which may occur in up to 80% of patients, leading 20% of them to fail to complete the preparation regimen[10-15].

Sodium picosulfate and Na-K-Mg sulfate have the advantage of better taste and a lower volume requirement for preparation[16]. However, both can cause electrolyte imbalances and dehydration, so they are not recommended for patients with liver disease, heart disease, or chronic kidney disease[15,17].

In addition to the agent-specific factors, the dosing regimen during preparation also affects its tolerability. The preparation can be administered as a continuous dose, where the total dose is taken the night before or on the day of the procedure, or as a split dose, where half of the preparation is taken the night before and the remaining half on the day of the procedure. While PEG and sodium picosulfate can be administered in either regimen, Na-K-Mg sulfate is only given as a continuous dose. The split-dose regimen is generally better tolerated and is the most recommended for elective procedures. In terms of choosing the preparation, aside from the previously mentioned factors, there may be other reasons that influence the choice[16,18,19].

The present study aims to describe the factors determining the choice of an agent for bowel preparation, its tolerability, and its impact on the quality of bowel cleansing.

METHODOLOGY

Study Design and Data Collection

An analytical cross-sectional observational study was conducted. The sample size was calculated based on an estimated prevalence of 80%, with a 5% margin of error, a significance level of 80%, and an anticipated dropout rate of 10%, resulting in a total of 530 patients. These patients were selected through non-random convenience sampling from individuals scheduled for elective outpatient colonoscopy at Clínica Fundación Valle del Lili in Cali, Colombia, between May and December 2022. The standard bowel preparation agent used in the institutional protocol was PEG due to its safety profile. Sodium picosulfate or Na-K-Mg sulfate were used when recommended by the treating physician when requesting the procedure. Institutional protocols exist for both of these agents as well. At the time of scheduling and according to the procedure's timing, patients were presented with and sent the preparation options, including the corresponding protocols: continuous dosing if the procedure was scheduled for the morning and split dosing if scheduled for the afternoon.

Patients aged 18 and older who were identified as suitable for the study (by the treating gastroenterologist at the time of the procedure request) were included. They were free to choose the preparation agent, considering the physician's recommendation, previous experiences, agent availability, recommendations from other sources, or cost. Patients with specific contraindications to any of the agents under evaluation were excluded.

Data Collection

Information was gathered from the medical record, the official procedure report, and a self-administered survey evaluating factors associated with the selection and tolerability of the bowel preparation agent. Sociodemographic and clinical variables were included.

Procedure

The three bowel preparations evaluated and their respective regimens were 4L PEG in continuous and split dosing, sodium picosulfate in continuous and split dosing, and sodium sulfate in continuous dosing. Quality criteria were defined as a Boston score of six or higher and a cecal intubation rate above 90%.

Statistical Analysis

The data recorded in the database were processed using the statistical software Stata 16. Descriptive statistical analysis for categorical variables was conducted using absolute and relative frequencies, and for quantitative variables, through the calculation of means and standard deviations or medians and interquartile ranges, depending on the distribution of variables as determined by the Kolmogorov-Smirnov test for normality. Subsequently, a bivariate analysis was performed, where quantitative variables were compared using the Kruskal-Wallis test, and categorical variables were compared using the chi-square test or *F*-test.

Ethical Considerations

This study was approved by the Ethics Committee of Clínica Fundación Valle del Lili in Cali, Colombia, adhering to the ethical guidelines outlined in the Declaration of Helsinki. All patients signed informed consent forms. Privacy and confidentiality of sensitive patient information were guaranteed.

RESULTS

In the evaluated population, the average age was 52.7 years (± 13.4), and 60% of the participants were women. A history of abdominal surgery and hypertension were the main comorbidities within the population. The four most common indications for colonoscopy were abdominal pain, screening, diarrhea, and lower gastrointestinal bleeding (**Table 1**).

The most commonly used bowel preparation agent was PEG (81.9%). Neither price nor prior experiences were significant factors in the selection of the bowel preparation agent ($p > 0.05$). The availability of the preparation (42.7%) and the recommendation of the treating physician (36.8%) were the main factors considered by the patients. However, statistically significant differences were observed only in the availability of the agent as a selection factor ($p < 0.05$) (**Table 2**).

Tolerability of the bowel preparations was measured in two ways: subjectively and objectively. In the subjective evaluation (classified as poor, bad, fair, and good), 45.1% of patients reported it as good, and 37.7% as fair. The agent with the highest subjective tolerability was sodium picosulfate, with 75.3% in a single dose, while PEG had the lowest tolerability, with 38.7% in the full-dose regimen, with statistically significant differences ($p < 0.05$). Meanwhile, objective tolerability, defined as having completed the full dose of the preparation agent, was 91.5% overall, with sodium sulfate showing the highest tolerability (100%) (**Table 3**).

Table 1. Demographic and Clinical Characteristics of the Population

Variable	n = 530 (%)
Demographic Characteristics	
- Female sex	318 (60.0)
- Age in years, mean (SD)	52.7 (13.4)
Clinical Characteristics	
- Body Mass Index	
- Underweight	8 (1.5)
- Normal Weight	250 (47.2)
- Overweight	216 (40.7)
- Obesity	56 (10.6)
Pathological History	
- Diabetes	27 (5.1)
- Constipation	16 (3.0)
- Abdominal/Gastrointestinal surgery	179 (33.7)
- Coronary heart disease	5 (0.9)
- Hypertension	105 (19.8)
- Kidney disease	9 (1.7)
- Liver disease	24 (4.5)
- Transplant	1 (0.2)
Indication for Procedure – Patient's Clinical Conditions	
- Abdominal pain	258 (48.7)
Lower gastrointestinal bleeding	45 (8.5)
Diarrhea	49 (9.3)
Colitis	9 (1.7)
Transplant protocol	10 (1.9)
Screening	102 (19.3)
Positive occult blood test	11 (2.1)
Suspected mass	1 (0.19)
Polyps	25 (4.7)
Anemia	14 (2.6)
Primary tumor	3 (0.6)
Abnormal weight loss	17 (3.2)
- History of colorectal cancer	27 (5.1)

SD: standard deviation. Author's own research.

Table 2. Reasons for Selecting the Preparation

Characteristics	Bowel Preparation			*p*-Value
	PEG (n = 434)	Sodium Picosulfate (n = 84)	Sodium Sulfate (n = 12)	
Reasons for Choosing Preparation				
Price				
Yes	27 (6.2)	11 (13.1)	1 (8.3)	0.086‡
Previous Experiences				
Yes	50 (11.5)	16 (19.1)	2 (16.7)	0.158‡
Availability of the Agent				
Yes	198 (45.7)	26 (30.9)	2 (16.7)	**0.008**‡
Treating Physician's Recommendation				
Yes	152 (35.0)	36 (42.9)	7 (58.3)	0.116‡
Recommendations from Other Sources				
Yes	72 (16.6)	22 (26.2)	2 (16.7)	0.111‡

‡ Fisher's F exact test. Author's own research.

The quality of bowel cleansing was assessed using the Boston scale and the cecal intubation rate. A total of 99.4% of patients achieved adequate bowel preparation, defined as a Boston score ≥6, and 98.3% achieved cecal intubation, with the lowest rate for PEG at 98.2% and the highest for sodium sulfate at 100%. No significant differences were observed between the agents studied.

Regarding adverse effects, the most frequent were nausea, bad taste, and headache (34.0%, 31.9%, and 22.7%, respectively). Statistically significant differences were found in relation to the type of preparation and abdominal pain and bad taste ($p < 0.05$).

The study identified an overall polyp detection rate (PDR) of 18%, without adjusting for age or indication for the procedure. When adjusted for patients over 50 years old undergoing their first screening procedure, the PDR was 20%, with an adenoma detection rate (ADR) of 15% (**Table 4**).

DISCUSSION

There is no prior national literature that identifies the reasons patients choose between the different bowel preparation options available on the market. In our population, availabi-

Table 3. Subjective and Objective Tolerability According to Type and Regimen of Bowel Preparation

Characteristics	Bowel Preparation					*p*-Value
	PEG (n = 434)		Sodium Picosulfate (n = 84)		Sodium Sulfate (n = 12)	
	4-Liter Regimen (n = 398)	Split-Dose Regimen (n = 36)	Single-Dose Regimen (n = 73)	Two-Dose Regimen (n = 11)	Single-Dose Regimen (n = 12)	
Tolerability						
- Subjective Tolerability			n (%)			
Poor (extremely difficult)	37 (9.3)	1 (2.8)	2 (2.7)	0 (0)	0 (0)	**0.00**
Bad (difficult)	41 (10.3)	1 (2.8)	6 (8.2)	1 (9.1)	2 (16.7)	
Fair (partially difficult)	166 (41.7)	18 (50.0)	10 (13.7)	3 (27.3)	3 (25.0)	
Good (very easy)	154 (38.7)	16 (44.4)	55 (75.3)	7 (63.6)	7 (58.3)	
- Total Tolerability			n (%)			
Complete full regimen	364 (91.5)	33 (91.7)	67 (91.8)	9 (81.8)	12 (100.0)	0.625
Incomplete regimen	34 (8.5)	3 (8.3)	6 (8.2)	2 (18.2)	0 (0)	

Author's own research.

Table 4. Boston Scale, Cecal Intubation, and Adverse Effects

Characteristics	Bowel Preparation			*p*-Value
	PEG (n = 434)	Sodium Picosulfate (n = 84)	Sodium Sulfate (n = 12)	
Procedure Intervention				
Cecal Intubation		**n (%)**		
Yes	426 (98.2)	83 (98.8)	12 (100.0)	0.822‡
Colon Cleansing				
Total Boston Scale Score				
≤5 ≥6	2 (0.5) 432 (99.5)	1 (1.2) 83 (98.8)	0 (0) 12 (100.0)	0.452‡
Adverse Effects				
Nausea		**n (%)**		
Yes	156 (35.9)	20 (23.8)	4 (33.3)	**0.089**‡
Abdominal Distention		**n (%)**		
Yes	88 (20.3)	12 (14.5)	4 (33.3)	0.321‡
Headache				
Yes	101 (23.3)	19 (22.9)	0 (0.00)	0.165‡
Abdominal Pain		**n (%)**		
Yes	55 (12.7)	12 (14.5)	5 (41.7)	**0.015**‡
Bad Taste		**n (%)**		
Yes	154 (35.5)	9 (10.8)	6 (50.0)	**0.00**‡
Allergy to the Agent		**n (%)**		
Yes	1 (0.2)	0 (0)	0 (0)	> 0.9‡

‡ Fisher's F exact test. Author's own research.

lity and physician recommendation were the primary factors influencing that choice. Although price was considered by only 7.4% of patients, PEG, the most affordable agent on the market, was by far the most commonly used.

In terms of tolerability, national literature reports similar results to ours, with a high frequency of adverse effects, but without affecting adherence to the bowel preparation, as the majority of patients were able to complete it.

Regarding the quality of bowel cleansing, our results align with previous studies that indicate no significant differences in the effectiveness of bowel cleansing among the different agents available. Notably, only two procedures had a Boston score of 0 (zero) in one or more colonic segments, leading to the recommendation to repeat the procedure within one year.

Although not the primary objective of the study, and considering that only 20% of the procedures performed were for screening and that 33.7% of the patients had a history of prior abdominal surgery, the polyp detection rate identified falls within the range described in national literature (14%-17%)[20,21]. However, it is noteworthy that the polyp detection rate in various national studies differs from that reported internationally, highlighting the need to delve deeper into the local epidemiology to establish the

prevalence of polyps in Colombia and to determine optimal quality indicators.

CONCLUSIONS

The study results suggest that the primary factor related to the choice of bowel preparation is the availability of the agent. The findings indicate that there are no significant differences in objective tolerability or the quality of the preparation among the various substances. Therefore, it is essential for healthcare personnel to become familiar with the different available agents to provide appropriate recommendations.

Acknowledgments

GEHCO Group, Fundación Valle Del Lili. Isabella Calderón Mejía, Daniela Botero Jaramillo.

Funding Sources

This research did not receive any specific grants from public, commercial, or non-profit funding agencies.

Conflict of Interest

The authors declare no conflicts of interest.

REFERENCES

1. Zhang J, Chen G, Li Z, Zhang P, Li X, Gan D, et al. Colonoscopic screening is associated with reduced Colorectal Cancer incidence and mortality: a systematic review and meta-analysis. J Cancer. 2020;11(20):5953-70. https://doi.org/10.7150/jca.46661
2. Rex DK. Key quality indicators in colonoscopy. Gastroenterol Rep (Oxf). 2023;11:goad009. https://doi.org/10.1093/gastro/goad009
3. Sharara AI, Abou Mrad RR. The modern bowel preparation in colonoscopy. Gastroenterol Clin North Am. 2013;42(3):577-98. https://doi.org/10.1016/j.gtc.2013.05.010
4. Altamirano Castañeda ML, Hernández Mondragón ÓV, Blanco Velasco G, Blancas Valencia JM. Comparación de 2 tipos de preparación intestinal para la realización de colonoscopia en un hospital de tercer nivel. Endoscopia. 2015;27(4):168-74. https://doi.org/10.1016/j.endomx.2015.12.004
5. Park SS, Sinn DH, Kim YH, Lim YJ, Sun Y, Lee JH, et al. Efficacy and Tolerability of Split-Dose Magnesium Citrate: Low-Volume (2 Liters) Polyethylene Glycol vs. Single- or Split-Dose Polyethylene Glycol Bowel Preparation for Morning Colonoscopy. Am J Gastroenterol. 2010;105(6):1319-26. https://doi.org/10.1038/ajg.2010.79
6. Carvajal Patiño GD, Aponte Marín DM, Ibáñez Pinilla M, Prieto-Ortíz RG, Castañeda-Orjuela C, González Salazar CA, et al. Eficacia y seguridad de 3 esquemas para la preparación del colon para colonoscopia (Polietilenglicol (PEG) 4 litros (dosis única) vs PEG 4 litros dividido (2 L+2 L) vs PEG 2 litros dividido volumen bajo (1 L + 1 L): ensayo clínico controlado aleatorizado. Rev Colomb Gastroenterol. 2019;34(2):144-51. https://doi.org/10.22516/25007440.393
7. Cheng J, Tao K, Shuai X, Gao J. Sodium phosphate versus polyethylene glycol for colonoscopy bowel preparation: an updated meta-analysis of randomized controlled trials. Surg Endosc. 2016;30(9):4033-41. https://doi.org/10.1007/s00464-015-4716-6
8. Adamcewicz M, Bearelly D, Porat G, Friedenberg FK. Mechanism of action and toxicities of purgatives used for colonoscopy preparation. Expert Opin Drug Metab Toxicol. 2011;7(1):89-101. https://doi.org/10.1517/17425255.2011.542411
9. Cohen LB. Advances in Bowel Preparation for Colonoscopy. Gastrointest Endosc Clin N Am. 2015;25(2):183-97. https://doi.org/10.1016/j.giec.2014.11.003
10. Lai EJ, Calderwood AH, Doros G, Fix OK, Jacobson BC. The Boston bowel preparation scale: a valid and reliable instrument for colonoscopy-oriented research. Gastrointest Endosc. 2009;69(3):620-5. https://doi.org/10.1016/j.gie.2008.05.057
11. Forero E, Cardona H, Reyes G, Abello H, Rosas M, Sánchez C. Preparación intestinal para colonoscopia; comparación entre polietilenglicol y manitol: Estudio de costo efectividad, doble ciego aleatorizado. Rev Colomb Gastroenterol. 2005;20(4):60-71.
12. Radaelli F, Meucci G, Imperiali G, Spinzi G, Strocchi E, Terruzzi V. High-Dose Senna Compared with Conventional PEG-ES Lavage as Bowel Preparation for Elective Colonoscopy: A Prospective, Randomized, Investigator-Blinded Trial. Am J Gastroenterol. 2005;100(12):2674-80. https://doi.org/10.1111/j.1572-0241.2005.00335.x
13. Juluri R, Eckert G, Imperiale TF. Meta-analysis: randomized controlled trials of 4-L polyethylene glycol and sodium phosphate solution as bowel preparation for colonoscopy. Aliment Pharmacol Ther. 2010;32(2):171-81. https://doi.org/10.1111/j.1365-2036.2010.04326.x

14. Aoun E, Abdul-Baki H, Azar C, Mourad F, Barada K, Berro Z, et al. A randomized single-blind trial of split-dose PEG-electrolyte solution without dietary restriction compared with whole dose PEG-electrolyte solution with dietary restriction for colonoscopy preparation. Gastrointest Endosc. 2005;62(2):213-8. https://doi.org/10.1016/s0016-5107(05)00371-8
15. Murcio-Pérez E, Téllez-Ávila. F. Opciones de preparación para colonoscopia. Endoscopia. 2012;24(1):23-31.
16. Roldán Molina LF, Roldán Delfino LM, León Ramírez SM, Nuñez Cabarcas EE, Pérez Useche HM, Restrepo Peláez AJ, et al. Efectividad y tolerabilidad de tres tipos de productos de preparación para colonoscopia. Rev Colomb Gastroenterol. 2021;36(3):334-40. https://doi.org/10.22516/25007440.679
17. Quaresma AB, Briancini G, Chiesa T, Monteiro SO, Mergener RA. Intestinal preparations for colonoscopy. Comparative study: mannitol, picosulphate and macrogol. J Coloproctol (Rio J). 2018;38(2):105-10. https://doi.org/10.1016/j.jcol.2017.12.001
18. López S, Vargas C, López C. Eficacia y tolerabilidad de la reducción del volumen de polietilenglicol para la preparación para colonoscopia. Rev Med Chil. 2019;147(8):977-982. https://doi.org/10.4067/S0034-98872019000800977
19. Johnson DA, Barkun AN, Cohen LB, Dominitz JA, Kaltenbach T, Martel M, et al. Optimizing adequacy of bowel cleansing for colonoscopy: recommendations from the US multi-society task force on colorectal cancer. Gastroenterology. 2014;147(4):903-24. https://doi.org/10.1053/j.gastro.2014.07.002
20. Barreto Noratto CP, Limas Solano LM, González CA. Calidad en colonoscopía: experiencia en un centro de endoscopía de Boyacá, Colombia. Acta Gastroenterol Latinoam. 2023;53(1):68-75.
21. Gómez Rodríguez AMPKT. Caracterización clínica y endoscópica de los pacientes llevados a Colonoscopia en el Hospital Universitario Samaritana 2017-2018. Bogotá: Universidad del Rosario; 2020.

https://doi.org/10.22516/25007440.1051

Original article

Morbidity and Mortality in COVID-19 Patients With and Without Gastrointestinal Symptoms

Margarita Rey-R.,[1] Gustavo Reyes,[1] Belén Mendoza-de Molano,[1] Cathalina Vergara-Cabra,[2] Erika D. Pérez-Riveros,[3] Juan Carlos Robayo,[1] Mariana Vásquez-Roldán,[4*] Fernando Sierra-Arango.[5]

OPEN ACCESS

Citation:
Rey-R. M, Reyes G, Mendoza-de Molano B, Vergara C, Pérez-Riveros E, Robayo JC, Vásquez-Roldán M, Sierra-Arango F. Morbidity and Mortality in COVID-19 Patients With and Without Gastrointestinal Symptoms. Revista. colomb. Gastroenterol. 2024;39(3):281-286. https://doi.org/10.22516/25007440.1051

[1] Internist, Gastroenterologist, Department of Gastroenterology and Digestive Endoscopy, Fundación Santa Fe de Bogotá. Bogotá, Colombia.
[2] Department of Gastroenterology and Digestive Endoscopy, Fundación Santa Fe de Bogotá. Bogotá, Colombia.
[3] Physician. Research Assistant, Fundación Santa Fe de Bogotá. Bogotá, Colombia.
[4] Rural-Practicum Researcher, Sub-Directorate of Clinical and Epidemiological Studies, Department of Gastroenterology and Digestive Endoscopy, Fundación Santa Fe de Bogotá. Bogotá, Colombia.
[5] Internist, Gastroenterologist, MSc. in Epidemiology, Department of Gastroenterology and Digestive Endoscopy, Fundación Santa Fe de Bogotá. Bogotá, Colombia.

***Correspondence:** Mariana Vásquez-Roldán.
marivasquezr@gmail.com

Received: 13/06/2023
Accepted: 07/06/2024

Abstract

Objective: Severe Acute Respiratory Syndrome Coronavirus 2 (SARS-CoV-2) causes a wide range of symptoms, including gastrointestinal manifestations such as nausea, vomiting, diarrhea, and abdominal pain. This study aimed to evaluate whether the presence or absence of these gastrointestinal symptoms could be associated with more severe disease progression, defined as death, the need for intensive care unit (ICU) management, mechanical ventilation, or bacterial coinfection. **Patients and Methods:** An analytical observational cohort study was conducted with confirmed COVID-19 patients with gastrointestinal symptoms and a comparison group without gastrointestinal symptoms. Patients included were over 18 years old, presented with symptoms suggestive of COVID-19, and had the diagnosis confirmed by a polymerase chain reaction test. **Results:** A total of 414 patients who met the selection criteria were analyzed, and it was found that mortality was influenced only by age, while mechanical ventilation and the need for ICU management were related to liver function profile. However, no difference in severity was found between patients with gastrointestinal symptoms and those without. **Conclusions:** Gastrointestinal symptoms alone do not represent a risk for the progression of SARS-CoV-2 disease, however, levels of alanine aminotransferase (ALT), aspartate aminotransferase (AST), and direct bilirubin (DB) should be included in the initial assessment of these patients, as they provide prognostic value according to the results of our study.

Keywords

COVID-19, Clinical Symptoms, Intensive Care Unit, Mechanical Ventilation, Mortality, Bacterial Infections.

INTRODUCTION

The number of severe acute respiratory syndrome coronavirus 2 (SARS-CoV-2) cases during the COVID-19 pandemic has exponentially increased, with over 260,522,651 confirmed cases worldwide and 5,187,665 reported deaths, according to the World Health Organization (WHO)[1,2]. This infection typically presents with a wide range of symptoms, from asymptomatic individuals to severe cases that primarily affect the respiratory system, as well as other systems such as the gastrointestinal system[3]. Gastrointestinal symptoms include diarrhea (3%–34%), nausea (1%–17%), vomiting (1%–4%), abdominal pain (2%–5%), gastrointestinal bleeding (0%–13%), and even liver failure[4-6].

Several studies propose a link between the presence of angiotensin-converting enzyme 2 (ACE-2) receptors and gastrointestinal symptoms, as these receptors are present throughout the gastrointestinal epithelium and serve as an

entry point for SARS-CoV-2. This receptor also influences the expression of neutral amino acid transporters in the intestine, altering the composition of the microbiota and leading to inflammation of the mucosa[7,8]. While this receptor is highly expressed in type II alveolar cells in the lungs, which explains the primary clinical manifestations, it is also found in high concentrations in the gastrointestinal tract (keratinocytes of the esophagus, epithelial cells of the stomach, intestinal cells, and colonocytes). Recent studies have shown that SARS-CoV-2 can directly bind to cholangiocytes via this receptor, causing liver damage, which explains its role in liver function test abnormalities during infection[9,10].

Some studies suggest that patients with gastrointestinal symptoms may experience worse clinical outcomes, with evidence that COVID-19 patients with gastrointestinal symptoms are up to seven times more likely to progress to acute respiratory distress syndrome and liver failure. Additionally, up to 50% of those who seek medical care may present with elevated liver enzymes (alanine aminotransferase [ALT], aspartate aminotransferase [AST], γ-glucuronosyltransferase [GGT]) and mild bilirubin elevation during the course of the disease[11]. This is significant because the true impact of gastrointestinal symptoms on the natural history of COVID-19 remains unclear, but their presence has been directly associated with a poorer prognosis[9,10,12].

MATERIALS AND METHODS

An observational, analytical cohort study was conducted, comparing a study group of COVID-19-positive patients with gastrointestinal symptoms and a comparator group without gastrointestinal symptoms. This study was approved by the Corporate Ethics Committee of Fundación Santa Fe de Bogotá and adheres to the principles of the Declaration of Helsinki[13] and Resolution 008430 of 1993 of the Republic of Colombia's Ministry of Health for observational studies[14].

Study Population

Patients over 18 years of age who presented to the emergency department with symptoms suggestive of COVID-19 and were confirmed with a polymerase chain reaction (PCR) test were included, regardless of whether they were managed as outpatients or hospitalized, and whether or not they had gastrointestinal symptoms at the time of admission (abdominal pain, nausea, vomiting, diarrhea, or elevated liver function tests). Initial liver function measurements were also considered for those patients who required hospitalization, with most measurements taken before admission to the intensive care unit (ICU).

Patients who did not have a confirmatory test for the virus or were diagnosed with a test other than PCR were excluded, as well as those who initially consulted through telemedicine or home care.

Data Systematization and Analysis

This ambispective cohort study collected data retrospectively from the admission of the first positive patient reported at Fundación Santa Fe de Bogotá on March 6, 2020, and prospectively until September 2021. The information was extracted from the medical records of patients admitted through the emergency department who were confirmed to have COVID-19 via PCR testing, regardless of the severity of the disease or whether hospitalization was required. The data collection included sociodemographic variables, relevant personal medical history (including a history of liver disease), source or exposure to the infection, presence of nausea/vomiting, diarrhea, abdominal pain, and clinical outcomes, considering mortality, ICU stay, bacterial coinfection, and the need for mechanical ventilation.

Statistical Analysis

Sample size calculation was performed using OpenEpi software[15], estimating that the percentage of COVID-19 patients without gastrointestinal symptoms (unexposed) would be 8.14%, while the percentage with gastrointestinal symptoms (exposed) would be 22.97%. A standard deviation of 0.5, a significance level of 5%, and a power of 80% were used in the calculation. A 10% loss rate was factored in, requiring an initial inclusion of 65 exposed patients and 194 unexposed patients. However, due to the patient volume, a total sample size of 414 patients was achieved, of whom 105 had gastrointestinal symptoms.

For the statistical analysis, categorical variables were described using frequency and percentages, and continuous variables were presented with frequency, mean, median, interquartile range, and the Shapiro-Wilk test to assess normal distribution. Bivariate analysis was conducted to determine if the presence of gastrointestinal symptoms was a risk factor for worse outcomes using the chi-square test and Fisher's exact test. Outcomes with a p-value <0.2 were included in the multivariate analysis, using a multivariate logistic regression model to identify independent predictors. The multivariate analysis was conducted using a multiple logistic regression model. Factors that significantly explained the outcome were those with a p-value <0.05, along with their odds ratio (OR) and 95% confidence interval (CI). Analyses were performed using Real Statistics software, version 7.9, August 2021.

RESULTS

A total of 414 patients who met the selection criteria were analyzed (178 women and 236 men), aged between 18 and 94 years. Of these, 105 patients presented with at least one gastrointestinal symptom at the time of admission, such as diarrhea, nausea, vomiting, or abdominal pain, and had outcomes including bacterial co-infection (12/402), need for mechanical ventilation (102/312), ICU admission (157/257), or death (19/395) (**Table 1**).

Table 1. Demographic Description of the Study Population (n = 414)

Variable		%	n
Sex	Female	42.99	178
	Male	57.24	236
Mechanical ventilation		24.63	102
ICU		37.92	157
Mortality		4.58	19
Bacterial co-infection		2.89	12
Gastrointestinal symptoms	Diarrhea	11.83	49
	Vomiting	2.65	11
	Nausea	6.28	26
	Abdominal pain	8.21	34
		Average	SD
Age	n =414	54.51	17.97282532
BMI (kg/m^2)	n = 414	26.72	4.605037009
ALT (U/L)	n = 298	123.44	846.6107765
AST (U/L)	n = 298	82.19	343.6445574
Direct bilirubin (mg/dL)	n = 263	0.22	0.294993885
ALP (U/L)	n = 104	117.21	78.326
GGT (U/mL)	n = 7	159	36.42043547

ALT: alanine aminotransferase; AST: aspartate aminotransferase; SD: standard deviation; ALP: alkaline phosphatase; GGT: γ-glutamyltransferase; BMI: body mass index; ICU: intensive care unit. Author's own research.

Among patients with COVID-19 who required mechanical ventilation as part of their treatment, the factors associated with this outcome were age (mean: 63.56 [33-87 years]; p = 0.025), BMI (27.80 [18.50-44.30 kg/m^2]; p = 0.001), ALT (252.09 [14.00-171.13 U/L]; p = 0.007), alkaline phosphatase (ALP) (71.37 [0.0-372.0]; p = 0.000), and direct bilirubin (DB) (0.23 [0.003-1.08]; p = 0.003). Regarding variables that could explain ICU admission, BMI (27.62 [18.40-46.7]; p = 0.015), ALT (186.66 [0.00-17,113]; p = 0.001), ALP (54.33 [372-0]; p = 0.000), and DB (0.23 [0.00-1.39]; p = 0.028) were found to be related to this outcome. As for the risk of concomitant bacterial co-infection with SARS-CoV-2, ALP (25.08 [0.00-156.00]; p = 0.048) and DB (0.30 [0.00-1.08]; p = 0.006) were associated with this outcome. Regarding the risk of death from COVID-19, the only factor found to be related was age (74.84 [60-94]; p = 0.002) (**Table 2**).

Regarding specific gastrointestinal symptoms such as nausea/vomiting, diarrhea, and abdominal pain, no association was found between their presence and severe disease outcomes, such as the need for ICU admission (p = 0.823), mechanical ventilation (p = 0.239), bacterial co-infection (p = 0.813), or death (p = 0.284). In other words, there were no individual factors explaining these proposed outcomes. Likewise, other measured variables, such as GGT levels, did not show any relationship with the outcomes.

When comparing patients with gastrointestinal symptoms to those without, no differences were found in severity outcomes, such as the need for ICU admission (p = 0.823), mechanical ventilation (p = 0.239), bacterial co-infection (p = 0.813), or death (p = 0.284). Thus, no individual factors could explain these outcomes (**Table 2**). Similarly, other variables, such as GGT levels, were not associated with the outcomes.

DISCUSSION

The multisystemic involvement caused by COVID-19 is a critical factor in the diagnosis, treatment, and overall clinical management of patients. Among other areas, the literature has focused on investigating whether gastrointestinal symptoms are associated with an increased risk of developing severe or critical illness and acute respiratory failure[16].

While the results of publications on this topic are inconclusive, some authors have indicated that there is no statistically significant difference in severe cases presenting with gastrointestinal symptoms compared to those without, whereas others, such as Wang and colleagues, found that the proportion of gastrointestinal symptoms was significantly higher in patients admitted to the ICU due to coronavirus infection[17]. Others have reported a link between the presence of gastrointestinal bleeding and abdominal pain with more severely ill patients[18], while Cai and colleagues demonstrated that liver injury occurred more frequently in patients with severe disease than in those with milder forms, with an incidence of up to 78% in patients who died from the virus[19]. However, none of these stud-

Table 2. Multivariable Logistic Regression Evaluating the Relationship Between Gastrointestinal Symptoms, Liver Function, and Outcomes

	Coeff b	*p*-Value	exp(b)	Lower	Upper
Logistic regression for mechanical ventilation					
- Intercept	-5.69	0.000	0.00		
- Age	0.04	0.000	1.04	1.02	1.06
- BMI (kg/m^2)	0.06	0.039	1.06	1.00	1.12
- ALT (U/L)	0.01	0.007	1.01	1.00	1.02
- ALP (U/L)	0.01	0.000	1.01	1.01	1.02
- Direct bilirubin (mg/dL)	-2.49	0.003	0.08	0.02	0.43
- Indirect bilirubin (mg/dL)	0.49	0.366	1.64	0.56	4.75
- AST (U/L)	0.00	0.317	1.00	0.99	1.00
- GGT (U/mL)	-0.01	0.142	0.99	0.98	1.00
- Gastrointestinal symptoms	-0.37	0.239	0.69	0.37	1.28
Logistic regression for ICU admission					
- Intercept	-6.22	0.000	0.00		
- Age	0.05	0.000	1.06	1.04	1.07
- BMI (kg/m^2)	0.07	0.015	1.07	1.01	1.13
- ALT (U/L)	0.02	0.001	1.02	1.01	1.03
- ALP (U/L)	0.01	0.000	1.01	1.00	1.01
- Direct bilirubin (mg/dL)	-1.70	0.028	0.18	0.04	0.83
- Indirect bilirubin (mg/dL)	0.41	0.444	1.51	0.53	4.30
- AST (U/L)	0.00	0.799	1.00	0.99	1.01
- GGT (U/mL)	0.00	0.569	1.00	0.98	1.01
- Gastrointestinal symptoms	-0.06	0.823	0.94	0.55	1.62
Logistic regression for bacterial co-infection					
- Intercept	-6.72	0.002	0.00		
- ALP (U/L)	-0.01	0.048	0.99	0.98	1.00
- Direct bilirubin (mg/dL)	4.67	0.006	106.35	3.83	2951.62
- Gastrointestinal symptoms	0.16	0.813	1.18	0.30	4.59
- BMI (kg/m^2)	0.07	0.278	1.07	0.94	1.22
- Age	0.03	0.168	1.03	0.99	1.07
- ALT (U/L)	0.00	0.988	1.00	0.99	1.01
- AST (U/L)	0.00	0.929	1.00	0.98	1.02
- GGT (U/mL)	-0.55	0.997	0.58	0.00	1.05
- Indirect bilirubin (mg/dL)	-2.48	0.092	0.08	0.00	1.49
Logistic regression for mortality					
- Intercept	-11.03	0.000	0.00		
- Age	0.10	0.000	1.10	1.05	1.16
- Direct bilirubin (mg/dL)	1.48	0.292	4.38	0.28	68.37
- Indirect bilirubin (mg/dL)	1.33	0.140	3.78	0.65	22.04
- BMI (kg/m^2)	0.05	0.452	1.05	0.93	1.19
- AST (U/L)	0.01	0.172	1.01	1.00	1.02
- GGT (U/mL)	0.01	0.373	1.01	0.99	1.03
- ALP (U/L)	-0.01	0.227	0.99	0.98	1.00
- ALT (U/L)	-0.02	0.085	0.98	0.96	1.00
- Gastrointestinal symptoms	-0.81	0.284	0.44	0.10	1.96

ALT: alanine aminotransferase; AST: aspartate aminotransferase; coeff b: b coefficient; exp(b): odds ratio; ALP: alkaline phosphatase; GGT: γ-glutamyltransferase; BMI: body mass index; ICU: intensive care unit. Author's own research.

ies considered gastrointestinal signs and symptoms as potential prognostic factors for unfavorable outcomes, such as mortality and acute respiratory distress syndrome (ARDS), in patients testing positive for SARS-CoV-2[20]. Another analysis found no significant differences in mortality between the two groups but did indicate that patients with gastrointestinal symptoms had a significant risk of developing ARDS[21].

In this study, none of the gastrointestinal symptoms, such as diarrhea, nausea, vomiting, or abdominal pain, were significantly associated with a specific outcome. However, liver function was related to certain outcomes. ALT was found to be associated with the risk of developing acute respiratory failure requiring mechanical ventilation, as well as the need for ICU admission. Importantly, these measurements were mostly taken before ICU admission, eliminating any confounding factors related to medications and ICU care. Additionally, there was a significant association between ALP and bacterial co-infection, mechanical ventilation, and ICU support requirements. Mortality, on the other hand, was the only outcome that showed no relationship with any gastrointestinal symptoms or liver function indicators. This finding aligns with international literature, where liver damage has been associated with disease progression but not with increased mortality[9,12,19]. Therefore, based on this study, it is recommended to include ALT, AST, and DB levels in the initial assessment of these patients, as they provide valuable prognostic information.

CONCLUSION

It is important to highlight that, when comparing patients with and without gastrointestinal symptoms, no statistically significant relationship was found regarding severe outcomes. However, a potential bias in this study is the inclusion of all patients, with or without gastrointestinal symptoms, as described, and not all had liver function measurements. This could be a limitation in terms of the total sample, although the number of patients with ALT and AST levels is still representative.

REFERENCES

1. World Health Organization. COVID-19 cases | WHO COVID-19 dashboard [Internet]. Datadot [consultado el 30 de noviembre de 2021]. Disponible en: https://covid19.who.int/
2. Johns Hopkins Coronavirus Resource Center. COVID-19 Map - Johns Hopkins Coronavirus Resource Center [Internet]. Johns Hopkins Coronavirus Resource Center [consultado el 30 de noviembre de 2021]. Disponible en: https://coronavirus.jhu.edu/map.html
3. Sierra-Arango F, Vergara-Cabra C, Vásquez-Roldan M, Pérez-Riveros ED. Acute surgical-like abdomen as a gastrointestinal manifestation of COVID-19 infection: a case report in Colombia. BMC Gastroenterol. 2021;21(1):187. https://doi.org/10.1186/s12876-021-01762-0
4. Zhu N, Zhang D, Wang W, Li X, Yang B, Song J, et al. A Novel Coronavirus from Patients with Pneumonia in China, 2019. N Engl J Med. 2020;382(8):727-33. https://doi.org/10.1056/NEJMoa2001017
5. Ministerio de Salud y Protección Social. Así va el aplanamiento de la curva epidemiológica en el país [Internet]. Ministerio de Salud y Protección Social [consultado el 30 de noviembre de 2021]. Disponible en: https://www.minsalud.gov.co/Paginas/Asi-va-el-aplanamiento-de-la-curva-epidemiologica-en-el-pais-.aspx
6. Instituto Nacional de Salud. Coronavirus Colombia [Internet]. Instituto Nacional de Salud [consultado el 30 de noviembre de 2021]. Disponible en: https://www.ins.gov.co/Noticias/paginas/coronavirus.aspx
7. Azwar MK, Kirana F, Kurniawan A, Handayani S, Setiati S. Gastrointestinal Presentation in COVID-19 in Indonesia: A Case Report. Acta Medica Indones. 2020;52(1):63-7.
8. Nobel YR, Phipps M, Zucker J, Lebwohl B, Wang TC, Sobieszczyk ME, et al. Gastrointestinal Symptoms and Coronavirus Disease 2019: A Case-Control Study From the United States. Gastroenterology. 2020;159(1):373-375.e2. https://doi.org/10.1053/j.gastro.2020.04.017
9. Suresh Kumar VC, Mukherjee S, Harne PS, Subedi A, Ganapathy MK, Patthipati VS, et al. Novelty in the gut: a systematic review and meta-analysis of the gastrointestinal manifestations of COVID-19. BMJ Open Gastroenterol. 2020;7(1):e000417. https://doi.org/10.1136/bmjgast-2020-000417
10. Dong Z, Xiang B-J, Jiang M, Sun M, Dai C. The Prevalence of Gastrointestinal Symptoms, Abnormal Liver Function, Digestive System Disease and Liver Disease in COVID-19 Infection: A Systematic Review and Meta-Analysis. J Clin Gastroenterol. 2021;55(1):67-76. https://doi.org/10.1097/MCG.0000000000001424
11. Wong SH, Lui RN, Sung JJ. Covid-19 and the digestive system. J Gastroenterol Hepatol. 2020;35(5):744-8. https://doi.org/10.1111/jgh.15047
12. Mao R, Qiu Y, He JS, Tan JY, Li XH, Liang J, et al. Manifestations and prognosis of gastrointestinal and liver involvement in patients with COVID-19: a systematic review and meta-analysis. Lancet Gastroenterol Hepatol.

2020;5(7):667-678.
https://doi.org/10.1016/S2468-1253(20)30126-6
13. World Medical Association. Declaración de Helsinki de la AMM – Principios éticos para las investigaciones médicas en seres humanos [Internet]. The World Medical Association [consultado el 30 de noviembre de 2021]. Disponible en: https://www.wma.net/es/policies-post/declaracion-de-helsinki-de-la-amm-principios-eticos-para-las-investigaciones-medicas-en-seres-humanos/
14. Ministerio de Salud y Protección Social. Resolución 8430 de 1993, por la cual se establecen las normas científicas, técnicas y administrativas para la investigación en salud [Internet]. Ministerio de Salud y Protección Social [consultado el 30 de noviembre de 2021]. Disponible en: https://www.minsalud.gov.co/sites/rid/Lists/BibliotecaDigital/RIDE/DE/DIJ/RESOLUCION-8430-DE-1993.PDF
15. Jin X, Lian J-S, Hu J-H, Gao J, Zheng L, Zhang Y-M, et al. Epidemiological, clinical and virological characteristics of 74 cases of coronavirus-infected disease 2019 (COVID-19) with gastrointestinal symptoms. Gut. 2020;69(6):1002-1009. https://doi.org/10.1136/gutjnl-2020-320926
16. Tariq R, Saha S, Furqan F, Hassett L, Pardi D, Khanna S. Prevalence and Mortality of COVID-19 Patients With Gastrointestinal Symptoms: A Systematic Review and Meta-analysis. Mayo Clin Proc. 2020;95(8):1632-1648. https://doi.org/10.1016/j.mayocp.2020.06.003
17. Wang D, Hu B, Hu C, Zhu F, Liu X, Zhang J, et al. Clinical Characteristics of 138 Hospitalized Patients With 2019 Novel Coronavirus-Infected Pneumonia in Wuhan, China. JAMA. 2020;323(11):1061-1069. https://doi.org/10.1001/jama.2020.1585
18. Tian Y, Rong L, Nian W, He Y. Review article: gastrointestinal features in COVID-19 and the possibility of faecal transmission. Aliment Pharmacol Ther. 2020;51(9):843–51. https://doi.org/10.1111/apt.15731
19. Cai Q, Huang D, Yu H, Zhu Z, Xia Z, Su Y, et al. COVID-19: Abnormal liver function tests. J Hepatol. 2020;73(3):566-74. https://doi.org/10.1016/j.jhep.2020.04.006
20. Gul F, Lo KB, Peterson J, McCullough PA, Goyal A, Rangaswami J. Meta-analysis of outcomes of patients with COVID-19 infection with versus without gastrointestinal symptoms. Bayl Univ Med Cent Proc. 2020;33(3):366-9. https://doi.org/10.1080/08998280.2020.1771164
21. Wang H, Qiu P, Liu J, Wang F, Zhao Q. The liver injury and gastrointestinal symptoms in patients with Coronavirus Disease 19: A systematic review and meta-analysis. Clin Res Hepatol Gastroenterol. 2020;44(5):653-661. https://doi.org/10.1016/j.clinre.2020.04.012

https://doi.org/10.22516/25007440.1192

Review article

Obesity: The Role of the Gastroenterologist

Valeria Atenea Costa-Barney,[1*] Daniela Cáceres,[2] Alfonso Kerguelen,[3] Jesús Rodríguez,[4] Andrés Rodríguez,[5] Manoel Galvao.[6]

OPEN ACCESS

Citation:
Costa-Barney VA, Cáceres D, Kerguelen A, Rodríguez J, Rodríguez A, Galvao M. Obesity: The Role of the Gastroenterologist. Revista. colomb. Gastroenterol. 2024;39(3):287-295.
https://doi.org/10.22516/25007440.1192

[1] Internist, Gastroenterologist. Bariatric Endoscopist, Clínica Palermo. Bogotá, Colombia.
[2] Internist, Gastroenterologist. Head of the Endoscopy Unit, Hospital Universitario Santa Sofía de Caldas. Manizales, Colombia.
[3] Internist, Endocrinologist, Clínica Marly, Colsanitas. Bogotá, Colombia.
[4] Gastrointestinal Endoscopic Surgeon, Clínica General del Norte, Barranquilla. Endoscopic Surgeon, Clínica Shaio. Bogotá, Colombia.
[5] Endoscopic Surgeon, Hospital de Santa Inés. Cuenca, Ecuador.
[6] Bariatric Endoscopic Surgeon. Orlando Health Weight Loss and Bariatric Surgery Institute. Orlando, USA

***Correspondence:** Valeria Atenea Costa-Barney.
ateneacosta.82@gmail.com

Received: 06/03/2024
Accepted: 24/05/2024

Abstract

Background: Obesity is a disease with high prevalence worldwide, and its incidence is increasing, especially in middle- to high-income countries. Its pathophysiology is related to intestinal hormonal regulation and various gastrointestinal conditions. **Introduction:** The gastroenterologist plays a crucial role in treating this disease through specialized interventions such as bariatric endoscopy, which contribute to weight loss and reduce comorbidities associated with this condition. Additionally, as more patients undergo weight loss procedures, understanding the adjunctive medical treatment in bariatric procedures becomes essential. This review presents the key elements that the gastroenterologist should consider in managing obesity based on the most recent literature. **Conclusions:** There are unmet treatment needs for patients with obesity, among which bariatric endoscopic procedures are a reality when conducted in conjunction with other multidisciplinary approaches.

Keywords

Obesity, Gastric Balloon, Bariatrics, GLP-1 Receptor Agonists, Gastrointestinal Endoscopy.

INTRODUCTION

According to the World Health Organization (WHO), obesity is a chronic disease defined by a body mass index (BMI) ≥30 kg/m^2[1]. It is classified into class I obesity (BMI: 30–34.9 kg/m^2), class II (BMI: 35–39.9 kg/m^2), and class III (BMI: ≥40 kg/m^2). Its prevalence has increased over the last 50 years, and it is currently estimated that over 650 million adults suffer from obesity. As such, it is considered a global public health issue, associated with multiple comorbidities. In addition to the underlying social burden, it generates high costs for individuals, their surroundings, and healthcare systems[2-5]. Triggers for obesity, besides dietary habits, include social, environmental, and physical factors that individuals experience[6].

In Colombia, the National Survey of Nutritional Situation (ENSIN in Spanish) estimated that obesity in adults rose from 13.7% in 2005 to 18.7% in 2015[7]. According to data from the World Obesity Federation, the overall prevalence in 2018 was 21.3%, with a higher rate in women than in men (22.5% vs. 14.4%)[8]. Obesity is associated with the occurrence of cardiovascular diseases as well as others, such as osteoarthritis, fatty liver, depression, cancer, and gastrointestinal conditions, including esophageal, gastric, small intestine, colon, and pancreatic diseases[9].

Lifestyle modification interventions have been the cornerstone of obesity management, showing greater short-term effectiveness with an average weight loss of 3% to 5%. However, in the long term, patients regain up to 80% of the weight lost[10-12]. Consequently, maintaining weight loss is a challenge for both patients and physicians. Clinical practice guidelines recommend a multimodal treatment approach, which includes the use of medications and the performance of medical-surgical procedures, such as bariatric surgery and bariatric endoscopy (BE), to help patients maintain weight loss and achieve treatment goals[11].

Currently, BE procedures, being minimally invasive, are considered to bridge the gap between medical and surgical interventions for obesity treatment. For this reason, gastroenterologists have become part of multidisciplinary teams offering less invasive management alternatives with success rates comparable to conventional treatments. These options are especially suitable for patients who are not candidates for surgical procedures or have a high surgical risk[13], for those who have undergone surgery but developed complications (5%–25%), and for managing patients who have failed to maintain optimal weight in the long term[14].

MEDICATIONS FOR THE MANAGEMENT OF OBESITY

There are several medications available for the treatment of obesity. Among the most commonly used therapeutic options are glucagon-like peptide-1 (GLP-1) receptor agonists, such as liraglutide and semaglutide, as well as other drugs like phentermine-topiramate, naltrexone-bupropion, and orlistat. These medications are indicated for patients with class I obesity or for those with a BMI ≥27 kg/m^2 who have an obesity-related health condition. In Colombia, two medications are approved for the management of obesity: liraglutide and orlistat.

The effectiveness of different therapeutic options in achieving a weight loss of ≥5% was evaluated in a recent meta-analysis. It found that, in order of efficacy, phentermine-topiramate showed the greatest weight loss (odds ratio [OR]: 8.02), followed by GLP-1 receptor agonists (OR: 6.33), and naltrexone-bupropion (OR: 2.69). Additionally, there was a higher risk of adverse events with GLP-1 agonists and orlistat[15]. It is important to note that the effectiveness of anti-obesity medications in reducing weight has improved with the development of new therapies. First-generation drugs achieved weight loss of 5% to 10% of initial body weight, while newer treatments can result in reductions of up to 10%-15%[16].

In addition to weight loss, GLP-1 medications have been reported to offer protective effects against cardiovascular events and mortality in patients with type 2 diabetes *mellitus*[17]. The *SELECT* study demonstrated benefits in reducing cardiovascular mortality, myocardial infarction, and stroke with weekly doses of 2.4 mg semaglutide compared to placebo in overweight or obese patients without diabetes but with underlying cardiovascular disease[16,18-20]. New pharmacological therapies are under study, including tirzepatide, retatrutide, and orforglipron, which have shown weight reductions of 20.9%, 24.2%, and 14.7%, respectively, compared to placebo[12,21,22].

Table 1 presents the characteristics of the medications commonly used in the management of obesity.

BARIATRIC ENDOSCOPY FOR THE MANAGEMENT OF OBESITY

Bariatric endoscopy (BE) procedures have been developed to enhance treatment options for individuals who are not candidates for conventional bariatric surgery. These procedures are less invasive, shorter in duration, performed on an outpatient basis, and offer quicker recovery times[17,23]. Among these interventions are the use of the intragastric balloon (IGB), endoscopic sleeve gastroplasty (ESG), primary obesity surgery endolumenal (POSE), and post-bariatric revision or repair procedures such as transoral outlet reduction (TORe).

Intragastric Balloon

The use of IGB has demonstrated a reduction in the amount of food consumed, secondary to reduced gastric capacity and delayed gastric emptying. Currently, a saline-filled balloon containing methylene blue is used, and it is removed after 6-12 months. Air-filled balloons have shown less weight loss (3-4 kg on average) compared to liquid-filled balloons[24,25]. The IGB placement is performed in an endoscopy unit, is an outpatient procedure, and lasts approximately 30 minutes, with discharge occurring one to two hours afterward. **Figures 1**, **2, 3,** and **4** illustrate key moments and steps to ensure the proper placement of an IGB.

According to the American Gastroenterological Association (AGA), IGB placement is recommended for overweight and obese individuals who have failed conventional treatments. The Brazilian Consensus on Endoscopic Gastroplasty (CBGE) recommends IGB placement in patients with overweight and class 1, 2, and 3 obesity, with no upper age limit for the procedure[26]. The prophylactic administration of proton pump inhibitors (PPIs) and antiemetics should be considered during the perioperative period and up to two weeks after device placement, due to the potential for abdominal pain, vomiting, and gastroesophageal reflux disease (GERD)[27].

Approximately 7% of patients who have undergone IGB placement experience dehydration, 2% are readmitted to medical services, and 1% require reintervention[24,28].

Table 1. Medications Frequently Used for the Management of Obesity

Medication/Mechanism of Action	Average Weight Loss Compared to Placebo During the First Year	Contraindications	Adverse Effects	Mode of Administration
Liraglutide (GLP-1 analogue) - Central appetite control, slows gastrointestinal transit, and reduces glucose levels.	- 6% greater than placebo and 4% greater than placebo in patients with T2DM. - Has shown reduction in mortality and cardiovascular disease events in patients with T2DM.	Pregnancy, breastfeeding, family history of medullary carcinoma or multiple endocrine neoplasia syndrome.	Nausea, vomiting, diarrhea, dyspepsia, abdominal pain, constipation, and headache.	- Subcutaneous injection. - Daily administration with weekly dose escalation (0.6 mg; 1.2 mg, 1.8 mg, 2.4 mg, 3 mg).
Semaglutide* (GLP-1 receptor analogue) - Central appetite control, slows gastrointestinal transit, and reduces glucose levels.	- 14.9% on average compared to 2.4% with placebo in non-diabetic patients with overweight or obesity. - Has shown reduction in mortality and cardiovascular disease events in both T2DM and non-diabetic patients with established cardiovascular disease and overweight or obesity.	Pregnancy, breastfeeding, family history of medullary carcinoma or multiple endocrine neoplasia syndrome.	Pancreatitis, nausea, vomiting, diarrhea, dyspepsia, abdominal pain, constipation, and headache.	- Subcutaneous injection. - Weekly administration with weekly dose escalation (0.25 mg, 0.5 mg, 1.0 mg, 1.7 mg, 2.4 mg).
Phentermine and Topiramate - Central appetite control. - Sympathomimetic and GABA receptor activation (phentermine). - Inhibition of carbonic anhydrase receptor (topiramate).	- 9% greater than placebo and 6.7% greater than placebo in patients with T2DM.	Pregnancy, breastfeeding, history of glaucoma, kidney stones, cardiovascular disease, uncontrolled hypertension.	Paresthesias, altered taste (dysgeusia), memory loss, depression, and fetal malformations.	- Oral daily intake. - Starts with low doses (3.75 mg/23 mg) with gradual increases after day 14.
Naltrexone and Bupropion - Central appetite control. - Opioid receptor antagonist (naltrexone). - Dopamine and norepinephrine reuptake inhibitor (bupropion).	- 5% greater than placebo and 3.2% greater than placebo in patients with T2DM.	Pregnancy, breastfeeding, uncontrolled hypertension, seizures, bipolar disorder, bulimia, anorexia, opioid use.	Dry mouth, nausea, vomiting, irritability, headache, and insomnia.	- Oral daily intake. - Starts with 8 mg/90 mg during the first week with weekly dose escalation until reaching 2 tablets in the morning and 2 in the evening by the fourth week of treatment.
Orlistat - Central appetite control and stimulation of norepinephrine, serotonin, and dopamine release. - Inactivation of gastric and pancreatic lipase.	- 2.9% weight reduction greater than placebo.	Pregnancy, breastfeeding, and patients with cholestasis.	Steatorrhea, fecal urgency, and fat-soluble vitamin deficiencies.	- Oral daily intake. - 60-120 mg three times a day.

*As of now, semaglutide is approved in Colombia for the management of diabetes, but not as a weight control medication. T2DM: type 2 diabetes mellitus; GLP-1: glucagon-like peptide 1. Adapted and modified from: Schmitz SH, and colleagues. Gastrointest Endosc Clin N Am. 2023;52:661-80[41].

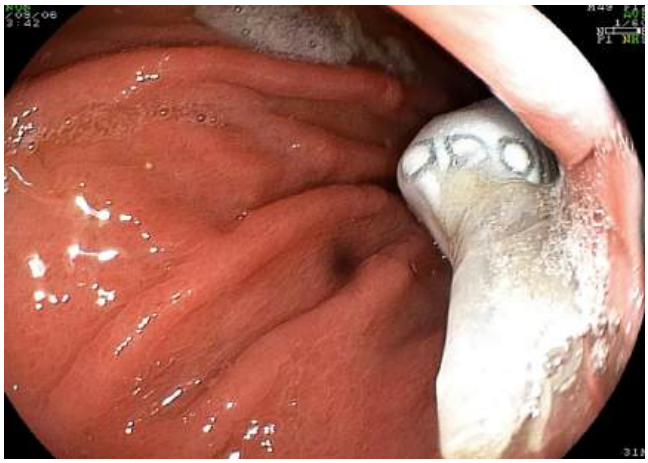

Figure 1. Subcardial positioning as a reference point for initiating balloon inflation. Author's file.

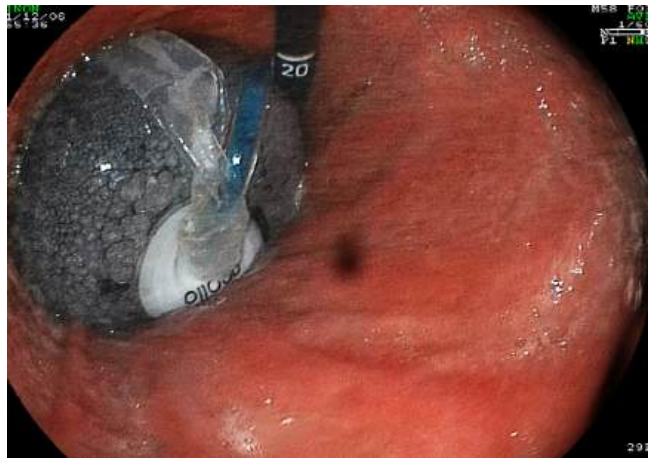

Figure 2. Retroflexion view as an optional maneuver for full visualization of the balloon during inflation with saline solution and methylene blue. Author's file.

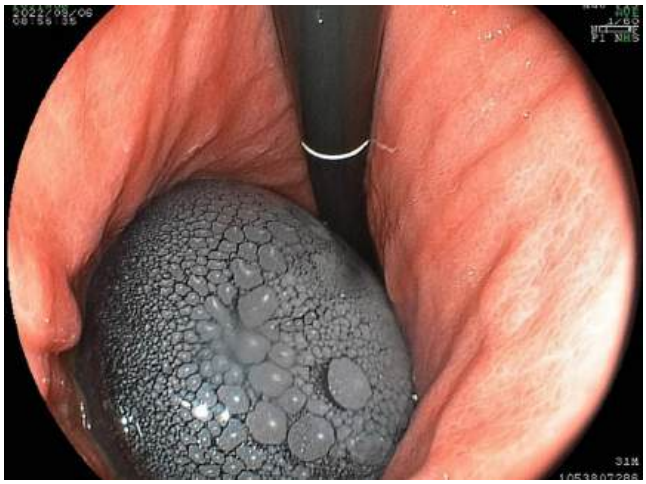

Figure 3. Inflated balloon viewed in retroflexion. Author's file.

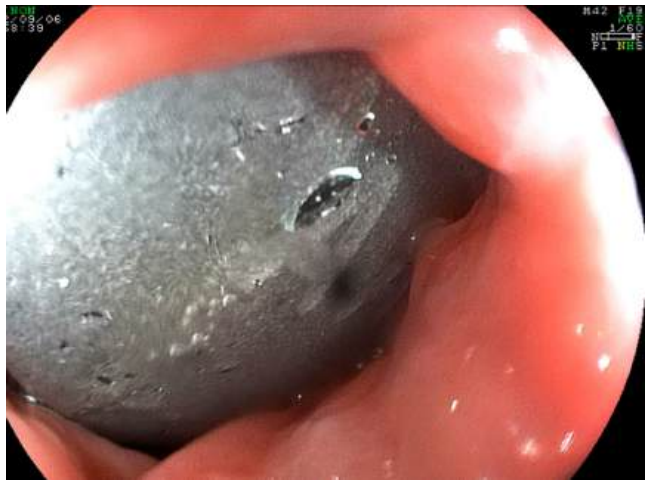

Figure 4. Inflated balloon at the subcardial level observed with direct vision. Author's file.

Complications have been reported in fewer than 2% of patients, including hyperinflation, spontaneous rupture, migration, gastric ulcer, bleeding, pancreatitis, and premature or early removal[25].

From a technical standpoint, there are different types of devices available. **Table 2** describes four therapeutic alternatives commonly used in Colombia.

Endoscopic Sleeve Gastroplasty (ESG)

ESG is the most commonly performed gastric remodeling procedure and involves placing several continuous sutures along the greater curvature of the stomach; a second layer of linear sutures can also be placed as reinforcement (**Figure 5**). Current evidence shows total weight loss effectiveness between 16% and 20% at 12 months[30-32], along with statistically significant reductions in blood pressure, waist circumference, triglycerides, glycated hemoglobin (HbA_{1c}) levels, and hepatic steatosis index[23]. Although this weight loss is less than that achieved with conventional surgery, ESG has a lower probability of adverse events and shorter recovery times. Additionally, it does not induce *de novo* gastroesophageal reflux disease (GERD) symptoms nor worsen existing GERD[33,34].

According to the U.S. Food and Drug Administration (FDA), candidates for ESG are patients with a BMI between

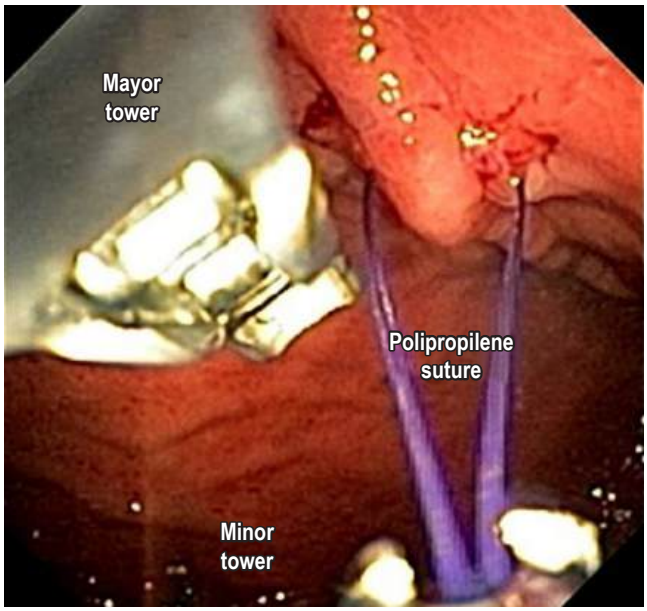

Figure 5. Gastric endosuturing with the Overstitch method. Photo courtesy of Dr. Valeria Atenea Costa.

30 and 50 kg/m^2, while the CBGE considers the procedure for patients with a BMI of 27 kg/m^2[26]. Currently, there is no established maximum age for performing the procedure, so it is recommended that each patient be evaluated individually.

Contraindications include active gastric ulcers, congestive gastropathy, gastric polyposis, giant hiatal hernia, gastric or esophageal varices, and uncontrolled psychiatric disorders.

ESG involves gastric restriction through full-thickness or transmural sutures placed endoscopically[23,35] and is performed under general anesthesia[25,36] (**Figure 6**). Initially, an endoscopic evaluation is required to rule out contraindications and determine potential suture sites in the gastric chamber walls. The procedure begins distally and proceeds proximally, maintaining a U suture pattern. The goal is to reduce gastric capacity by 70%-80%, transforming the gastric fundus into a pouch that limits tolerated volume and induces gastric restriction, resulting in delayed or impaired gastric emptying for solids (**Figure 7**). During and after the procedure, antibiotics, antiemetics, and analgesics are typically administered.

Other Treatment Alternatives

Some patients who undergo bariatric surgery experience weight regain and require post-bariatric repair or revision. The TORe technique is a minimally invasive alternative in which an endoscopic suture is placed at the gastrojejunal level in patients with Roux-en-Y bypass to reduce the size of the dilated stoma following surgery, with or without suturing the gastric pouch (**Figure 8**).

Another recent alternative for managing obesity is primary surgery with POSE endoplication, which uses an incision-

Table 2. Characteristics of Intragastric Balloons Commonly Used in Colombia

Balloon Type	Material	Technical Aspects for Placement and Removal	Reported Weight Loss	Reported Complications[29]
Orbera	Silicone	- Placement via endoscopy - Filled with 400-700 mL of saline solution - Removal via endoscopy after 6-12 months	- 15.3% body weight loss (Orbera six months) compared to 14.7% (Orbera 365) - 26.5% excess weight loss	- 1.4%: device migration - 2%: gastric ulcer - 18.3%: reflux - 1.1%: intolerance
Silimed	Silicone	- Placement via endoscopy - Filled with 650 mL of saline solution - Removal via endoscopy after six months	- Initial weight: 107.7 ± 25.1 kg, weight after six months of treatment: 89.4 kg - Initial BMI: 35.7 ± 5.7 kg/m², BMI after six months of treatment: 31.8 kg/m²	- 21%: epigastric pain - 3.8%: device deflation
Spatz 3	Silicone	- Placement via endoscopy - Filled with 300-900 mL of saline solution - Adjustable valve to optimize results - Removal via endoscopy after 12 months	- 20.1% body weight loss - 45.8% excess weight loss	- Gastric ulcer, migration, intolerance in 4.7% of cases
Elipse Allurion	Polyurethane	- Does not require endoscopy, administered orally - Filled with 550 mL of water - Naturally expelled after four months	- 11.6% body weight loss - 26% excess weight loss	- 2.9%-7.03%: device intolerance - 0.6%: device deflation

Adapted from: Ameen S, and colleagues. Expert Rev Med Devices. 2024;21(1-2):37-54[29].

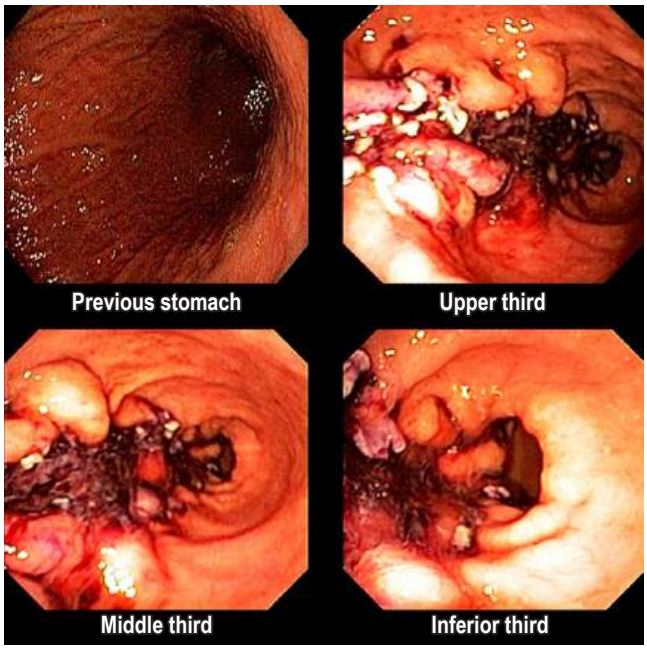

Figure 6. Final endoscopic view of an endoscopic sleeve gastroplasty. Images courtesy of Dr. Andrés Rodríguez.

less technique to create folds in the stomach body, leading to reduced capacity and delayed gastric emptying. Preliminary reports have shown a reduction in excess weight at thee and six months by 42% and 48%, respectively[37,38].

Finally, the duodenal mucosal resurfacing (DMR) technique uses a catheter for hydrothermal ablation of the duodenal mucosa, aimed at improving glycemic control by restoring cellular anatomy and modulating the endocrine response in patients with diabetes[39,40].

These therapeutic alternatives are still under development, and their efficacy and safety profiles in different population groups remain to be fully established.

CONCLUSIONS

Given the current scenario, with a growing number of patients who are overweight or obese, gastroenterologists play a crucial role in managing and monitoring patients who have not undergone surgical interventions or who have experienced poor outcomes in sustaining weight loss and/or complications from such procedures. These issues must be managed in collaboration with the surgical team.

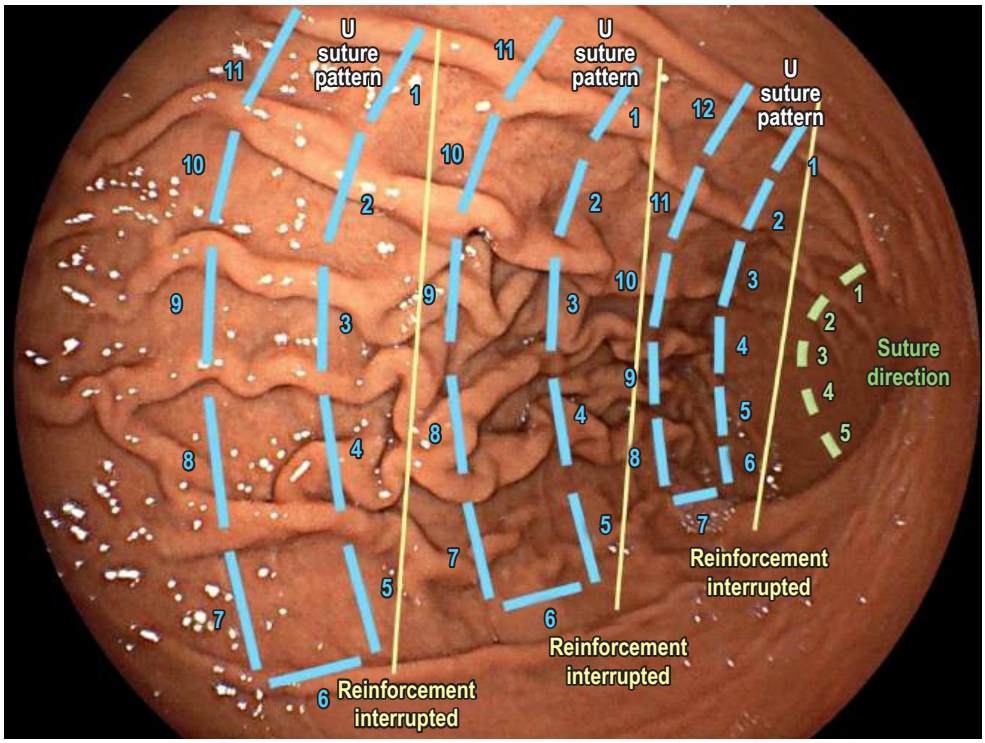

Figure 7. Gastric restriction with ESG. Adapted from: Barrichello S, and colleagues. Gastrointestinal Endoscopy. 2019;90(5):770-780[42].



Figure 8. Video showing post-bariatric endoscopic repair after gastric bypass: TORe method with argon plasma and gastric endosuturing. Video courtesy of Dr. Jesús Rodríguez and Dr. Valeria Atenea Costa. Available at https://youtu.be/pbs6ezdDQ9M

It is important to highlight the unmet needs in obesity control for a large number of patients. Pharmacotherapy as monotherapy and lifestyle interventions have shown modest short- to medium-term results, which are unsustainable in the long term. On the other hand, while bariatric surgery is effective, it remains inaccessible to many patients due to its cost, in addition to the potential complications and its invasive nature. This review outlines minimally invasive, reversible, effective, and safe bariatric endoscopy (BE) alternatives. However, additional studies are needed to determine long-term efficacy and outcomes regarding metabolic adjustments and comorbidities in Latin American populations, considering the specific social, cultural, and biological aspects of these communities. Nonetheless, it is clear that the future of obesity medicine lies in a multidisciplinary approach and close follow-up, requiring the combination of various treatment strategies.

REFERENCES

1. World Health Organization (WHO). WHO European Regional Obesity Report 2022 [Internet]. Copenhagen: WHO Regional Office for Europe; 2022 [consultado el 15 de enero de 2024]. Disponible en: https://iris.who.int/bitstream/handle/10665/353747/9789289057738-eng.pdf?sequence=1
2. Ward ZJ, Bleich SN, Cradock AL, Barrett JL, Giles CM, Flax C, et al. Projected U.S. State-Level Prevalence of Adult Obesity and Severe Obesity. N Engl J Med. 2019;381(25):2440-2450. https://doi.org/10.1056/NEJMsa1909301
3. Alfaris N, Alqahtani AM, Alamuddin N, Rigas G. Global Impact of Obesity. Gastroenterol Clin North Am. 2023;52(2):277-93. https://doi.org/10.1016/j.gtc.2023.03.002
4. Lobstein T, Jackson-Leach R, Powis J, Brinsden H, GrayWorld M. World Obesity Atlas 2023 [Internet]. World Obesity Federation; 2023 [consultado el 15 de enero de 2024]. Disponible en: https://s3-eu-west-1.amazonaws.com/wof-files/World_Obesity_Atlas_2023_Report.pdf
5. Chooi YC, Ding C, Magkos F. The epidemiology of obesity. Metabolism. 2019;92:6-10. https://doi.org/10.1016/j.metabol.2018.09.005
6. Ulijaszek S. Obesity and environments external to the body. Philos Trans R Soc Lond B Biol Sci. 2023;378(1885):20220226. https://doi.org/10.1098/rstb.2022.0226
7. Herrán OF, Bermúdez JN, Zea MdP. Cambios alimentarios en Colombia; resultados de dos encuestas nacionales de nutrición, 2010-2015. Salud UIS. 2020;52(1):21-31. https://doi.org/10.18273/revsal.v52n1-2020004
8. NCD Risk Factor Collaboration (NCD-RisC). Worldwide trends in underweight and obesity from 1990 to 2022: a pooled analysis of 3663 population-representative studies with 222 million children, adolescents, and adults. Lancet. 2024;403(10431):1027-1050. https://doi.org/10.1016/S0140-6736(23)02750-2
9. Shay JES, Singh A. The Effect of Obesity on Gastrointestinal Disease. Gastroenterol Clin North Am. 2023;52(2):403-15. https://doi.org/10.1016/j.gtc.2023.03.008
10. Ahern AL, Breeze P, Fusco F, Sharp SJ, Islam N, Wheeler GM, et al. Effectiveness and cost-effectiveness of referral to a commercial open group behavioural weight management programme in adults with overweight and obesity: 5-year follow-up of the WRAP randomised controlled trial. Lancet Public Health. 2022;7(10):e866-e75. https://doi.org/10.1016/S2468-2667(22)00226-2
11. Perdomo CM, Cohen RV, Sumithran P, Clement K, Fruhbeck G. Contemporary medical, device, and surgical therapies for obesity in adults. Lancet. 2023;401(10382):1116-30. https://doi.org/10.1016/S0140-6736(22)02403-5
12. Schmitz SH, Aronne LJ. The Effective Use of Anti-obesity Medications. Gastroenterol Clin North Am. 2023;52(4):661-80. https://doi.org/10.1016/j.gtc.2023.08.003
13. Muller TD, Bluher M, Tschop MH, DiMarchi RD. Anti-obesity drug discovery: advances and challenges. Nat Rev Drug Discov. 2022;21(3):201-23. https://doi.org/10.1038/s41573-021-00337-8

14. Phillips BT, Shikora SA. The history of metabolic and bariatric surgery: Development of standards for patient safety and efficacy. Metabolism. 2018;79:97-107. https://doi.org/10.1016/j.metabol.2017.12.010
15. Shi Q, Wang Y, Hao Q, Vandvik PO, Guyatt G, Li J, et al. Pharmacotherapy for adults with overweight and obesity: a systematic review and network meta-analysis of randomised controlled trials. Lancet. 2022;399(10321):259-69. https://doi.org/10.1016/S0140-6736(21)01640-8
16. Wilding JPH, Batterham RL, Calanna S, Davies M, Van Gaal LF, Lingvay I, et al. Once-Weekly Semaglutide in Adults with Overweight or Obesity. N Engl J Med. 2021;384(11):989-1002. https://doi.org/10.1056/NEJMoa2032183
17. Mok J, Adeleke MO, Brown A, Magee CG, Firman C, Makahamadze C, et al. Safety and Efficacy of Liraglutide, 3.0 mg, Once Daily vs Placebo in Patients With Poor Weight Loss Following Metabolic Surgery: The BARI-OPTIMISE Randomized Clinical Trial. JAMA Surg. 2023;158(10):1003-11. https://doi.org/10.1001/jamasurg.2023.2930
18. Ryan DH, Lingvay I, Colhoun HM, Deanfield J, Emerson SS, Kahn SE, et al. Semaglutide Effects on Cardiovascular Outcomes in People With Overweight or Obesity (SELECT) rationale and design. Am Heart J. 2020;229:61-9. https://doi.org/10.1016/j.ahj.2020.07.008
19. Lingvay I, Brown-Frandsen K, Colhoun HM, Deanfield J, Emerson SS, Esbjerg S, et al. Semaglutide for cardiovascular event reduction in people with overweight or obesity: SELECT study baseline characteristics. Obesity (Silver Spring). 2023;31(1):111-22. https://doi.org/10.1002/oby.23621
20. Lincoff AM, Brown-Frandsen K, Colhoun HM, Deanfield J, Emerson SS, Esbjerg S, et al. Semaglutide and Cardiovascular Outcomes in Obesity without Diabetes. N Engl J Med. 2023;389(24):2221-32. https://doi.org/10.1056/NEJMoa2307563
21. Jastreboff AM, Kaplan LM, Frias JP, Wu Q, Du Y, Gurbuz S, et al. Triple-Hormone-Receptor Agonist Retatrutide for Obesity - A Phase 2 Trial. N Engl J Med. 2023;389(6):514-26. https://doi.org/10.1056/NEJMoa2301972
22. Wharton S, Blevins T, Connery L, Rosenstock J, Raha S, Liu R, et al. Daily Oral GLP-1 Receptor Agonist Orforglipron for Adults with Obesity. N Engl J Med. 2023;389(10):877-88. https://doi.org/10.1056/NEJMoa2302392
23. Abu Dayyeh BK, Bazerbachi F, Vargas EJ, Sharaiha RZ, Thompson CC, Thaemert BC, et al. Endoscopic sleeve gastroplasty for treatment of class 1 and 2 obesity (MERIT): a prospective, multicentre, randomised trial. Lancet. 2022;400(10350):441-51. https://doi.org/10.1016/S0140-6736(22)01280-6
24. Crossan K, Sheer AJ. Intragastric Balloon. StatPearls. Treasure Island (FL) ineligible companies. Disclosure: Amy Sheer declares no relevant financial relationships with ineligible companies; 2024.
25. Force ABET, Committee AT, Abu Dayyeh BK, Kumar N, Edmundowicz SA, Jonnalagadda S, et al. ASGE Bariatric Endoscopy Task Force systematic review and meta-analysis assessing the ASGE PIVI thresholds for adopting endoscopic bariatric therapies. Gastrointest Endosc. 2015;82(3):425-38 e5. https://doi.org/10.1016/j.gie.2015.03.1964
26. Neto MG, Silva LB, de Quadros LG, Grecco E, Filho AC, de Amorim AMB, et al. Brazilian Consensus on Endoscopic Sleeve Gastroplasty. Obes Surg. 2021;31(1):70-8. https://doi.org/10.1007/s11695-020-04915-4
27. Muniraj T, Day LW, Teigen LM, Ho EY, Sultan S, Davitkov P, et al. AGA Clinical Practice Guidelines on Intragastric Balloons in the Management of Obesity. Gastroenterology. 2021;160(5):1799-808. https://doi.org/10.1053/j.gastro.2021.03.003
28. Dang JT, Switzer NJ, Sun WYL, Raghavji F, Birch DW, Karmali S. Evaluating the safety of intragastric balloon: An analysis of the Metabolic and Bariatric Surgery Accreditation and Quality Improvement Program. Surg Obes Relat Dis. 2018;14(9):1340-7. https://doi.org/10.1016/j.soard.2018.05.003
29. Ameen S, Merchant HA. Intragastric balloons for obesity: critical review of device design, efficacy, tolerability, and unmet clinical needs. Expert Rev Med Devices. 2024;21(1-2):37-54. https://doi.org/10.1080/17434440.2023.2289691
30. Alexandre F, Lapergola A, Vannucci M, Pizzicannella M, D'Urso A, Saviano A, et al. Endoscopic management of obesity: Impact of endoscopic sleeve gastroplasty on weight loss and co-morbidities at six months and one year. J Visc Surg. 2023;160(2S):S38-S46. https://doi.org/10.1016/j.jviscsurg.2022.12.003
31. Barrichello S, Hourneaux de Moura DT, Hourneaux de Moura EG, Jirapinyo P, Hoff AC, Fittipaldi-Fernandez RJ, et al. Endoscopic sleeve gastroplasty in the management of overweight and obesity: an international multicenter study. Gastrointest Endosc. 2019;90(5):770-80. https://doi.org/10.1016/j.gie.2019.06.013
32. Beran A, Matar R, Jaruvongvanich V, Rapaka BB, Alalwan A, Portela R, et al. Comparative Effectiveness and Safety Between Endoscopic Sleeve Gastroplasty and Laparoscopic Sleeve Gastrectomy: a Meta-analysis of 6775 Individuals with Obesity. Obes Surg. 2022;32(11):3504-12. https://doi.org/10.1007/s11695-022-06254-y
33. Seo DJ, Simsek C, Chan WW, Thompson CC, Jirapinyo P. Improvement of gastroesophageal reflux symptoms following endoscopic sleeve gastroplasty. Gastroenterology. 2022;162(7):S-339-S-40. https://doi.org/10.1016/S0016-5085(22)60818-7
34. Sharaiha RZ, Hajifathalian K, Kumar R, Saunders K, Mehta A, Ang B, et al. Five-Year Outcomes of Endoscopic Sleeve Gastroplasty for the Treatment of Obesity. Clin Gastroenterol Hepatol. 2021;19(5):1051-7 e2. https://doi.org/10.1016/j.cgh.2020.09.055

35. Wang JW, Chen CY. Current status of endoscopic sleeve gastroplasty: An opinion review. World J Gastroenterol. 2020;26(11):1107-12. https://doi.org/10.3748/wjg.v26.i11.1107
36. Lopez-Nava G, Bautista-Castano I, Jimenez A, de Grado T, Fernandez-Corbelle JP. The Primary Obesity Surgery Endolumenal (POSE) procedure: one-year patient weight loss and safety outcomes. Surg Obes Relat Dis. 2015;11(4):861-5. https://doi.org/10.1016/j.soard.2014.09.026
37. Reja D, Zhang C, Sarkar A. Endoscopic bariatrics: current therapies and future directions. Transl Gastroenterol Hepatol. 2022;7:21. https://doi.org/10.21037/tgh.2020.03.09
38. Singh S, Bazarbashi AN, Khan A, Chowdhry M, Bilal M, de Moura DTH, et al. Primary obesity surgery endoluminal (POSE) for the treatment of obesity: a systematic review and meta-analysis. Surg Endosc. 2022;36(1):252-66. https://doi.org/10.1007/s00464-020-08267-z
39. de Oliveira GHP, de Moura DTH, Funari MP, McCarty TR, Ribeiro IB, Bernardo WM, et al. Metabolic Effects of Endoscopic Duodenal Mucosal Resurfacing: a Systematic Review and Meta-analysis. Obes Surg. 2021;31(3):1304-12. https://doi.org/10.1007/s11695-020-05170-3
40. Mingrone G, van Baar AC, Deviere J, Hopkins D, Moura E, Cercato C, et al. Safety and efficacy of hydrothermal duodenal mucosal resurfacing in patients with type 2 diabetes: the randomised, double-blind, sham-controlled, multicentre REVITA-2 feasibility trial. Gut. 2022;71(2):254-64. https://doi.org/10.1136/gutjnl-2020-323608
41. Schmitz SH, Aronne LJ. The Effective Use of Anti-obesity Medications. Gastrointest Endosc Clin N Am. 2023;52:661-80. https://doi.org/10.1016/j.gtc.2023.08.003
42. Barrichello S, Hourneaux de Moura DT, Hourneaux de Moura EG, Jirapinyo P, Hoff AC, Fittipaldi-Fernandez RJ, et al. Endoscopic sleeve gastroplasty in the management of overweight and obesity: an international multicenter study. Gastrointestinal Endoscopy. 2019;90(5):770-780. https://doi.org/10.1016/j.gie.2019.06.013

https://doi.org/10.22516/25007440.1265

Review article

Research and Publish. 3. How to Conduct a Statistical Analysis of Research

Gerardo Andrés Puentes-Leal.[1*]

OPEN ACCESS

Citation:
Puentes-Leal GA. Research and Publish. 3. How to Conduct a Statistical Analysis of Research. Revista. colomb. Gastroenterol. 2024;39(3):296-301.
https://doi.org/10.22516/25007440.1265

[1] Internist and Gastroenterologist. Specialist in Clinical Epidemiology and University Teaching, Master's in Health Economics, Centro Hospitalario Serena del Mar, Cartagena de Indias. Cartagena, Colombia.

***Correspondence:** Gerardo Andrés Puentes-Leal.
gandrespl@yahoo.com.ar

Received: 06/08/2024
Accepted: 20/08/2024

Abstract

Currently, clinical practice must integrate evidence-based medicine. This requires a rigorous scientific method that includes identifying a knowledge uncertainty (the problem), formulating a question, conducting a systematic search of the available evidence, selecting the best valid evidence, interpreting and applying it, and if this evidence does not exist, the scientist (the physician) must generate that knowledge through a research design. A part of the methodological process is statistical analysis, which, for example, involves inputting clinical data (the study's database) into a statistical machine that has various mathematical processing options (calculating statistical metrics) to obtain a result that must be validated, interpreted, and analyzed to justify its real-world applicability. This review aims to contextualize some basic statistical concepts and proposes a succinctly organized set of steps for conducting a statistical analysis, which is intended to encourage further exploration to develop a critical perspective when reviewing a research design.

Keywords

Statistical Data Analysis, Validity of Results, Statistical Inference, Methodology.

INTRODUCTION

Clinical research should be utilized by physicians as a tool to help reduce uncertainty in scientific knowledge. It seeks to answer questions that can solve problems related to the health conditions of our patients, enabling us to make sound decisions in medical practice[1]. This process, which refers to the integration of scientific evidence, medical knowledge, and clinical experience, is what defines evidence-based medicine[2]. Research requires a scientific method, and when it comes to quantitative research, the method involves transforming clinical data into medical knowledge[2].

The organization and transformation of this data using mathematical formulas is known as statistical analysis. However, research can yield results that deviate from reality, or in other words, erroneous results (**Figure 1**). One of the problems that arise in research is the inappropriate use of statistical tests, which stems from a lack of knowledge about statistics and the improper application of research methodology[3,4]. The risk lies in researchers or readers not recognizing potential errors in research findings and conclusions, known as *false positives* or *false negatives* (alpha and beta errors)[5]. Internal and external validity of research is achieved when the likelihood of alpha or beta error is reduced, and the results are applicable to the target population. A basic recommendation to keep in mind when reading or conducting research is to establish the hypothesis that aims to answer the research question and then determine how to

© 2024 Asociación Colombiana de Gastroenterología

test that hypothesis. In quantitative research, this includes the statistical analysis.

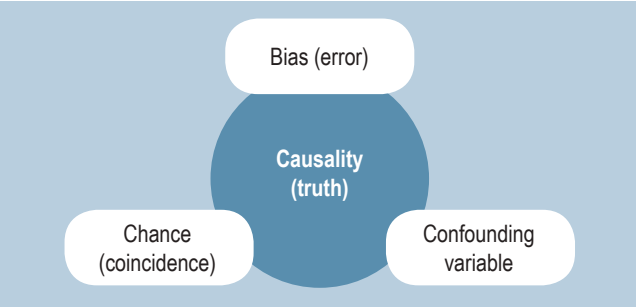

Figure 1. Possible outcomes of a research study. Author's File.

More and more, physicians are now required to justify their medical practices based on scientific evidence, which has led to an increased need for generating clinical research. However, not all physicians are epidemiologists, and many lack a structured understanding of statistics. This classifies physicians into two groups: those who base their medical decisions on guidelines, articles, and protocols, and those with a basic understanding of clinical epidemiology, who can constructively critique the methodology and results of such guidelines, protocols, and scientific articles. Therefore, this review proposes to cover some basic principles that help responsibly critique research studies and provide a foundation for conducting statistical analyses in one's own research projects.

BASIC CONCEPTS: FROM SIMPLICITY TO UNDERSTANDING THE PROCESS OF STATISTICAL ANALYSIS

Hypothesis Testing[6,7]

A problem requires a solution, and to address this, a scientific question is posed that seeks to answer the potential solution. The question is formulated based on a proposition derived from prior scientific knowledge and supported by data. This proposition is called a *scientific hypothesis* and is based on facts and scientific understanding. There is an alternative hypothesis and a null hypothesis, which either confirm or refute the answer to the question. The process of testing the hypothesis is the scientific method in which data are used through observation or experimentation.

Statistical Measures

A statistical measure is a formula or calculation applied to sample data that yields a value, which can then be interpreted to describe the data. There are descriptive statistics related to central tendency (mean, median, mode) and those related to dispersion (standard deviation, range, and variance). Additionally, there are association measures that compare two groups of data between populations. Depending on the research design, these could include relative risk (RR), odds ratio (OR), hazard ratio (HR), among others. It is important to clarify that statistical measures are calculated according to the nature of the variable (e.g., nominal qualitative versus ratio quantitative).

Chance[8]

Chance refers to an unpredictable outcome due to randomness. In statistics, the result of a statistical measure is neither reproducible nor due to a mathematical algorithm; in other words, the outcome is random and due to chance. The scientific method seeks to minimize random outcomes by establishing probabilities for a phenomenon when crossing variables.

Statistical Significance[6]

When comparing two groups of data and obtaining a number that indicates their relationship or difference (such as an odds ratio), a mathematical (statistical) formula is applied to evaluate whether the result is due to chance. If it is considered statistically significant, it is assumed there is a low probability that the result occurred by chance (although it can never be guaranteed 100%). The goal is to minimize this chance risk to between 1%, 5%, and 10%, which is why the p-value of <0.05 (less than 5%) is commonly used. Similarly, when comparing results between two groups, statistical formulas are calculated to determine if the obtained statistical measure reflects a real and statistically significant difference. However, it is important to note that this does not always mean that the difference is large, important, or clinically significant.

Bias

When collecting, processing, measuring, and applying mathematical formulas to data, the goal is to show that the values represent the true phenomenon—that is, that they are real. Bias refers to a deviation in the process of collecting, processing, and measuring data, which leads to false results that do not reflect reality. Biases can occur at any stage in the process of database creation and data analysis. Before performing statistical analyses, biases should be measured, quantified, mitigated, and predicted. Recognizing biases is part of the discussion and analysis of results, allowing

the reader to evaluate whether they accept the findings and apply them to their clinical practice, considering that the biases do not significantly influence the likelihood of errors in the results. Alternatively, the reader may reject the information due to the risk of obtaining erroneous results in clinical practice. The quality of research is inversely proportional to the level of bias present.

Confounding

When analyzing the association between two variables, A and B, that appears to be reproducible and consistent, but there is a third variable, C, that explains this association, and when controlled—either by removing or matching between groups—the association between A and B disappears. In this case, variable C is a confounding variable.

Causality

Causality is confirmed when one variable is shown to cause an effect in another variable, and this effect is not due to chance, bias, or a confounding variable.

Type I Error (Alpha)

The best way to understand this error is as a false positive. The conclusion indicates that the alternative hypothesis is confirmed and accepted. For example, variable A causes B, or factor C prevents outcome D, among others. However, when the study methodology is replicated, the same result is not obtained, and upon investigation, biases, chance, confounding variables, and other factors are identified. Statistical significance is used to reduce this type of error. It is often compared to "wrongly convicting an innocent person, sentencing them as guilty".

Type II Error (Beta)

This is a false negative. The conclusion of the study states that the null hypothesis is accepted, meaning there is no causality or association between the variables being tested. However, in reality, this association or difference does exist. It is often likened to "letting a guilty person go free".

Descriptive Statistics

This type of statistics describes data variables from a population. It covers the entire population and summarizes the data using graphs or statistical measures of central tendency, dispersion (for quantitative variables), or frequencies (for nominal variables).

Inferential Statistics

When it is not possible to describe all the data of a population, random samples (sample sizes) are taken, analyzed, and used to represent (infer) the results for the entire population or to extrapolate to other populations with similar characteristics. To extrapolate study results, statistical formulas are used to estimate the probability that the results represent the population.

STATISTICAL ANALYSIS

Statistical analysis is a mathematical and statistical methodology used to organize, describe, analyze, and interpret data in a valid way, establishing probabilities for extrapolation; in other words, to use the data for decision-making.

Types of Statistical Analysis

Figure 2 shows the types of analysis.

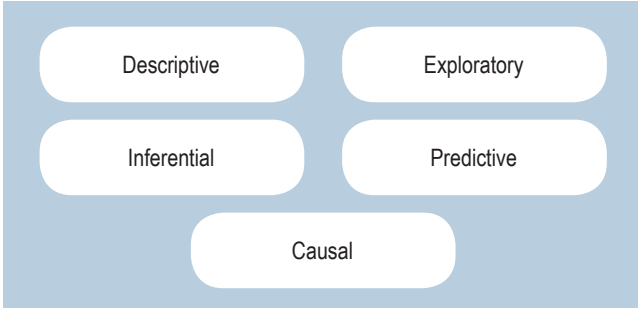

Figure 2. Types of Statistical Analysis. Author's File.

Descriptive

The results from a sample database are summarized in tables, graphs, and charts, and can be used to formulate hypotheses. These results cannot be generalized to the entire population; however, they are commonly used in most research designs and form the basis of descriptive observational studies.

Exploratory

This goes beyond descriptive analysis by examining the relationships between variables and seeking associations (correlations) among observations. It aims to control certain variables within subgroups of the database for analysis. Demographic characteristics that differentiate two groups can be identified. Exploratory analysis is used in analytical observational research designs.

Inferential

Descriptive results from a database are subjected to statistical tests that assess whether they can be extrapolated to other similar or general populations. The analysis also evaluates the probability of relationships between variables in the sample and confirms associations and causalities. This type of analysis requires a significant sample size, bias control, and results must be tested to rule out the likelihood of chance. It is used in analytical observational and experimental research designs, as well as systematic reviews.

Predictive

Analytical and inferential results from a research design are applied to mathematical models that estimate future trends, behaviors, or the likelihood of outcomes when variables are modified. It is used in survival designs and economic models.

Causal

This analysis seeks to confirm that a variable not only correlates with another but also causes the effect, without being due to a confounding variable or chance. Different models exist for establishing causality, with the Bradford-Hill model[9] being the most recommended. It suggests fulfilling the following criteria: strength of association, consistency, specificity, temporality, biological gradient, biological plausibility, coherence, experimental evidence, analogy, reversibility, and critical judgment. Causal analysis is used in experimental research designs and systematic reviews.

Proposal for Conducting a Statistical Analysis for Quantitative Studies

The steps for conducting a statistical analysis in quantitative studies are as follows (**Figure 3**):

1. Establish the research question and problem: What does the author want to investigate? Propose the null and alternative hypotheses[1].
2. Review the database: Explore the data, identify the characteristics of the variables (qualitative or quantitative), and organize the data by variables. Provide a clear and realistic description of the data available. Review the research design[4].
3. Evaluate the reliability and validity of data collection: Assess biases in information and measurement. Evaluate how the data were collected and measured, identify potential recording errors, and determine how closely the data reflect what was intended to be measured. Analyze how the data relate to the study subjects[10].
4. Select the statistical program: Choose the most practical and reliable statistical software based on the type of analysis needed. Available programs include MS Excel, SPSS, R, Stata, OpenEpi, Epidat, among others.
5. Perform descriptive statistical analysis on each variable, typically represented in the demographic table of an article:
   - Frequency distribution (for qualitative variables);
   - Measures of central tendency for quantitative variables (mean, mode, and median);

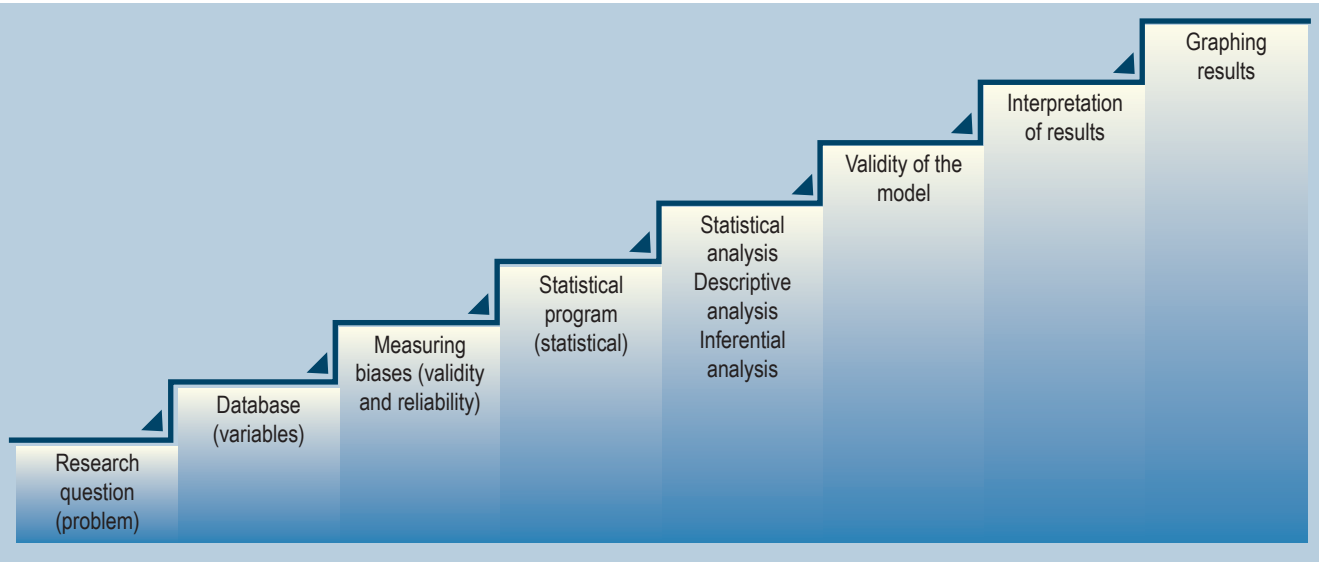

Figure 3. Proposal for Conducting a Statistical Analysis for Quantitative Studies

- Measures of variability for quantitative variables (range, standard deviation, and variance).

6. Conduct inferential statistical analysis, taking into account the hypotheses, sample size, and distribution. This analysis is performed when the goal is to present results that readers can use to make decisions in their clinical practice. Design a model that considers and describes the relationship between the data and the study subjects[11]:
   - Parametric analysis: Used when hypotheses involve interval or ratio quantitative variables. Various statistical tests can be applied, such as the Student's t-test, linear regression, correlation coefficients, difference of proportions tests like the Z standard error, chi-square, Fisher's exact test, analysis of variance (ANOVA), and analysis of covariance (ANCOVA).
   - Non-parametric analysis: Used when hypotheses involve nominal or ordinal qualitative variables. Available statistical tests include Pearson's chi-square test, binomial test, Fisher's test, Spearman and Kendall correlation coefficients, tests for cross-tabulations, Wilcoxon, among others[12].
   - Multivariate analysis: Used when evaluating the effect of more than one variable on an outcome. Available statistical tests include the log-linear model, multiple linear regression, canonical correlation, ANOVA, MANOVA, ANCOVA, and MANCOVA, among others[13].
7. Evaluate the model to determine its validity: It is essential to ensure that the database contains all the necessary variables to address the research question, that the method of measuring the variable was the most appropriate, and that the statistical measures or operational metrics selected to calculate differences or associations best describe the phenomenon under investigation. The method can be applied to a different database with similar parameter ranges, and if the results are consistent and reproducible, the model can be considered valid[10].
8. Interpret the results using foundational scientific knowledge and propose new hypotheses: It is important to take into account the limitations of the data and the techniques used, as well as any other relevant information that may influence the conclusions[2,6,10].
9. Graph and present results: The selection of graphs or result algorithms is not a minor process; the goal is to present the findings clearly and accurately[10].

CONCLUSIONS

For the results of a study to have internal validity, proper statistical analysis must be conducted. This requires aligning the research question, the study design, and the database that collects the variables to be analyzed. Each variable should be carefully interpreted, and the appropriate statistical methods should be applied for reprocessing and interpretation. It is always crucial to consider how closely the results represent reality, and how much they may be influenced by biases, confounding variables, or chance. A good statistical analysis reduces the probability of error. A medical researcher's best ally is a biostatistician who can process the mathematical part of the database without losing sight of the clinical concept behind the entire research design.

REFERENCES

1. Albis-Feliz R. Investigar y publicar. 1. Cómo formular una pregunta de investigación. Rev Colomb Gastroenterol. 2024;39(1):59-61. https://doi.org/10.22516/25007440.1174
2. Vega-de Céniga, M, Allegue-Allegue N, Bellmunt-Montoya S, López-Espada C, Riera-Vázquez R, Solanich-Valldaura T, et al. Medicina basada en la evidencia: concepto y aplicación. Angiología. 2009;61(1):29-34. https://doi.org/10.1016/S0003-3170(09)11004-0
3. Ramírez Ríos A, Polack Peña AM. Estadística inferencial. Elección de una prueba estadística no paramétrica en investigación científica. Horizonte de la Ciencia. 2020;10(19):191-208. https://doi.org/10.26490/uncp.horizonteciencia.2020.19.597
4. Rey-Rubiano M. Investigar y publicar. 2. Cómo responder la pregunta "diseño del estudio". Rev Colomb Gastroenterol. 2024;39(2):176-178. https://doi.org/10.22516/25007440.1189
5. Illigens BMW, Lopes F, Fregni F, Brunoni A. Parametric Statistical Tests. En: Fregni F, Illigens B (editores). Critical Thinking in Clinical Research. Nueva York: Oxford University Press; 2018. https://doi.org/10.1093/med/9780199324491.003.0009
6. Suemoto CK, Lee C, Fregni F. Basics of Statistics. En: Fregni F, Illigens B (editores). Critical Thinking in clinical research. Nueva York: Oxford University Press; 2018. https://doi.org/10.1093/med/9780199324491.003.0008

7. S*á*nchez M, Marín G, Quintero I. La importancia de la prueba de hipótesis. Semilla Científica. 2024;5:211-216. https://doi.org/10.37594/sc.v1i5.1381
8. Jiménez Ríos E. Los diccionarios de la Real Academia Española. En: Lexicografía hispánica/The Routledge Handbook of Spanish Lexicography. Routledge; 2024. p. 392-406. https://doi.org/10.4324/9780429244353-29
9. Hill AB. The environment and disease: association or causation? 1965. J R Soc Med. 2015;108(1):32-7. https://doi.org/10.1177/0141076814562718
10. Hernández-Sampieri R, Mendoza C. Metodología de la investigación: las rutas cuantitativa, cualitativa y mixta. McGraw Hill; 2018.
11. Dagnino J. Análisis de proporciones. Rev Chil Anest. 2014;43(2):134-138. https://doi.org/10.25237/revchilanestv43n02.12
12. Fregni F, Lopes F, Matsubayashi SR. Non-Parametric Statistical Tests. En: Fregni F, Illigens B (editores). Critical Thinking in clinical research. Nueva York: Oxford University Press; 2018. https://doi.org/10.1093/med/9780199324491.003.0010
13. Sagaró Del Campo NM, Zamora Matamoros L. Técnicas estadísticas multivariadas para el estudio de la causalidad en medicina. Rev Ciencias Médicas. 2020;24(2):287-300.

https://doi.org/10.22516/25007440.1133

Review article

Disorders of Brain-Gut Interaction (Functional Gastrointestinal Disorders): Neuromodulators in Clinical Practice (Part II)

David Benigno Páramo-Hernández,[1] Luis Fernando Pineda-Ovalle,[2*] Laura Marcela Moya-Valenzuela,[3] Alejandro Concha-Mejía,[4] Juan David Páramo-Díaz.[5]

OPEN ACCESS

Citation:
Páramo-Hernández DB, Pineda-Ovalle LF, Moya-Valenzuela LM, Concha-Mejía A, Páramo-Díaz JD. Disorders of Brain-Gut Interaction (Functional Gastrointestinal Disorders): Neuromodulators in Clinical Practice (Part II). Revista. colomb. Gastroenterol. 2024;39(3):302-309.
https://doi.org/10.22516/25007440.1133

[1] Gastroenterologist and Clinical Epidemiologist, Gut Médica, Instituto de Salud Digestiva. Bogotá, Colombia.
[2] Specialist in Internal Medicine, Gastroenterology, and Epidemiology, Gut Médica, Instituto de Salud Digestiva. Director, Gut Médica. Bogotá, Colombia.
[3] Specialist in Internal Medicine and Gastroenterology. Gastroenterologist, Medicali, Clínica de la Colina and Gut Médica, Instituto de Salud Digestiva. Bogotá, Colombia.
[4] Physician and Surgeon, Specialist in Internal Medicine, Gastroenterology, and Epidemiology. Head of Gastroenterology, Clínica del Country. Bogotá, Colombia.
[5] General Psychiatrist. Instructor Professor, Medical School, Pontificia Universidad Javeriana. Bogotá, Colombia.

***Correspondence:** Luis Fernando Pineda-Ovalle.
lfpinovalle@gmail.com

Received: 30/08/2023
Accepted: 03/04/2024

Abstract

Introduction: This article continues the review of neuromodulators used in clinical practice and their role in treating various disorders of brain-gut interaction (DGBI), particularly gastric, intestinal, and anal disorders. **Materials and Methods:** The working group reviewed the most common pathologies and medications according to the latest literature and the best clinical evidence in each case. **Results:** Due to the diversity of disorders, study types, and therapeutic options, the decision was made to present the evidence with the best outcomes for each case, including the doses used, their results, and side effects. **Conclusions:** The best available evidence of medications used for each DGBI is presented. At the end, a table highlights the most commonly used drugs, their doses, and gastrointestinal effects for each clinical condition, along with another table listing the most important side effects. Since the available evidence is not definitive, more controlled clinical trials are needed for each condition to confirm the effectiveness and safety of these treatments.

Keywords

Digestive system disorders, neurotransmitters, antidepressants.

INTRODUCTION

This article continues the review of neuromodulators used in clinical practice and their role in the treatment of various disorders of brain-gut interaction (DBGI), particularly those affecting the stomach, intestines, and anus.

FUNCTIONAL DYSPEPSIA

Upon confirmation of a functional dyspepsia diagnosis[1-3], treatment should be initiated with acid secretion inhibitors (proton pump inhibitors [PPIs]), H_2 receptor antagonists, potassium-competitive acid blockers (PCABs), and pro-

© 2024 Asociación Colombiana de Gastroenterología

kinetic agents (acetylcholinesterase inhibitors, dopamine receptor antagonists, and serotonin receptor agonists)[1,2]. If there is no improvement, the use of neuromodulators should be considered as a second-line treatment[2]. These are recommended for patients who do not respond to acid suppression and *Helicobacter pylori* eradication, in accordance with British and American guidelines, due to their pain-modulating properties at various levels of the gut-brain axis[4,5]. Their effectiveness may be linked to the high correlation between functional dyspepsia and psychiatric conditions such as anxiety and depression, which impact the brain-gut axis.

The efficacy of tricyclic antidepressants (TCAs) has been studied, showing effectiveness as a second-line treatment, particularly for abdominal pain management. However, in cases of anxiety or depression, they may be considered as first-line treatment.

Both TCAs and selective serotonin reuptake inhibitors (SSRIs) modulate serotonin levels, influencing motility and visceral nociception. Neither SSRIs nor serotonin-norepinephrine reuptake inhibitors (SNRIs) have demonstrated benefit in patients with functional dyspepsia[6]. These medications should be started at low doses, preferably at night, and gradually titrated based on tolerance to avoid side effects that may lead patients to discontinue treatment. The estimated treatment duration is between 6 and 12 months; in some cases, based on clinical progression, they may be continued longer, particularly when there are psychiatric comorbidities. Discontinuing these medications in such cases could result in relapses of these concomitant conditions[4].

Tricyclic Antidepressants

Among the TCAs, imipramine, at a dose of 25 mg for two weeks and then 50 mg for up to 12 weeks, has shown satisfactory overall relief of global dyspepsia symptoms compared to placebo (63% vs. 36%), with a number needed to treat (NNT) of four. It also reduces the overall score of epigastric pain, abdominal distension, postprandial fullness, satiety, and vomiting, along with improvement in mood and anxiety[6]. TCAs should be used with caution due to their side effects, starting with low doses (10 mg/day) and slowly titrating up to a maximum of 30-50 mg/day[4,5]. The side effects are described in **Table 1**[6]. Amitriptyline at a dose of 50 mg, compared to escitalopram at 10 mg and placebo for 10 weeks, showed better symptom improvement in its group, with a global improvement of symptoms. However, both amitriptyline and escitalopram improved quality of life without significant adverse effects (**Table 2**)[6].

Selective Serotonin Reuptake Inhibitors (SSRIs)

One of these medications is sertraline. In a double-blind, randomized, placebo-controlled study, a dose of 50 mg of sertraline was administered for eight weeks. The results

Table 1. Side Effects of Neuromodulators

Group	Medication	Side Effects
TCA	Amitriptyline, imipramine, desipramine, nortriptyline	Sedation, constipation, hypotension, dry mouth, nausea, arrhythmias, weight gain, sexual dysfunction, QT prolongation[6-9]
SSRI	Citalopram, escitalopram, fluoxetine, paroxetine, sertraline	Agitation, diarrhea, insomnia, night sweats, headache, weight loss, sexual dysfunction, drowsiness, dry mouth, headache[8,9]
SNRI	Duloxetine	Nausea, agitation, dizziness, sleep disturbances, fatigue, liver dysfunction[8,9]
Atypical Antipsychotics	Quetiapine	Sedation, drowsiness, dry mouth, metabolic syndrome, cardiac arrhythmias, liver dysfunction, weight gain, diabetes[8,9]
Delta Ligands	Gabapentin, pregabalin	Sedation, headache, dizziness, vertigo, fatigue, weight gain, peripheral edema[8,10,11]
Tetracyclic Antidepressant	Mirtazapine	Weight gain, increased appetite, dry mouth, nausea, constipation, vomiting[6-8]
Antipsychotics	Levosulpiride	Mild drowsiness[6,7]
Anxiolytics	Buspirone	Sedation, headache, diziness[6,7]

Adapted from: Bosman L, and colleagues. 2023[6]; Wauters L, and colleagues. 2020[7]; Drossman DA, and colleagues. 2018[8]; Younger J, and colleagues. 2014[9]; Rao SSC, and colleagues. 2016[10]; Carrington EV, and colleagues. 2020[11].

Table 2. Summary of Neuromodulator Use for Each Clinical Condition

Clinical Condition	Medication	Dose	Study Type	Effects
Functional Dyspepsia	**Tricyclic Antidepressants**			
	Imipramine	25 mg for 2 weeks 50 mg for 12 weeks	RCT[6,7]	Overall relief of dyspepsia, improvement in anxiety
		50 mg/day for four weeks compared to placebo	Cross-over RCT[6,7]	Reduction in IG symptoms in four weeks
	Amitriptyline	Amitriptyline 50 mg Escitalopram 10 mg	RCT[6,7]	Relief of 40% with placebo, 53% with amitriptyline, 38% with escitalopram
	SNRI			
	Venlafaxine	75 mg for two weeks, 150 mg for four weeks	Cross-over double-blind RCT with placebo[6,7]	No significant difference in symptoms compared to placebo
	SSRI			
	Sertraline	50 mg/day for eight weeks	Double-blind placebo-controlled trial[6,7]	Improvement in dyspepsia index, no changes in overall symptoms
	Tetracyclic Antidepressant			
	Mirtazapine	15 mg for eight weeks	Double-blind placebo-controlled trial[6,7,12]	Weight gain, better tolerance to nutrients
	Antipsychotics			
	Levosulpiride	25 mg/day	CCT vs. placebo[6,7]	Overall symptom relief, improved gastric emptying time
	Anxiolytic Agents			
	Buspirone	20-30 mg/day for four weeks	RCT with placebo[6,7,12]	Relief of dyspepsia, postprandial fullness, and distension
IBS	TCA	25-100 (150) mg	Network meta-analysis[19]	Most effective for pain relief between weeks 4 and 12 (RR 0.53; 95% CI: 0.34-0.83)
	Amitriptyline, imipramine, desipramine, nortriptyline		Systematic review and meta-analysis, 12 TCA-specific studies[19]	RR for symptom improvement: 0.65 (CI: 0.55-0.77); NNT: 4.5
	SSRI			
	Citalopram, escitalopram, fluoxetine, paroxetine, sertraline	Psychiatric dose range: citalopram 10-20 mg, escitalopram 20 mg/day, fluoxetine 20 mg/day, paroxetine 20 mg/day, sertraline 50 mg for eight weeks	Systematic review and meta-analysis, 7 SSRI-specific studies[19]	RR for symptom improvement: 0.68 (CI: 0.51-0.91); NNT: 5
	SNRI	Duloxetine 30-90 mg Venlafaxine 225 mg	Case series[19]	40% achieved pain score reduction
	Atypical Antipsychotics	Quetiapine 25-100 mg	Case reports[19]	Improvement in pain and insomnia
		Olanzapine 2.5-10 mg	Case reports[19]	Improvement if diarrhea is present
Centrally Mediated Abdominal Pain	**TCA**	Amitriptyline, imipramine, desipramine, nortriptyline: 25-100 mg	Systematic review and meta-analysis[13,14]	RR for symptom improvement: 1.36 (CI: 1.07-1.71); NNT: 4.5
	Duloxetine	30-60 mg	Cohort studies[15]	Pain reduction
	Pregabalin	75-225 mg	CCT[10]	Improvement in pain scale and quality of life
Functional Anorectal Pain	**TCA**		Case series[10,11]	Pain reduction
	Gabapentin		Case series[10,11]	Pain reduction

TCA: tricyclic antidepressants; CM: centrally mediated; RCT: randomized controlled trial; DB: double-blind; SSRI: selective serotonin reuptake inhibitors; SNRI: serotonin-norepinephrine reuptake inhibitors; NNT: number needed to treat; RR: relative risk; SR & M: systematic review and meta-analysis; IBS: irritable bowel syndrome; CBT: cognitive-behavioral therapy. Adapted from: Bosman L, and colleagues. 2023[6]; Wauters L, and colleagues. 2020[7]; Rao SSC, and colleagues. 2016[10]; Carrington EV, and colleagues. 2020[11]; Engsbro AL, and colleagues. 2021[12]; Ford AC, and colleagues. 2019[13]; Kilgallon E, and colleagues. 2019[14]; Yang H, and colleagues. 2021[15]; Black CJ, and colleagues. 2020[19].

showed a statistically significant improvement in the mean dyspepsia index, but there was no difference in quality of life, subjective global symptom resolution, depression, or anxiety. The reported side effects included constipation and agitation (**Table 1**)[6,16].

Serotonin-Norepinephrine Reuptake Inhibitors (SNRIs)

Venlafaxine is one such drug. In a double-blind, randomized, placebo-controlled study, venlafaxine was administered at a dose of 75 mg/day for two weeks, followed by 150 mg/day for four weeks, and then 75 mg/day for the final two weeks. The study results showed no improvement compared to placebo, neither in symptom severity nor in the number of symptoms, anxiety, depression, or overall health quality[6,16].

Tetracyclic Antidepressant

Mirtazapine has shown effects in relaxing the gastric fundus, reducing early satiety, improving food tolerance, enhancing quality of life, promoting weight gain, and alleviating depressive symptoms and somatization[6,7]. In a randomized placebo-controlled study, mirtazapine at a dose of 15 mg for eight weeks reduced the severity of dyspepsia symptoms and improved early satiety, but there was no difference in key symptoms of functional dyspepsia such as fullness, weight gain, or tolerance to nutrient volumes, nor did it affect gastric emptying. It did improve quality of life and gastrointestinal anxiety, but it did not significantly impact anxiety or depression[6]. Side effects included weight gain, increased appetite, nausea, vomiting, dry mouth, and constipation[16].

Antipsychotics

Levosulpiride at a dose of 25 mg once daily, compared to placebo, showed significant improvement and greater efficacy in relieving dyspeptic symptoms and motility issues, as well as a reduction in gastric emptying time, though mild drowsiness was reported. The effect of levosulpiride on gastric emptying has been evaluated against placebo, showing a reduction in upper abdominal pain, distension, early satiety, nausea, and vomiting, with no reported side effects. British guidelines for functional dyspepsia recommend providing careful explanations about its use and its side effect profile[4].

Anxiolytic Agents

Buspirone, a serotonin 1-A receptor antagonist, relaxes the gastric body and improves gastric accommodation, significantly reducing overall symptoms of functional dyspepsia and postprandial distress syndrome[6,7]. In a randomized, double-blind, placebo-controlled crossover study, a reduction in the severity of dyspepsia symptoms was observed, along with a significant decrease in postprandial fullness and distension[7].

IRRITABLE BOWEL SYNDROME (IBS)

Treatment for irritable bowel syndrome (IBS) begins with educating patients about the condition, emphasizing its benign nature, and explaining the usefulness and safety of diagnostic tests and treatment options. Treatment should be tailored to the specific symptoms and their severity[12,17-20]. Management focuses on controlling pain as the predominant symptom and addressing other symptoms, whether constipation, diarrhea, or alternating between the two, as well as additional symptoms like bloating, which is common in all types of IBS. Thus, treatment options include prokinetics, secretagogues, laxatives, antispasmodic analgesics, among others[8,18]. Pain management often requires a synergistic approach, combining medications that provide peripheral neuromodulation, such as antispasmodics, secretagogues, opioid agonists/antagonists, serotonin receptor antagonists, and centrally acting agents, including the better-known *neuromodulators*, which are discussed in more detail later[19].

First-Line Treatment

For moderate to severe pain, tricyclic antidepressants (TCAs) present the strongest evidence. A recent network meta-analysis ranked TCAs as the most effective for pain relief between weeks 4 and 12 (RR 0.53; 95% confidence interval [CI]: 0.34-0.83)[19]. Due to their complex mechanism of action, their therapeutic properties can derive from both the intended effects and side effects. For example, sedation can help treat insomnia, or increased intestinal transit can help manage diarrhea[8,9]. Regarding the medications in this group:

- Amitriptyline and imipramine (tertiary amines) more commonly cause side effects due to their stronger antimuscarinic and antihistaminic effects.
- Desipramine and nortriptyline (secondary amines) have fewer antihistaminic and antimuscarinic effects than amitriptyline.
- Doses range from 10/25 to 150 mg/day, but the final dose is determined by the balance between side effects and therapeutic benefits (therapeutic index)[8,9].

Serotonin-norepinephrine reuptake inhibitors (SNRIs) also have evidence of efficacy for conditions that often coexist with IBS, such as back pain, headaches, and fibromyal-

gia. They have fewer side effects than TCAs and can be used when TCA side effects are poorly tolerated. This is due to their serotonergic effect and lack of antimuscarinic effects, making this group useful for managing IBS when constipation and depression are part of the clinical picture[8,9].

Selective serotonin reuptake inhibitors (SSRIs) are also part of the first-line treatment, especially when anxiety, depression, obsessive, or phobic characteristics are central alongside IBS symptoms. It is important to note that SSRIs do not help with pain management but rather with overall symptom control, and are used in psychiatric dose ranges[8].

Second-Line Treatment

Drugs like olanzapine and quetiapine are considered atypical antipsychotics, producing fewer extrapyramidal side effects and used as co-treatment in managing abdominal pain in IBS. Quetiapine has multiple effects on different receptors: D_2, 5-HT_2A, H1 receptor antagonist, partial 5-HT_1A receptor agonist, affinity for α_1 and α_2 receptors, and inhibition of norepinephrine reuptake through one of its metabolites (N-desalkylquetiapine). It has shown effects on pain associated with fibromyalgia and is used at low doses (25-200 mg/day for gut-brain axis disorders). Olanzapine has been studied more extensively in managing chronic pain associated with fibromyalgia and headaches, with doses ranging from 2.5-10 mg/day. The adverse effects are described in **Table 1**[8].

Delta ligands are another group of peripheral neuromodulators that block the $\alpha_2\delta$ subunit of voltage-gated calcium channels in neurons. These include gabapentin and pregabalin, both of which have demonstrated a reduction in visceral hypersensitivity in IBS. The coexistence of IBS with fibromyalgia and parietal abdominal pain could be a scenario where this treatment option is viable[8,9].

Lastly, low-dose naltrexone (4.5 mg/day) offers an alternative for chronic pain management, which can be extrapolated to IBS. Its analgesic effect seems to stem not only from opioid antagonism but also from its anti-inflammatory and neuroprotective effects via microglial cells[9].

CENTRALLY MEDIATED ABDOMINAL PAIN SYNDROME

Managing centrally mediated abdominal pain syndrome (CAPS) requires establishing an effective physician-patient relationship, setting treatment goals, and tailoring treatment based on symptom severity, offering a combination of treatment options, including pharmacological and psychological therapies[21-23]. Medical treatment is most effective in the context of a strong physician-patient relationship and a comprehensive biopsychosocial treatment plan[24]. There is limited evidence from studies specifically designed for CAPS treatment, which is why many concepts are general and similar to other pain disorders in brain-gut interaction disorders (DBGI), such as IBS. Therefore, the following insights are mainly based on IBS studies, particularly those addressing severe cases[21].

Tricyclic Antidepressants (TCAs)

Twelve randomized clinical trials (RCTs) evaluated the efficacy and safety of TCAs in treating IBS patients. Of those receiving active therapy, 63.8% improved. The number needed to treat (NNT) with TCAs was 4.5 (95% CI: 3.5-7). The latest systematic reviews and meta-analyses assessed the effect of antidepressant therapy on abdominal pain[13,19]. Antidepressants were more likely to improve abdominal pain symptoms compared to placebo; however, the beneficial effects were due to TCAs, not SSRIs. TCAs also improved global symptoms in IBS patients relative to placebo (relative risk [RR]: 1.36; 95% CI: 1.07-1.71). The number needed to treat (NNT) with TCAs was 4.5 (95% CI: 3.5-7)[14]. A recent clinical guideline for managing IBS strongly recommends using TCAs for treating global IBS symptoms, with moderate-quality evidence supporting this recommendation[25].

Serotonin-Norepinephrine Reuptake Inhibitors (SNRIs)

In two cohort studies[14,26], specifically targeting patients with CAPS, a favorable response was observed with duloxetine at an initial dose of 30 mg/day for pain improvement, compared to various interventions (TCAs, opioids, gabapentin) ($p = 0.003$)[14,26].

Pregabalin

A CCT with 107 CAPS patients compared quality of life scores (PHQ-15) and pain scale scores (GAD-7). It found that patients tolerated pregabalin at a dose of 75 mg three times a day, or a combined regimen of pregabalin and pinaverium, with a greater reduction in pain compared to pinaverium bromide alone ($p = 0.0002$ vs. $p = 0.0033$)[27].

Other Agents

A prospective randomized controlled trial (RCT) was conducted to explore the short-term efficacy of the local analgesic (lidocaine) and the opioid analgesic (sufentanil) in 130 CAPS patients. Both treatments showed negative efficacy during short-term observation, with no worsening of symptoms from the opioid receptor blocker (sufentanil)[15]. Regarding the doses and side effects of the mentioned medications, see **Table 3**.

Table 3. Side Effects of Neuromodulatory Medications

Group	Medication	Side Effects
TCA	- Amitriptyline - Imipramine - Desipramine - Nortriptyline	Sedation, constipation, hypotension, dry mouth, nausea, arrhythmias, weight gain, sexual dysfunction, QT prolongation[6,8,14,15]
SSRI	- Citalopram - Escitalopram - Fluoxetine - Paroxetine - Sertraline	Agitation, diarrhea, insomnia, night sweats, headache, weight loss, sexual dysfunction, drowsiness, dry mouth, headache[14,15]
SNRI	- Duloxetine	Nausea, agitation, dizziness, sleep disturbances, fatigue, liver dysfunction[14,15]
Atypical Antipsychotics	- Quetiapine	Sedation, drowsiness, dry mouth, metabolic syndrome, cardiac arrhythmias, liver dysfunction, weight gain, diabetes[14,15]
Delta ligands	- Gabapentin - Pregabalin	Sedation, headache, dizziness, vertigo, fatigue, weight gain, peripheral edema[11,14,27]
Tetracyclic Antidepressant	- Mirtazapine	Weight gain, increased appetite, dry mouth, nausea, constipation, vomiting[6,8,14]
Antipsychotics	- Levosulpiride	Mild drowsiness[6,8]
Anxiolytics	- Buspirone	Sedation, headache, diziness[6,8]

TCAs: tricyclic antidepressants; SSRIs: selective serotonin reuptake inhibitors; SNRIs: serotonin-norepinephrine reuptake inhibitors. Adapted from: Bosman L, and colleagues. 2023[6]; Drossman DA, and colleagues. 2018[8]; Carrington EV, and colleagues. 2020[11]; Kilgallon E, and colleagues. 2019[14]; Yang H, and colleagues. 2021[15]; Xu R, and colleagues. 2023[27].

FUNCTIONAL ANORECTAL PAIN

Functional anorectal pain is classified into three types of disorders: levator ani syndrome, nonspecific functional pain, and proctalgia fugax. Their clinical differentiation is based on the duration of pain and the presence or absence of anorectal tenderness[10].

Treatment

Treatment for levator ani syndrome (LAS) typically includes electrical stimulation, biofeedback therapy (which has been shown to be more than 90% effective in improving defecation effort in the short term), and muscle relaxants such as methocarbamol, diazepam, and cyclobenzaprine. Additionally, therapies like levator ani muscle massage and sitz baths have also proven useful[10].

Therapeutic approaches in neuromodulation for levator ani syndrome and nonspecific functional anorectal pain include measures such as low-dose tricyclic antidepressants (TCAs), gabapentin, and cyclobenzaprine. However, there are no controlled clinical studies on these treatments, but TCAs are suggested for patients who also have coexisting anxiety[11].

CONCLUSIONS

After reviewing the literature for each disorder of brain-gut interaction (DBGI), clinical studies were selected (systematic reviews, CCTs, or the best available evidence in each case) to propose various therapeutic options for pain modulation and to obtain some therapeutic benefits from these types of medications in patients.

In general, it is notable that these medications are initially used in low doses, with the option to gradually increase the dose and to combine certain subgroups of medications or use them simultaneously with psychotherapy targeting gastrointestinal symptoms. However, special attention should be given to the potential side effects and drug interactions.

There is also a clear need for more CCTs in the future to obtain higher-quality evidence to support the recommendation of these medications in each case.

REFERENCES

1. Koduru P, Irani M, Quigley EMM. Definition, Pathogenesis, and Management of That Cursed Dyspepsia. Clin Gastroenterol Hepatol. 2018;16(4):467-79. https://doi.org/10.1016/j.cgh.2017.09.002
2. Miwa H, Nagahara A, Asakawa A, Arai M, Oshima T, Kasugai K, et al. Evidence-based clinical practice guidelines for functional dyspepsia 2021. J Gastroenterol. 2022;57(2):47-61. https://doi.org/10.1007/s00535-021-01843-7
3. Stanghellini V, Chan FKL, Hasler WL, Malagelada JR, Suzuki H, Tack J, et al. Gastroduodenal Disorders. Gastroenterology. 2016;150(6):1380-92. https://doi.org/10.1053/j.gastro.2016.02.011
4. Black CJ, Paine PA, Agrawal A, Aziz I, Eugenicos MP, Houghton LA, et al. British Society of Gastroenterology guidelines on the management of functional dyspepsia. Gut. 2022;71(9):1697-723. https://doi.org/10.1136/gutjnl-2022-327737
5. Moayyedi PM, Lacy BE, Andrews CN, Enns RA, Howden CW, Vakil N. ACG and CAG Clinical Guideline: Management of Dyspepsia. Am J Gastroenterol. 2017;112(7):988-1013. https://doi.org/10.1038/ajg.2017.154
6. Bosman L, Wauters L, Vanuytsel T. Neuromodulating agents in functional dyspepsia: a comprehensive review. Acta Gastroenterol Belg. 2023;86(1):49-57. https://doi.org/10.51821/86.1.10998
7. Wauters L, Talley NJ, Walker MM, Tack J, Vanuytsel T. Novel concepts in the pathophysiology and treatment of functional dyspepsia. Gut. 2020;69(3):591-600. https://doi.org/10.1136/gutjnl-2019-318536
8. Drossman DA, Tack J, Ford AC, Szigethy E, Törnblom H, Van Oudenhove L. Neuromodulators for Functional Gastrointestinal Disorders (Disorders of Gut-Brain Interaction): A Rome Foundation Working Team Report. Gastroenterology. 2018;154(4):1140-1171.e1. https://doi.org/10.1053/j.gastro.2017.11.279
9. Younger J, Parkitny L, McLain D. The use of low-dose naltrexone (LDN) as a novel anti-inflammatory treatment for chronic pain. Clin Rheumatol. 2014;33(4):451-9. https://doi.org/10.1007/s10067-014-2517-2
10. Rao SSC, Bharucha AE, Chiarioni G, Felt-Bersma R, Knowles C, Malcolm A, et al. Functional Anorectal Disorders. Gastroenterology. 2016;150(6):1430-1442.e4. https://doi.org/10.1053/j.gastro.2016.02.009
11. Carrington EV, Popa SL, Chiarioni G. Proctalgia Syndromes: Update in Diagnosis and Management. Curr Gastroenterol Rep. 2020;22(7):35. https://doi.org/10.1007/s11894-020-00768-0
12. Engsbro AL, Begtrup LM, Haastrup P, Storsveen MM, Bytzer P, Kjeldsen J, et al. A positive diagnostic strategy is safe and saves endoscopies in patients with irritable bowel syndrome: A five-year follow-up of a randomized controlled trial. Neurogastroenterol Motil. 2021;33(3):e14004. https://doi.org/10.1111/nmo.14004
13. Ford AC, Lacy BE, Harris LA, Quigley EMM, Moayyedi P. Effect of Antidepressants and Psychological Therapies in Irritable Bowel Syndrome: An Updated Systematic Review and Meta-Analysis. Am J Gastroenterol. 2019;114(1):21-39. https://doi.org/10.1038/s41395-018-0222-5
14. Kilgallon E, Vasant DH, Green D, Shields PL, Hamdy S, Lal S, et al. Chronic continuous abdominal pain: evaluation of diagnostic features, iatrogenesis and drug treatments in a cohort of 103 patients. Aliment Pharmacol Ther. 2019;49(10):1282-92. https://doi.org/10.1111/apt.15241
15. Yang H, Chen H, Hu B. Evaluation of the short-term efficacy of local analgesic (lidocaine) and opioid analgesic (sufentanil) on patients with centrally mediated abdominal pain syndrome: a randomized controlled trial. Therap Adv Gastroenterol. 2021;14:17562848211021783. https://doi.org/10.1177/17562848211021783
16. Zhou W, Li X, Huang Y, Xu X, Liu Y, Wang J, et al. Comparative efficacy and acceptability of psychotropic drugs for functional dyspepsia in adults: A systematic review and network meta-analysis. Medicine. 2021;100(20):E26046. https://doi.org/10.1097/MD.0000000000026046
17. Lacy BE, Mearin F, Chang L, Chey WD, Lembo AJ, Simren M, et al. Bowel Disorders. Gastroenterology. 2016;150(6):1393-1407.e5. https://doi.org/10.1053/j.gastro.2016.02.031
18. Vasant DH, Paine PA, Black CJ, Houghton LA, Everitt HA, Corsetti M, et al. British Society of Gastroenterology guidelines on the management of irritable bowel syndrome. Gut. 2021;70(7):1214-40. https://doi.org/10.1136/gutjnl-2021-324598
19. Black CJ, Yuan Y, Selinger CP, Camilleri M, Quigley EMM, Moayyedi P, et al. Efficacy of soluble fibre, antispasmodic drugs, and gut-brain neuromodulators in irritable bowel syndrome: a systematic review and network meta-analysis. Lancet Gastroenterol Hepatol. 2020;5(2):117-31. https://doi.org/10.1016/S2468-1253(19)30324-3
20. Black CJ, Staudacher HM, Ford AC. Efficacy of a low FODMAP diet in irritable bowel syndrome: systematic review and network meta-analysis. Gut. 2022;71(6):1117-1126. https://doi.org/10.1136/gutjnl-2021-325214
21. Keefer L, Drossman DA, Guthrie E, Simrén M, Tillisch K, Olden K, et al. Centrally Mediated Disorders of Gastrointestinal Pain. Gastroenterology. 2016;150(6):1408-19. https://doi.org/10.1053/j.gastro.2016.02.034
22. Grover M, Drossman DA. Functional abdominal pain. Curr Gastroenterol Rep. 2010;12(5):391-8. https://doi.org/10.1007/s11894-010-0125-0
23. Sperber AD, Drossman DA. Review article: The functional abdominal pain syndrome. Aliment Pharmacol Ther.

2011;33(5):514-24.
https://doi.org/10.1111/j.1365-2036.2010.04561.x
24. Drossman DA. 2012 David Sun lecture: helping your patient by helping yourself--how to improve the patient-physician relationship by optimizing communication skills. Am J Gastroenterol. 2013;108(4):521-8.
https://doi.org/10.1038/ajg.2013.56
25. Lacy BE, Pimentel M, Brenner DM, Chey WD, Keefer LA, Long MD, et al. ACG Clinical Guideline: Management of Irritable Bowel Syndrome. Am J Gastroenterol. 2021;116(1):17-44.
https://doi.org/10.14309/ajg.0000000000001036
26. Tang Y, Song J, Zhu Y, Chen H, Yao W, Zou D. Analysis of clinical characteristics of centrally mediated abdominal pain syndrome, exploration of diagnostic markers and its relationship with the efficacy of duloxetine treatment. Medicine. 2022;101(48):E32134.
https://doi.org/10.1097/MD.0000000000032134
27. Xu R, Wang Y, Han W. Randomized clinical trial: the effects of pregabalin for centrally mediated abdominal pain syndrome. Therap Adv Gastroenterol. 2023;16:175628482311523.
https://doi.org/10.1177/17562848231152334

https://doi.org/10.22516/25007440.1129

Case report

Chronic Digestive Bleeding Caused by Hookworms Diagnosed via Capsule Endoscopy: Case Report

César Pastás-Navarrete,[1] Fredy A. Pazmiño.[2*]

OPEN ACCESS

Citation:
Pastás-Navarrete C, Pazmiño FA. Chronic Digestive Bleeding Caused by Hookworms Diagnosed via Capsule Endoscopy: Case Report. Revista. colomb. Gastroenterol. 2024;39(3):310-317.
https://doi.org/10.22516/25007440.1129

[1] Department of Surgical Sciences, School of Health Sciences, Universidad del Cauca. Popayán, Colombia.
[2] Department of Public Health, Medical School, Universidad Nacional de Colombia. Bogotá, Colombia.

***Correspondence:** Fredy A. Pazmiño.
fapazmino@unal.edu.co

Received: 30/09/2023
Accepted: 05/02/2024

Abstract

Hookworm infections can lead to iron deficiency anemia, and in rare cases, severe life-threatening anemia. This case presents a 38-year-old male patient who consulted due to melena, asthenia, adynamia, dizziness, blurred vision, precordial pain, and shortness of breath with minimal exertion. The evaluation indicated that the patient had severe iron deficiency anemia with hemodynamic instability, but upper digestive endoscopy and colonoscopy were normal. Capsule endoscopy revealed multiple hookworms in the jejunum, which were the cause of the chronic intestinal bleeding. The patient was treated with albendazole for five days and received a repeat dose at 21 days. This case highlights that hookworms should be considered in the differential diagnosis for patients with obscure digestive bleeding from rural areas.

Keywords

Hookworm, *Ancylostoma duodenale*, *Necator americanus*, Anemia, Capsule Endoscopy.

INTRODUCTION

Hookworms are parasitic nematodes belonging to the family *Ancylostomatidae*, which includes two main genera: *Necator americanus* and *Ancylostoma duodenale*[(1)]. The hookworm life cycle consists of five larval stages (L1 to L5), beginning with the unembryonated eggs being shed in the soil. There, the eggs become fertile and eventually hatch into larvae, undergoing several developmental stages until they become infective adults. One or two days after the eggs embryonate, they release rhabditiform larvae, which are not yet infective. These larvae undergo two molts (L1 and L2) before transforming into infective filariform larvae (L3), which can survive in favorable environmental conditions for three to four weeks. Infection occurs when human skin, usually on bare feet, hands, buttocks, or back, comes into contact with soil contaminated by the infective larvae. The larvae penetrate the skin and enter the bloodstream through the capillaries. From there, they are passively transported to the right chambers of the heart and then to the pulmonary vasculature, where they cross into the alveoli. Once in the lungs, the L3 larvae exit the alveoli and migrate up the bronchial tree, ascending to the pharynx, where they are swallowed. They then enter the gastrointestinal tract, eventually reaching the small intestine, where they complete their migration. Once in the small intestine, the larvae undergo two additional molts (L4 and L5) and use their teeth or cutting plates to lacerate the mucosa and

© 2024 Asociación Colombiana de Gastroenterología

anchor themselves, facilitating feeding while preventing expulsion by intestinal peristalsis. As they begin to feed on blood, the juvenile parasites mature into adult hookworms (L5), which can live for many years in the small intestine of their human hosts[1,2].

Morphologically, *N. americanus* has a pair of cutting plates in its buccal capsule, while *A. duodenale* has a pair of fangs that it uses to attach to the mucosa of the small intestine for feeding. Mucosal injury causes inflammation and bleeding, and the resulting blood loss can lead to iron deficiency anemia in individuals hosting moderate to high numbers of adult parasites[1]. The adult parasite measures between 5 and 13 mm, and both species cause bleeding. However, it has been shown that *A. duodenale* is responsible for a blood loss 10 times greater than that caused by *N. americanus*[2]. The greatest blood loss occurs around the site where the parasite attaches to the host's mucosa. The parasite secretes anticoagulant substances that inhibit factors XIa, VIIa, and tissue factor, disrupting hemostasis at the site of injury[3]. It is estimated that *N. americanus* can cause a blood loss of 0.03 to 0.04 mL/day, and 25 adult parasites can lead to a blood loss of 1 mL/day, while *A. duodenale* can cause a blood loss of 0.15 to 0.20 mL/day, with just 5 adult parasites causing a loss of 1 mL/day of blood[4].

The prevalence of hookworm infection is influenced by environmental, socioeconomic, and personal factors[5]. It is estimated that approximately 500 million people worldwide, living in tropical regions, are infected with hookworms, causing more than 4 million disability-adjusted life years (DALYs). Additionally, hookworm infection represents an economic burden, with estimated losses exceeding USD 130 billion annually[1,6]. In Colombia, the prevalence of hookworm infection among children has been estimated at 6.4%. In the biogeographical province of Chocó-Magdalena, which includes the department of Cauca, the prevalence of hookworms was estimated at 9.8%, second only to the department of Amazonas, which had the highest prevalence at 35.7%[7]. In the indigenous population of the department of Cesar, a prevalence of 18% for *N. americanus* was reported, while in Córdoba, 22.5% of the subjects studied were found to be infected with hookworms[8,9].

Symptoms associated with hookworm infection can include cutaneous manifestations, pulmonary symptoms (Loeffler's syndrome due to the L3 larval stage), abdominal pain, nausea, iron deficiency anemia, malnutrition, and anasarca due to plasma hypoproteinemia[5]. Hookworm disease is treatable, and recovery is complete. Diagnosis is traditionally made by detecting eggs in stool samples or through molecular methods[1]. Below, we present a case of intestinal bleeding and severe anemia caused by hookworms, diagnosed via capsule endoscopy in Colombia.

CLINICAL CASE

This is the case of a 38-year-old male patient from Boca Grande, López de Micay, Cauca, Colombia, with a history of weekend binge drinking, smoking, and having undergone a thoracotomy and laparotomy five years ago due to a gunshot wound. He sought care at a Level I health center after experiencing a one-month history of gastrointestinal bleeding, characterized by melena with occasional rectal bleeding, along with asthenia, adynamia, objective vertigo, blurred vision, precordial pain, and shortness of breath with mild exertion, which worsened in the last three days. Upon initial evaluation, his hemoglobin (Hb) was found to be 2.8 g/dL, and based on his symptoms, the working diagnosis was gastrointestinal hemorrhage. He was treated with intravenous fluids and tranexamic acid and was urgently referred to a higher-level care facility for further management.

Upon admission to the Level III health center, the patient was in fair general condition. He denied abdominal pain, chest pain, or difficulty breathing. On physical examination, his skin was pale, and his oral and conjunctival mucosa were pale and dry. A digital rectal exam revealed black material on the glove, suggestive of melena, without pain or masses. His vital signs were as follows: blood pressure: 80/40 mm Hg, heart rate: 90 beats per minute (bpm), respiratory rate: 16 breaths per minute, temperature: 36.0 °C, ambient oxygen saturation: 90%, glucose: 109 mg/dL, Glasgow Coma Scale: 15/15. The patient weighed 69 kg and was 1.60 meters tall. Laboratory results showed the following: hemoglobin (Hb): 2.5 g/dL (normal range: 13.6-17.5), hematocrit: 8.9% (39.5-50.3), reticulocytes: 2.43%, white blood cells: 3,700/µL (4,000-11,200), neutrophils: 2,600/µL (1,800-6,400), lymphocytes: 600/µL (1,300-3,500), eosinophils: 100/µL (100-500), mean corpuscular volume (MCV): 52.1 fL (80.7-95.5), mean corpuscular hemoglobin concentration (MCHC): 27.9 g/dL (32.5-35.2), platelets: 391,000/µL (159,000-388,000), prothrombin time (PT): 15.2 seconds, partial thromboplastin time (PTT): 33.6 seconds, international normalized ratio (INR): 1.36, and albumin: 3.51 g/dL. Electrolytes, renal function, and liver function were within normal limits. Given the patient's hemodynamic state and low hemoglobin level, treatment for hypotension and gastrointestinal bleeding was initiated. This included 1000 mL of Hartmann's solution followed by an infusion at 80 mL/h, intravenous omeprazole 80 mg followed by 40 mg IV every 12 hours, 1 g IV tranexamic acid, 10% calcium gluconate IV every eight hours, and due to severe anemia, three units of emergency packed red blood cells were transfused.

The patient was evaluated by the general surgery team, and it was initially considered to perform an upper gas-

trointestinal endoscopy (UGIE). The exploration, up to the second portion of the duodenum, revealed chronic antral gastritis and pale gastric mucosa, without evidence of recent or old bleeding. Given the negative results from the first UGIE, a total colonoscopy was considered to explore the lower digestive tract. The colonoscopy findings included nonspecific colitis, possibly of infectious origin, and grade I hemorrhoids, with no evidence of bleeding lesions. Treatment was initiated with metronidazole 500 mg IV every eight hours, ciprofloxacin 500 mg orally (PO) every 12 hours, and mesalazine 500 mg PO every eight hours. During the hospital stay (10 days) and until the definitive diagnosis of the cause of the bleeding was made, the patient received three transfusions of packed red blood cells (**Table 1**). Following the institutional protocol, a second UGIE was performed, which was negative for bleeding lesions up to the second portion of the duodenum. Additionally, stool tests and Wright's stain were negative for the presence of eggs and blood parasites, respectively. Since the cause of the intestinal bleeding remained unidentified, exploration of the small intestine via capsule endoscopy was considered.

After bowel preparation with a laxative, a capsule endoscopy was performed, revealing the presence of a significant number of cylindrical worms in the small intestine, mostly located in the proximal jejunum. No parasites were identified in the duodenum. The worms were either dark red or light red in color, and some were anchored to the intestinal wall (**Figures 1-4**). The rest of the examination was normal, with no active bleeding lesions documented in the intestinal mucosa. Based on the macroscopic morphological characteristics of the parasites, their location, and the patient's symptoms, the parasites were identified as hookworms. With this finding, and given the patient's favorable clinical evolution, including hemodynamic stability, stable hemoglobin levels, the absence of new episodes of gastrointestinal bleeding, and no further need for blood transfusions, the patient was discharged with outpatient management. He was prescribed albendazole 400 mg/day for five consecutive days, with a recommendation to repeat the dose after 21 days. Additionally, esomeprazole 40 mg/day was prescribed for 60 days, and follow-up was arranged via outpatient service.

DISCUSSION

Hookworms were first described and classified in 1838 by Italian physician Angelo Dubini, who discovered these parasites in the small intestine during an autopsy[10]. Since then, hookworms have been a growing focus of interest due to their negative impact on human health. This parasite, also referred to as *ancylostomiasis*, belong to the nematode fam-

Table 1. Hemoglobin levels and results of endoscopic studies performed on the patient with severe anemia syndrome

Date	Transfused Blood Products	Hb Level	Blood Pressure (mm Hg)	Digestive Exploration
14/12/2022	Three PRBC units	2.5 g/dL (at admission)	80/40	First UGIE: chronic antral and corporal gastritis, negative for bleeding
15/12/2022		5.0 g/dL	110/75	
16/12/2022 AM.	Two PRBC units Four FFP units	6.7 g/dL	116/73	Total colonoscopy: colitis of possible infectious origin, grade I hemorrhoids, negative for lower gastrointestinal bleeding
16/12/2022 PM.	1 PRBC unit	6.9 g/dL	118/75	
17/12/2022		8.0 g/dL	114/78	Second UGIE: chronic antral and corporal gastritis, negative for bleeding
19/12/2022		8.1 g/dL	120/88	
20/12/2022		9.2 g/dL	136/89	Capsule endoscopy: severe nematode infestation of the small intestine suggestive of hookworms, no signs of bleeding or other lesions
21/12/2022		8.8 g/dL	118/78	
22/12/2022		8.9 g/dL	115/68	
23/12/2022		8.9 g/dL (discharge)	123/78	

UGIE: upper gastrointestinal endoscopy; PRBC: packed red blood cells; FFP: fresh frozen plasma. Author's own research.



Figure 1. Capsule endoscopy shows red worms in the jejunum. Author's File.



Figure 2. Capsule endoscopy identified hookworms in the patient's small intestine. Author's File.

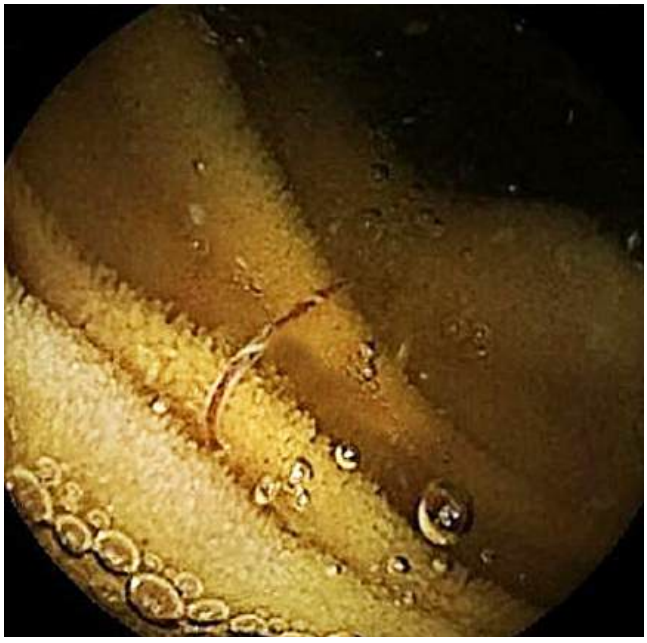

Figure 3. Another image from the capsule endoscopy showing a hookworm in the patient's small intestine. Author's File.



Figure 4. Hookworm in the mucosa of the patient's small intestine. Author's File.

ily *Ancylostomatidae*, with the most representative species being *A. duodenale*, *N. americanus*, *Ancylostoma caninum*, and *Ancylostoma braziliense*. All of these species can cause disease in humans; however, *A. caninum* and *A. braziliense* also affect dogs and cats, respectively, and represent zoonotic infections in humans, where filariform larvae penetrate the skin and cause cutaneous larva migrans syndrome[1].

The primary hookworms that affect humans are *A. duodenale* and *N. americanus*. Transmission occurs through skin contact with contaminated soil, and environmental

and socioeconomic factors, such as improper fecal waste management, humid environments, warm temperatures, and outdoor activities performed barefoot, facilitate the transmission of these parasites[1]. Additionally, socioeconomic conditions such as poverty, poor water quality, and inadequate sanitation contribute to the transmission and prevalence of this geohelminthiasis, which is widespread and most common in tropical and subtropical regions[2,11].

Once the filariform larvae penetrate the skin, they migrate, and the adult parasites settle in the host's small intestine, where they damage the intestinal mucosa. As a defense mechanism, the human body mounts a robust immune response against the parasites, driven by T_h2 cells and immunoglobulin E (IgE) antibodies. However, despite this immune response, a significant number of parasites survive and persist in the human host for years[1,12]. In the intestinal mucosa, hookworms feed on the host's blood, leading to iron deficiency anemia. Experimentally, hookworms' ability to cause anemia has been demonstrated by infecting 10 healthy subjects with a gelatin capsule containing 150 *A. duodenale* larvae in the L3 stage. A decrease in hemoglobin (Hb) levels was observed, dropping from an average pre-infection Hb of 13 g/dL (range: 12-15 g/dL) to a post-infection average of 10.4 g/dL (range: 9.8-11 g/dL) over three months[10,13]. Additionally, the severity of anemia has been shown to depend on the type of infecting parasite, with infection by *A. duodenale* resulting in greater blood loss than that caused by *N. americanus*[5,14].

On the one hand, most individuals infected with hookworms present with chronic, asymptomatic occult gastrointestinal bleeding; however, in rare cases, they can cause acute anemia[15,16]. Hookworm infections are often overlooked or misdiagnosed, making it essential to consider these parasites in the differential diagnosis of anemia and acute or chronic gastrointestinal bleeding, particularly in patients with risk factors who come from rural areas of tropical developing countries[1,17,18]. Additionally, hookworms can also lead to hypoalbuminemia, elevated IgE levels, and eosinophilia[1]. In the present case, eosinophilia and hypoalbuminemia were not identified, but the patient did present with microcytic hypochromic anemia. Eosinophilia in hookworm infection is typically detected within the first 20 to 30 days post-infection, peaking between 6 and 12 weeks, and then gradually returning to normal levels[1,13]. The absence of eosinophilia in this case may suggest a chronic hookworm infection.

On the other hand, upper gastrointestinal bleeding, which includes lesions from the upper esophageal sphincter to the ligament of Treitz, is considered the most prevalent gastroenterological emergency. The incidence of upper gastrointestinal bleeding in the United States has been estimated between 50 and 172 cases per 100,000 people per year; in Spain, 34 cases per 100,000; in the United Kingdom, 72 cases per 100,000; and in Malaysia, 100 cases per 100,000. Mortality rates due to upper gastrointestinal bleeding have been estimated at 4% to 14% in China, 9% in Peru, 4% in Mexico, and between 5% and 10% in Colombia[19]. Similarly, the overall incidence of lower gastrointestinal bleeding is estimated between 33 and 87 cases per 100,000 people[20], while small intestine bleeding accounts for 5% to 10%[21]. Both upper and lower gastrointestinal bleeding can be investigated using upper gastrointestinal endoscopy (UGIE) or colonoscopy. However, exploring the small intestine has historically been challenging[21]. Fortunately, capsule endoscopy has enabled the exploration of the small intestine in cases of suspected obscure gastrointestinal bleeding, with a diagnostic yield of 50% to 60% and a negative predictive value of 90%[21,22].

In the present case, the patient presented with obscure gastrointestinal bleeding, suggesting a source from the upper or middle intestine. However, UGIE ruled out bleeding lesions in the upper intestine, and the colonoscopy did not reveal any active bleeding lesions in the colon but did report the presence of grade I hemorrhoids, which could explain the episodes of rectal bleeding reported by the patient.

On the other hand, stool examination is the most commonly used method for diagnosing hookworms; however, the sensitivity of this method using Kato-Katz and formalin-ether concentration techniques is 68.4% (95% confidence interval [CI]: 56.6-78.3) and 38.2% (95% CI: 27.5-50.1), respectively, indicating low sensitivity[23]. In Colombia, the sensitivity of the Kato-Katz method for hookworms has been estimated at 73%[24]. Several case reports describe the diagnosis of intestinal hookworms via capsule endoscopy; however, to date, no such reports have been published in Colombia (**Table 2**). In two of these cases, stool tests were positive for eggs, and in two other cases, no stool tests were mentioned. However, in all cases, capsule endoscopy demonstrated the presence of hookworms in the intestine, and in four cases, the stool test results were negative for hookworm eggs, as was the case in the present report. These data suggest that the sensitivity of stool tests for hookworms does not exceed 80% and indicate that capsule endoscopy may provide a complementary method for diagnosing hookworm infections[15,24,25].

Hookworm disease is treatable, and recovery is complete. The two most widely used medications are albendazole and mebendazole, both of which are benzimidazoles. These drugs are broad-spectrum anthelmintics that work by inhibiting microtubule polymerization through binding to β-tubulin in invertebrates, effectively killing adult worms[1]. A single dose of 400 mg albendazole is more

Table 2. Clinical characteristics and test results of patients with hookworms diagnosed via capsule endoscopy

Author	Clinical Characteristics	UGIE	Colonoscopy	Capsule Endoscopy Findings	Presence of Hookworm Eggs in Stool
Wu, 2007[26]	39-year-old man with watery diarrhea	Not performed	Hookworms in the ascending colon	Hookworms in the stomach, duodenum, and jejunum	Positive
Kalli, 2011[27]	22-year-old man with severe iron deficiency anemia	Normal	Normal	Hookworms in the proximal small intestine, slight bleeding at parasite attachment site	Negative
Seidelman, 2015[25]	63-year-old man with generalized weakness, loss of appetite, iron deficiency anemia	Mild non-erosive gastritis	Internal hemorrhoids grade I, melena	Hookworms in the mid-jejunum	NR
Coton, 2017[28]	43-year-old man with unexplained iron deficiency anemia	Normal	Normal	Duodenal bleeding, linear jejunal ulcer, hookworms	Negative
Tan, 2017[15]	46-year-old man with acute hematochezia	Hookworms in the duodenum	Normal	Fresh bleeding in the jejunum, hookworms in the jejunum	NR
Meng, 2018[29]	46-year-old man with acute hematochezia	Hookworms in the duodenum	Normal	Hookworms in the jejunum, active bleeding, blood clots	Negative
Chergui, 2021[30]	34-year-old man with severe iron deficiency anemia	Normal	Normal	Hookworms in the proximal small intestine	Positive
Li, 2023[17]	72-year-old man with chronic anemia and black stools	Chronic superficial gastritis, hiatal hernia	Internal hemorrhoids	Eroded jejunal mucosa with minimal bleeding, hookworms in the jejunum	Negative**
Present case	38-year-old man with severe iron deficiency anemia	Chronic antral gastritis	Grade I hemorrhoids, nonspecific colitis	Hookworms in the jejunum	Negative

*The patient underwent several stool tests, all of which were negative. **Hookworm eggs detected using FA160 automatic analyzer. NR: not reported. Adapted from: Tan X, and colleagues. 2017[15]; Li B, and colleagues. 2023[17]; Seidelman J, and colleagues. 2016[25]; Wu IC, and colleagues. 2007[26]; Kalli T, and colleagues. 2011[27]; Coton T, and colleagues. 2018[28]; Meng Y, and colleagues. 2018[29]; Chergui H, and colleagues. 2021[30].

effective than a single 500 mg dose of mebendazole. A systematic review and meta-analysis reported that a single dose of albendazole has a cure rate of 72% (95% CI: 59-81), while a single dose of mebendazole has a cure rate of only 15% (95% CI: 1-27)[31]. Similarly, a study involving 1,834 school-aged children from several countries showed an overall cure rate for hookworm infection of 87.8% with a single dose of albendazole[32]. Additionally, three consecutive daily doses of albendazole achieved a 92% cure rate (95% CI: 80.8-97.8), compared to 58.5% (95% CI: 45.6-70.6) for mebendazole[33]. In this case, the decision was made to prescribe five consecutive days of treatment with albendazole and to repeat a 400 mg dose at 21 days to improve the cure rate.

CONCLUSION

In patients from rural areas with a high prevalence of geohelminthiasis who present with acute or chronic gastrointestinal bleeding and show evidence of iron deficiency anemia, hookworm infection should be considered in the differential diagnosis. Capsule endoscopy can help identify the cause of gastrointestinal bleeding and rule out intestinal parasitic disease.

Conflict of Interest

The authors report no conflicts of interest in relation to this article.

REFERENCES

1. Loukas A, Hotez PJ, Diemert D, Yazdanbakhsh M, McCarthy JS, Correa-Oliveira R, et al. Hookworm infection. Nat Rev Dis Primers. 2016;2:16088. https://doi.org/10.1038/nrdp.2016.88
2. Jourdan PM, Lamberton PHL, Fenwick A, Addiss DG. Soil-transmitted helminth infections. Lancet. 2018;391(10117):252-265. https://doi.org/10.1016/S0140-6736(17)31930-X
3. Stanssenst P, Bergumt PW, Gansemanst Y, Jesperst L, Larochet Y, Huangt S, et al. Anticoagulant repertoire of the hookworm Ancylostoma caninum. Proc Natl Acad Sci USA. 1996;93(5):2149-2154. https://doi.org/10.1073/pnas.93.5.2149
4. Crompton DWT. The public health importance of hookworm disease. Parasitology. 2000:121 Suppl:S39-50. https://doi.org/10.1017/S0031182000006454
5. Hotez PJ, Brooker S, Phil D, Bethony JM, Bottazzi ME, Loukas A, et al. Hookworm Infection. N Engl J Med. 2004;351(8):799-807. https://doi.org/10.1056/NEJMra032492
6. Bartsch SM, Hotez PJ, Asti L, Zapf KM, Bottazzi ME, Diemert DJ, et al. The Global Economic and Health Burden of Human Hookworm Infection. PLoS Negl Trop Dis. 2016;10(9):e0004922. https://doi.org/10.1371/journal.pntd.0004922
7. Quiroz DJG, Lopez SDPA, Arango CM, Acosta JEO, Parias LDB, Alzate LU, et al. Prevalence of soil transmitted helminths in school-aged children, Colombia, 2012-2013. PLoS Negl Trop Dis. 2020;14(7):e0007613. https://doi.org/10.1371/journal.pntd.0007613
8. Kann S, Bruennert D, Hansen J, Mendoza GAC, Gonzalez JJC, Quintero CLA, et al. High prevalence of intestinal pathogens in indigenous in Colombia. J Clin Med. 2020;9(9):2786. https://doi.org/10.3390/jcm9092786
9. Fernández-Niño JA, Idrovo AJ, Cucunubá ZM, Reyes-Harker P, Guerra ÁP, Moncada LI, et al. Paradoxical associations between soil-transmitted helminths and Plasmodium falciparum infection. Trans R Soc Trop Med Hyg. 2012;106(11):701-708. https://doi.org/10.1016/j.trstmh.2012.07.012
10. Chapman PR, Giacomin P, Loukas A, McCarthy JS. Experimental human hookworm infection: a narrative historical review. PLoS Negl Trop Dis. 2021;15(12):e0009908. https://doi.org/10.1371/journal.pntd.0009908
11. Anegagrie M, Lanfri S, Aramendia AA, Scavuzzo CM, Herrador Z, Benito A, et al. Environmental characteristics around the household and their association with hookworm infection in rural communities from bahir dar, amhara region, Ethiopia. PLoS Negl Trop Dis. 2021;15(6):e0009466. https://doi.org/10.1371/journal.pntd.0009466
12. Cooper PJ, Ayre G, Martin C, Rizzo JA, Ponte EV, Cruz AA. Geohelminth infections: a review of the role of IgE and assessment of potential risks of anti-IgE treatment. Allergy. 2008;63(4):409-417. https://doi.org/10.1111/j.1398-9995.2007.01601.x
13. Lee M, Kim JD, Lee JK. Studies on Ancylostomiasis: 1. An Experimental Study on Hookworm Infection and Anemia. Korean J Nucl Med. 1967;1(1):55-66.
14. Albonico M, Stoltzfus RJ, Savioli L, Tielsch JM, Chwaya HM. Epidemiological evidence for a differential effect of hookworm species, Ancylostoma duodenale or Necator americanus, on iron status of children. Int J Epidemiol. 1998;27(3):530-537. https://doi.org/10.1093/ije/27.3.530
15. Tan X, Cheng M, Zhang J, Chen G, Liu D, Liu Y, et al. Hookworm infection caused acute intestinal bleeding diagnosed by capsule: A case report and literature review. Korean Journal of Parasitology. Korean J Parasitol. 2017;55(4):417-420. https://doi.org/10.3347/kjp.2017.55.4.417
16. de la Riva H, Escamilla DG, Frati AC. Acute massive intestinal bleeding caused by hookworm. JAMA. 1981;246(1):68. https://doi.org/10.1001/jama.246.1.68
17. Li B, Chen S, Cui X, Dai M, Meng W, Wu Q, et al. Chronic Hemorrhagic Anemia Caused by Hookworm Infection: A Case Report. Acta Parasitol. 2023;68(1):288-292. https://doi.org/10.1007/s11686-022-00653-y
18. Wu F, Xu Y, Xia M, Ying G, Shou Z. Hookworm Anemia in a Peritoneal Dialysis Patient in China. Korean J Parasitol. 2016;54(3):315-7. https://doi.org/10.3347/kjp.2016.54.3.315
19. Cuartas Agudelo YS, Martínez Sánchez LM, Cuartas-Agudelo YS, Martínez-Sánchez LM. Aspectos clínicos y etiológicos de la hemorragia digestiva alta y sus escalas de evaluación. MÉD UIS. 2020;33(3):9-20. https://doi.org/10.18273/revmed.v33n3-2020001
20. Sengupta N, Feuerstein JD, Jairath V, Shergill AK, Strate LL, Wong RJ, et al. Management of Patients With Acute Lower Gastrointestinal Bleeding: An Updated ACG Guideline. Am J Gastroenterol. 2023;118(2):208-231. https://doi.org/10.14309/ajg.0000000000002130
21. Van de Bruaene C, Hindryckx P, Van de Bruaene L, De Looze D. Bleeding Lesion of the Small Bowel: an Extensive Update Leaving No Stone Unturned. Curr Gastroenterol Rep. 2018;20:5. https://doi.org/10.1007/s11894-018-0610-4
22. Valdivia PC, Skonieczna-żydecka K, Elosua A, Sciberras M, Piccirelli S, Rullan M, et al. Indications, Detection, Completion and Retention Rates of Capsule Endoscopy in Two Decades of Use: A Systematic Review and Meta-Analysis. Diagnostics (Basel). 2022;12(5):1105. https://doi.org/10.3390/diagnostics12051105

23. Utzinger J, Rinaldi L, Lohourignon LK, Rohner F, Zimmermann MB, Tschannen AB, et al. FLOTAC: a new sensitive technique for the diagnosis of hookworm infections in humans. Trans R Soc Trop Med Hyg. 2008;102(1):84-90. https://doi.org/10.1016/j.trstmh.2007.09.009
24. López MC, Moncada LI, Ariza-Araújo Y, Fernández-Niño JA, Reyes P, Nicholls RS. Evaluación de tres pruebas para el diagnóstico de geohelmintos en Colombia. Biomedica. 2013;33(1):128-136. https://doi.org/10.7705/biomedica.v33i1.633
25. Seidelman J, Zuo R, Udayakumar K, Gellad ZF. Caught on Capsule: Iron-deficiency Anemia Due to Hookworm Infection. Am J Med. 2016;129(2):167-9. https://doi.org/10.1016/j.amjmed.2015.08.004
26. Wu IC, Lu CY, Wu DC. Acute hookworm infection revealed by capsule endoscopy. Endoscopy. 2007;39 Suppl 1: E306-E306. https://doi.org/10.1055/s-2007-967015
27. Kalli T, Karamanolis G, Triantafyllou K. Hookworm Infection Detected by Capsule Endoscopy in a Young Man With Iron Deficiency. Clin Gastroenterol Hepatol. 2011;9(4):e33. https://doi.org/10.1016/j.cgh.2010.10.026
28. Coton T, Massoure MP, Cottez S, Varvenne D. Human hookworm disease: Enteroscopy and video capsule endoscopy features. Clin Res Hepatol Gastroenterol. 2018;42(3):e39-e40. https://doi.org/10.1016/j.clinre.2017.11.008
29. Meng Y, Lu F, Shi L, Cheng M, Zhang J. Acute major gastrointestinal bleeding caused by hookworm infection in a patient on warfarin therapy. Medicine (Baltimore). 2018;97(11):e9975. https://doi.org/10.1097/MD.0000000000009975
30. Chergui H, Akhoundi M, Marteau A, Bejou B, Lekhal C, Deutsch D, et al. Severe iron-deficiency anaemia due to hookworm infection diagnosed by capsule endoscopy. Int J Infect Dis. 2021;104:271-272. https://doi.org/10.1016/j.ijid.2021.01.014
31. Keiser J, Utzinger J. Efficacy of current drugs against soil-transmitted helminth infections: systematic review and meta-analysis. JAMA. 2008;299(16):1937-1948. https://doi.org/10.1001/jama.299.16.1937
32. Vercruysse J, Behnke JM, Albonico M, Ame SM, Angebault C, Bethony JM, et al. Assessment of the Anthelmintic Efficacy of Albendazole in School Children in Seven Countries Where Soil-Transmitted Helminths Are Endemic. PLoS Negl Trop Dis. 2011;5(3):e948. https://doi.org/10.1371/journal.pntd.0000948
33. Steinmann P, Utzinger J, Du ZW, Jiang JY, Chen JX, Hattendorf J, et al. Efficacy of Single-Dose and Triple-Dose Albendazole and Mebendazole against Soil-Transmitted Helminths and Taenia spp.: A Randomized Controlled Trial. PLoS One. 2011;6(9):e25003. https://doi.org/10.1371/journal.pone.0025003

https://doi.org/10.22516/25007440.1029

Case report

Capillary Hemangioma of the Jejunum as a Cause of Acute Bleeding: Case Report and Literature Review

Martín Alonso Gómez-Zuleta,[1*] Diego Alexánder Cardona-Botero,[2] Juan Antonio Trejos-Naranjo,[2] Felipe Vera-Polanía.[2]

OPEN ACCESS

Citation:
Gómez-Zuleta MA, Cardona-Botero DA, Trejos-Naranjo JA, Vera-Polanía F. Capillary Hemangioma of the Jejunum as a Cause of Acute Bleeding: Case Report and Literature Review. Revista. colomb. Gastroenterol. 2024;39(3):318-322. https://doi.org/10.22516/25007440.1029

[1] Internist and Gastroenterologist, Hospital Universitario Nacional de Colombia. Associate Professor of Internal Medicine, Director of the Gastroenterology Unit, Universidad Nacional de Colombia. Bogotá, Colombia.
[2] Gastroenterology Resident, Universidad Nacional de Colombia. Bogotá, Colombia.

***Correspondence:** Martín Alonso Gómez-Zuleta.
martinalonsogomezz@gmail.com

Received: 19/02/2023
Accepted: 07/07/2023

Abstract

Bleeding from the small intestine is an uncommon cause of gastrointestinal tract bleeding. Most cases are secondary to angiodysplasias; however, they are rarely associated with hemangiomas of the small intestine, which are benign vascular neoplasms primarily diagnosed using capsule endoscopy and balloon-assisted enteroscopy in stable patients preoperatively. To date, only one case has been published with hemodynamic instability at the time of diagnosis. This report presents the case of a 21-year-old woman who presented with acute bleeding and hemorrhagic shock secondary to capillary hemangioma of the jejunum, which was diagnosed via intraoperative enteroscopy and successfully managed with surgical resection.

Keywords

Hemangioma, Bleeding, Small Intestine, Capsule Endoscopy, Balloon Enteroscopy.

INTRODUCTION

Obscure gastrointestinal bleeding, defined as bleeding without identification of the source, accounts for 10% of all cases of gastrointestinal hemorrhage. Bleeding from the small intestine is the leading cause of obscure bleeding, comprising 5%-10% of all cases of gastrointestinal tract bleeding[(1)], which includes the region between the ampulla of Vater and the ileocecal valve. Among the various lesions, vascular causes represent 70%-80% of cases, followed by tumors in 5%-10%[(2)]. Small intestinal hemangiomas are considered rare, accounting for 7%-10% of all benign small bowel tumors. The most common clinical manifestations include bleeding, abdominal pain, obstruction, intussusception, or perforation[(3)]. Bleeding is predominantly chronic, with secondary iron-deficiency anemia as the main consequence[(4)]. The use of capsule endoscopy and device-assisted enteroscopy in recent years has enabled complete evaluation of the small intestine and diagnosis of such lesions. The first-line treatment is surgical resection. We present the case of a young patient experiencing massive gastrointestinal bleeding due to a jejunal capillary hemangioma, which was diagnosed by intraoperative enteroscopy and successfully managed with surgical resection.

CASE PRESENTATION

A 21-year-old female patient with no known medical history presented with an acute episode of rectal bleeding, accompanied by abdominal pain, nausea, and general dis-

© 2024 Asociación Colombiana de Gastroenterología

comfort. Upon admission to a medical center, persistent bleeding was documented, resulting in anemia and necessitating the transfusion of four units of packed red blood cells and three units of plasma. An esophagogastroduodenoscopy was performed, revealing erythematous antral gastritis, and a total colonoscopy showed grade I internal hemorrhoids with no signs of active bleeding. However, clinically, the patient continued to experience two to three episodes of melena daily.

In preparation for a small intestine bleeding study, capsule endoscopy was planned. However, during her stay, she developed hemodynamic instability with tachycardia and hypotension, requiring stabilization and subsequent referral for angiography and embolization to control the bleeding. Upon arrival at the institution, she was hemodynamically stable and did not require vasopressor support. A second esophagogastroduodenoscopy was conducted, showing chronic erythematous gastritis and antral follicular gastritis. During follow-up, the patient once again exhibited signs of hemorrhagic shock, with ongoing profuse melena and significant anemia within less than 24 hours, with hemoglobin levels dropping from 9.7 g/dL to 3.9 g/dL. Consequently, an abdominal aortogram with selective mesenteric vessel study was performed, which was reported as normal for her age (**Figure 1**).

Due to the patient's clinical instability and the negative angiographic study, a multidisciplinary team decided to proceed with intraoperative enteroscopy. An open laparotomy was performed, identifying the ligament of Treitz, at which point an enterotomy was made, and a colonoscope was introduced. In the proximal jejunum, a pedunculated polypoid lesion was identified, measuring approximately 15 mm at the head and 10 mm at the stalk, with active bleeding observed (**Figure 2**). A hemostatic clip was placed to partially control the bleeding and facilitate the surgical resection of a 30 cm segment of the jejunum with a side-to-side anastomosis.

Pathology examination reported a well-circumscribed benign mesenchymal tumor located in the submucosa and muscularis propria, consisting of thin-walled vascular channels without atypia or mitosis, filled with abundant blood, consistent with an ulcerated capillary hemangioma (**Figures 3** and **4**). The patient showed a favorable clinical course, with no new bleeding episodes, improved hemoglobin levels, and good tolerance to oral intake, allowing for discharge. She remains asymptomatic in outpatient follow-up.

DISCUSSION

Hemangiomas account for 0.05% of all gastrointestinal tract neoplasms. They can be classified by the type of vessels involved as capillary, cavernous, or mixed types and are composed of small terminal blood vessels. Their presence in the small intestine is exceedingly rare, with only a few cases reported to date[4]. Although considered a benign

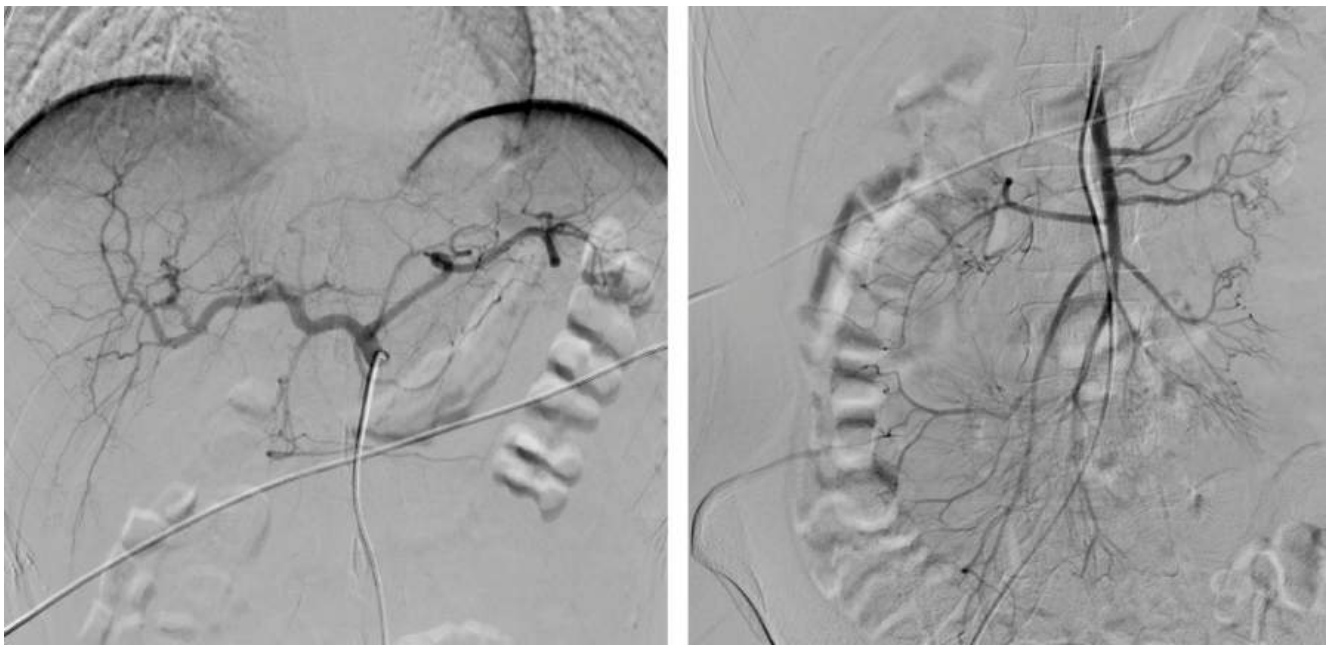

Figure 1. Abdominal aortogram and selective mesenteric vessel study within normal limits for age. Source: Author's File.

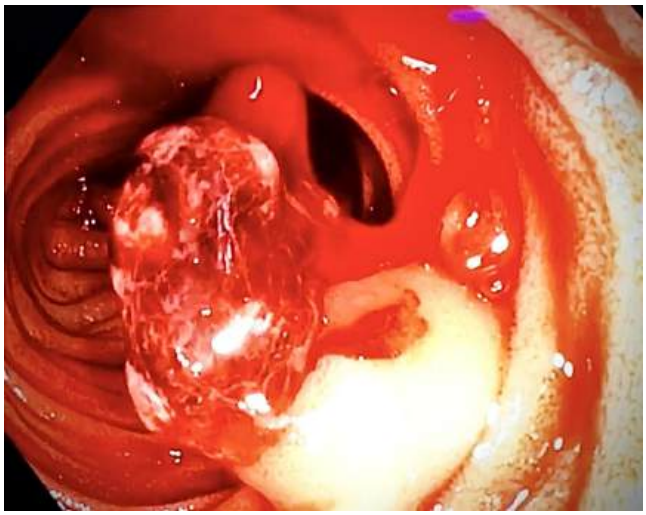

Figure 2. Intraoperative enteroscopy. Polypoid lesion in the jejunum with active bleeding. Source: Author's File.

condition, hemangiomas have the potential to cause complications, primarily chronic bleeding over time, which can lead to iron-deficiency anemia. While they can be successfully treated with surgical resection, their rarity in younger patients and their anatomical location may prevent them from being considered in differential diagnoses. Furthermore, routine examinations like computed tomography, magnetic resonance imaging, and colonoscopy often face limitations in identifying these lesions. Therefore, diagnostic studies for the small intestine, such as capsule endoscopy or double-balloon enteroscopy, have become the best tools for preoperative evaluation of lesions in the ileum and jejunum in hemodynamically stable patients[5].

In this case, due to the patient's hemodynamic instability, which necessitated transfusion support and vasopressor use, an abdominal angiography was initially performed but yielded negative results. Consequently, intraoperative enteroscopy was ordered as a last resort to determine the bleeding source and achieve prompt control, in line with current recommendations for managing small intestine bleeding[1,6,7]. Subsequently, the standard treatment of surgical resection with side-to-side anastomosis was carried out, resulting in a satisfactory postoperative course.

This case highlights the significance of intraoperative enteroscopy as a fundamental tool in managing small intestine bleeding in patients with persistent hemodynamic instability, even after a negative abdominal vessel angiography. In such cases, it should not be deferred or replaced by procedures like capsule endoscopy, as intraoperative enteroscopy not only allows diagnosis but also facilitates immediate treatment within the same procedure. In this case, intraoperative enteroscopy was preferred over capsule endoscopy due to the latter's lower sensitivity for detecting arteriovenous malformations (as low as 50%), mainly because it lacks insufflation and suction capabilities, which hinders the inspection of folds and lengthens the procedure time and result interpretation. Additionally, arteriovenous malformations can sometimes be detected through transillumination of the external surface of the intestinal wall, which is only feasible with intraoperative enteroscopy[8,9].

The histopathological study confirmed the diagnosis of capillary hemangioma of the jejunum, and this histological

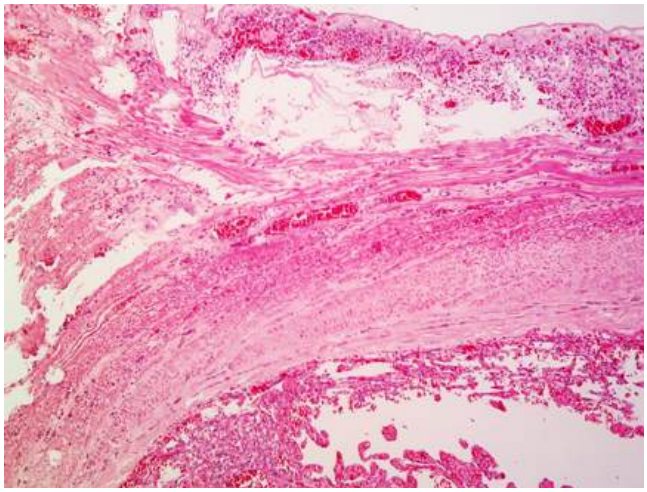

Figure 3. Capillary hemangioma of the jejunum. Hematoxylin-eosin stain, 40x. Involvement of the submucosal and muscularis propria layers. Source: Author's File.

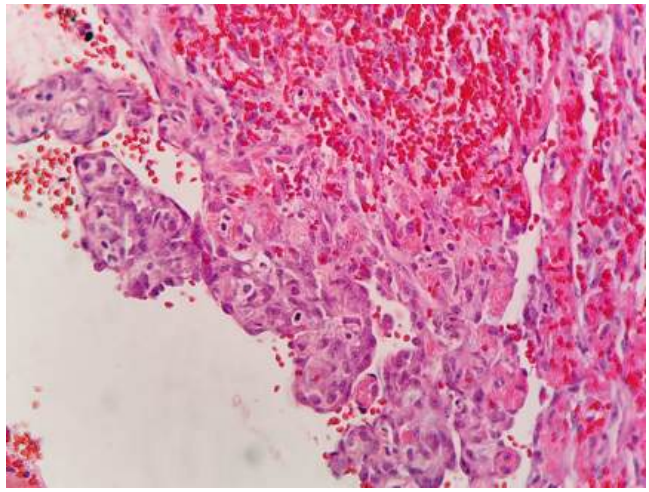

Figure 4. Capillary hemangioma of the jejunum. Hematoxylin-eosin stain, 400x. Thin-walled vascular channels with abundant blood content. Source: Author's File.

subtype is also considered particularly rare. In a study of 37 reported cases from 2000 to 2018, only three exhibited the capillary subtype, while the rest showed the cavernous subtype[3]. Additionally, diagnosis in these cases was made preoperatively using capsule endoscopy or balloon-assisted enteroscopy in hemodynamically stable patients. The most common treatment for these hemangiomas is surgical resection. However, in recent years, less invasive endoscopic therapies, such as polidocanol sclerotherapy, have shown promising results, along with other therapies like argon plasma coagulation and endoscopic mucosal resection. Nevertheless, special caution is required to prevent complications such as perforation, arterial aspiration, and puncture-related issues, especially in cases of transmural hemangiomas, as in this instance, where endoscopic therapy alone might not suffice for complete treatment of the lesion[10,11].

CONCLUSION

We report the case of a young adult patient with a solitary capillary hemangioma in the jejunum that caused acute bleeding, leading to hemorrhagic shock and necessitating intraoperative enteroscopy and jejunal surgical resection. These types of lesions pose diagnostic challenges with conventional methods like computed tomography, magnetic resonance imaging, or colonoscopy. Although capsule endoscopy and balloon enteroscopy can aid in characterizing them, in patients with persistent or recurrent hemodynamic instability, as seen in this case, intraoperative enteroscopy should be the procedure of choice, as it allows for lesion localization and urgent management. Finally, although these lesions are rare, they should be considered in the differential diagnosis of gastrointestinal bleeding originating in the small intestine, especially in young patients with massive bleeding episodes.

REFERENCES

1. ASGE Standards of Practice Committee; Gurudu SR, Bruining DH, Acosta RD, Eloubeidi MA, Faulx AL, et al. The role of endoscopy in the management of suspected small-bowel bleeding. Gastrointest Endosc. 2017;85(1):22-31. https://doi.org/10.1016/j.gie.2016.06.013
2. Iodarche F, urculeț C, Beuran M, Ene D, Gaspar B, Georgescu F, et al. Emergency Surgery for Small Bowel Hemangioma. A review of the literature. Chirurgia (Bucur). 2021;116(6):657-663. https://doi.org/10.21614/chirurgia.116.6.657
3. Hu PF, Chen H, Wang XH, Wang WJ, Su N, Shi B. Small intestinal hemangioma: Endoscopic or surgical intervention? A case report and review of literature. World J Gastrointest Oncol 2018;10(12):516-52. https://doi.org/10.4251/wjgo.v10.i12.516
4. Wang B, Lou Z, Zheng W, Zhang J, Liu J. Capillary hemangioma in the ileum: Obscure small-bowel bleeding in an elderly person. Turk J Gastroenterol. 2018;29(4):520-521. https://doi.org/10.5152/tjg.2018.17612
5. Willert RP, Chong AK. Multiple cavernous hemangiomas with iron deficiency anemia successfully treated with double-balloon enteroscopy. Gastrointest Endosc. 2008;67(4):765-7. https://doi.org/10.1016/j.gie.2007.07.044
6. Gerson LB, Fidler JL, Cave DR, Leighton JA. ACG Clinical Guideline: Diagnosis and Management of Small Bowel Bleeding. Am J Gastroenterol. 2015;110(9):1265-87. https://doi.org/10.1038/ajg.2015.246
7. Ohmiya N. Management of obscure gastrointestinal bleeding: Comparison of guidelines between Japan and other countries. Dig Endosc. 2020;32(2):204-218. https://doi.org/10.1111/den.13554
8. Lofty WE. Ali RM, Galal SM. Capsule endoscopy versus intraoperative enteroscopy in management of small bowel arteriovenous malformations. The Egyptian Journal of Surgery. 2014,33(3):171-177. https://doi.org/10.4103/1110-1121.141903
9. Abutalib H, Yano T, Shinozaki S, Lefor AK, Yamamoto H. Roles of Capsule Endoscopy and Balloon-Assisted Enteroscopy in the Optimal Management of Small Bowel Bleeding. Clin Endosc. 2020;53(4):402-409. https://doi.org/10.5946/ce.2020.143
10. Aoyama T, Fukumoto A, Shigita K, Asayama N, Mukai S, Nagata S. Successful Endoscopic Sclerotherapy Using Polidocanol for Small Bowel Hemangioma. Intern Med. 2020;59(14):1727-1730. https://doi.org/10.2169/internalmedicine.4327-19
11. Al-Tkrit A, Aneeb M, Mekaiel A, Alawawdeh F, Mehta A. Cavernous Hemangioma: A Rare Cause of Massive Lower Gastrointestinal Bleeding. Cureus. 2020;12(8):e10075. https://doi.org/10.7759/cureus.10075

https://doi.org/10.22516/25007440.1120

Case report

Case Report of Intrahepatic Cholestasis Associated with ATP8B1 Gene Mutation in a Patient with Human Immunodeficiency Virus (HIV) Infection: A Diagnostic Challenge

Darwin Jhoan Ariza-Rodríguez,[1] Valentina Dávila,[1*] Carmen Yanette Suárez-Quintero,[2] Sandra Amado-Garzón.[1]

OPEN ACCESS

Citation:
Ariza-Rodríguez DJ, Dávila V, Suárez-Quintero CY, Amado-Garzón S. Case Report of Intrahepatic Cholestasis Associated with ATP8B1 Gene Mutation in a Patient with Human Immunodeficiency Virus (HIV) Infection: A Diagnostic Challenge. Revista. colomb. Gastroenterol. 2024;39(3):323-327.
https://doi.org/10.22516/25007440.1120

[1] Specialist in Internal Medicine, Internist, Hospital Universitario San Ignacio. Bogotá, Colombia.
[2] Specialist in Internal Medicine, Gastroenterology, and Clinical Hepatology. Gastroenterologist, Hospital Universitario San Ignacio. Bogotá, Colombia.

***Correspondence:** Valentina Dávila.
v.davila@javeriana.edu.co

Received: 25/07/2023
Accepted: 24/11/2023

Abstract

Benign recurrent intrahepatic cholestasis (BRIC) is a rare condition that is part of a spectrum of disorders known as familial intrahepatic cholestasis. It is characterized by episodes of cholestasis lasting weeks to months with complete resolution between episodes. BRIC is associated with a good prognosis compared to other conditions, due to its later onset and lower association with fibrosis. Diagnosis is one of exclusion, posing a diagnostic challenge that requires a high index of suspicion and is confirmed by identifying the ATP8B1 gene mutation.

This report presents the case of a patient with human immunodeficiency virus (HIV) who developed severe intrahepatic cholestasis and had a history of recurrent jaundice throughout his life. After extensive studies of intrahepatic cholestasis, he was diagnosed with symptomatic BRIC with the ATP8B1 gene mutation.

Keywords

Jaundice, intrahepatic cholestasis, mutation.

INTRODUCTION

Familial intrahepatic cholestasis is a group of heterogeneous disorders characterized by impaired bile secretion by hepatocytes due to mutations in genes encoding proteins expressed on the apical membrane of hepatocytes. These disorders include progressive familial intrahepatic cholestasis (PFIC) and benign recurrent intrahepatic cholestasis (BRIC). PFIC has four types, and BRIC has two types, each distinguished by the specific gene mutation involved, the age of onset of cholestatic manifestations, prognosis, and risk of progression to cirrhosis or hepatocellular carcinoma[1,2].

PFIC has an incidence of approximately one in 50,000 to one in 100,000 individuals per year[3,4] and is marked by persistent early-onset cholestasis that advances to cirrhosis and end-stage liver disease in childhood[5]. BRIC, on the other hand, is characterized by episodes of cholestasis lasting from weeks to months, followed by complete resolution between episodes[6,7]. It has a favorable prognosis and, unlike PFIC, typically presents at later ages and usually does not progress to fibrosis[8]. However, there have been

reports of BRIC progressing to PFIC, suggesting that both conditions are part of a spectrum[9,10].

The ATP8B1 gene mutation, located on chromosome 18q21, is responsible for causing both PFIC type 1 and BRIC type 1[11]. The ATP8B1 gene encodes the FIC1 protein, a P-type adenosine triphosphatase (ATPase) located on the canalicular membrane and cholangiocytes. This protein functions by coupling ATP hydrolysis to the translocation of aminophospholipids, thereby maintaining phospholipid asymmetry across membranes, including the bile canalicular membrane. Its defect disrupts membrane structure and associated membrane proteins, such as the bile salt export pump[12].

This case report presents a clinical instance of BRIC in a 63-year-old patient with a history of human immunodeficiency virus (HIV) infection, experiencing recurrent episodes of intrahepatic cholestasis. After an extensive evaluation ruling out other causes, the diagnosis was reached.

CLINICAL CASE

The patient is a 63-year-old male with a 20-year history of HIV infection, managed with dolutegravir and emtricitabine/tenofovir, showing good adherence and immunovirological control. He presented with a two-month history of jaundice that began on the chest and subsequently became generalized, accompanied by asthenia, adynamia, generalized nocturnal pruritus, acholia, dark urine, and an unintentional weight loss of 5 kg over the past two months. Systemic review revealed recurrent episodes of jaundice since he was 18 years old and a family history of two brothers with similar symptoms.

On physical examination, generalized jaundice was noted, with no other significant findings. Admission laboratory tests indicated elevated alkaline phosphatase, transaminase levels two to four times the upper limit, marked hyperbilirubinemia with a predominance of direct bilirubin, hypoalbuminemia, and a prolonged international normalized ratio (INR) (**Table 1**). Baseline laboratory tests from two months prior had been normal. A hepatobiliary ultrasound showed no dilatation of the extrahepatic bile duct or choledocholithiasis. Given the severe cholestasis, further imaging with magnetic resonance cholangiography was performed, which also showed no obstructions. Additional tests were conducted to rule out infectious hepatitis (hepatitis B surface antigen [HBsAg], hepatitis B core antigen [HBcAg], hepatitis C antibodies [anti-HCV], cytomegalovirus [CMV], Epstein-Barr virus [EBV], rapid plasma reagin [RPR], and HIV), all of which were negative, as well as autoimmune disease markers (antinuclear antibodies [ANA], anti-mitochondrial antibodies [AMA], and anti-smooth muscle antibodies [ASMA], all negative). A consultation with infectious disease specialists considered the possibility of antiretroviral therapy (ART)-associated hepatotoxicity, but this was ruled out due to the lack of improvement following medication discontinuation and the history of jaundice episodes predating ART initiation.

A percutaneous liver biopsy was performed, revealing severe, predominantly intracanalicular cholestasis located pericentrally (soft cholestasis), with mild portal inflammation, and no evidence of necroinflammatory disease or autoimmune hepatitis. This finding suggested a cholestasis of possible genetic origin, which was confirmed by the detection of an ATP8B1 gene mutation.

Table 1. Relevant Laboratory Findings

Laboratory Tests	Admission	Follow-Up	Reference Range
Alkaline phosphatase	506 U/L	250 U/L	30-120 U/L
Total bilirubin	42.9 mg/dL	1.4 mg/dL	0.3-1 mg/dL
Direct bilirubin	26.2 mg/dL	0.8 mg/dL	0-0.2 mg/dL
Indirect bilirubin	16.7 mg/dL	0.6 mg/dL	0-1.1 mg/dL
GGT	168 U/L	113 U/L	12-73 U/L
Albumin	3.0 g/dL	4.3 mg/dL	4.2-5.5 g/dL
AST	124 U/L	51 U/L	0-50 U/L
ALT	70 U/L	38 U/L	0-50 U/L
INR	2.33	1.6	0.8-1.2

ALT: alanine aminotransferase; AST: aspartate aminotransferase; GGT: γ-glutamyltransferase; INR: international normalized ratio. Author's own research.

Given the clinical presentation and absence of cirrhosis, a diagnosis of benign recurrent intrahepatic cholestasis (BRIC) was established. The patient received symptomatic treatment for pruritus with topical betamethasone and loratadine, as well as ursodeoxycholic acid at a dose of 1,200 mg/day. At a follow-up 20 months later, marked reduction in bilirubin levels was observed (**Figure 1**), along with normalization of other liver function tests.

DISCUSSION

Intrahepatic cholestasis is characterized by impaired bile production and excretion, leading to accumulation of bile pigments in the skin, sclerae, and mucous membranes, resulting in jaundice and pruritus[3]. A group of autosomal recessive familial disorders exhibit intrahepatic cholestasis, with ATP8B gene mutations implicated in their pathogenesis.

This report presents a case of BRIC in a patient whose diagnostic challenge stemmed from other possible causes of liver profile abnormalities due to a history of HIV infection and the use of antiretroviral drugs associated with hepatotoxicity. This is the first reported case of BRIC in a patient with HIV.

BRIC typically manifests at later ages (in contrast to PFIC, which begins in childhood), presents with recurrent jaundice episodes, and follows a benign course without fibrosis; however, there is a risk of progression to PFIC. **Table 2** provides a comparative overview of these two conditions. In this case, liver biopsy showed no fibrosis but did reveal severe, predominantly intracanalicular cholestasis with mild portal inflammation, characteristic of BRIC[13].

The distinctive laboratory characteristics of cholestatic episodes in patients with BRIC1, BRIC2, PFIC1, and PFIC2 include elevated total and direct bilirubin, normal or slightly elevated serum γ-glutamyltransferase (GGT) (in PFIC3, GGT is markedly elevated), elevated alkaline phosphatase, and ALT and AST levels that are normal or moderately elevated[6].

In the presented case, although the GGT level was elevated, it showed only a minimal increase, less than twice the upper limit of normal. A review by Velimir and colleagues reported a BRIC patient with minimal GGT elevation[13].

The diagnosis of BRIC is based on the diagnostic criteria proposed by Luketic and Shiffman[13], which include at least two jaundice episodes separated by intervals ranging from weeks to years without any symptoms, laboratory findings consistent with intrahepatic cholestasis, normal or minimally elevated GGT, severe pruritus due to cholestasis, histology showing centrilobular cholestasis, normal intra- and extrahepatic bile ducts on cholangiography, and the

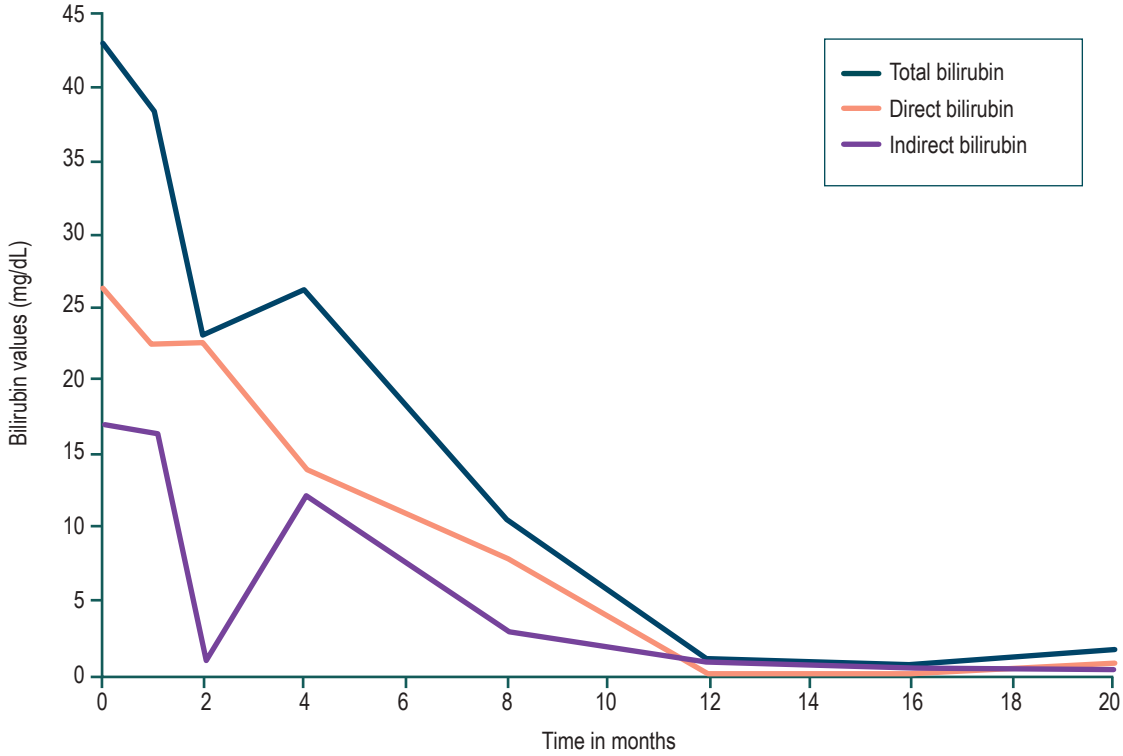

Figure 1. Bilirubin levels over time. Author's own research.

Table 2. Comparison between Progressive Familial Intrahepatic Cholestasis (PFIC) and Benign Recurrent Intrahepatic Cholestasis (BRIC)

Characteristics	PFIC	BRIC
Condition type	Progressive	Recurrent
Severity	Progression to fibrosis	Lower risk of fibrosis
Symptoms	Intense pruritus, jaundice, liver failure	Jaundice, milder pruritus
Age of onset	Childhood	Early adulthood or adolescence
Genetic mutations	ATP8B1, ABCB11, ABCB4, TJP2	ATP8B1, ABCB11
Treatment response	May require liver transplant	Medical management; symptoms may improve over time

Author's own research.

exclusion of other causes of cholestasis, such as extrahepatic cholestasis, primary biliary cirrhosis, primary sclerosing cholangitis, viral or toxic hepatitis, infiltrative diseases, and malignancy. As mentioned, the diagnosis is confirmed by identifying an ATP8B1 gene mutation[6].

Management of the disease is symptomatic, aimed at pruritus control. Various medications have been tried, including ursodeoxycholic acid, cholestyramine, rifampicin, and antihistamines, providing symptomatic relief but with no effect on preventing recurrent jaundice episodes[14].

The diagnosis of BRIC1 is by exclusion and confirmed through genetic testing. In our patient, other causes of cholestasis and liver dysfunction were reasonably ruled out, and a history of similar episodes since age 18 led to the expansion of diagnostic testing to include genetic causes. High clinical suspicion and careful discernment are required, as in this case, particularly due to the concurrent use of medications with a high risk of hepatotoxicity.

CONCLUSION

Familial intrahepatic cholestasis is a heterogeneous group of rare disorders characterized by persistent or recurrent cholestasis due to mutations in genes involved in bile excretion. Depending on the type, these disorders may progress to cirrhosis or follow a benign course. A high index of suspicion is important for diagnosis, and this condition should be considered in the differential diagnosis of cholestatic liver diseases.

Ethical Considerations

This study was submitted to the research and ethics committee of Hospital San Ignacio and Pontificia Universidad Javeriana, in compliance with current research regulations and with the patient's informed consent. The authors declare there is no personal information that could identify the patient.

Funding Sources

This work did not receive any funding.

Conflict of Interest

The authors declare no conflict of interest.

REFERENCES

1. Halawi A, Ibrahim N, Bitar R. Triggers of benign recurrent intrahepatic cholestasis and its pathophysiology: a review of literature. Acta Gastroenterol Belg. 2021;84(3):477-86. https://doi.org/10.51821/84.3.013
2. van der Woerd WL, van Mil SWC, Stapelbroek JM, Klomp LWJ, van de Graaf SFJ, Houwen RHJ. Familial cholestasis: Progressive familial intrahepatic cholestasis, benign recurrent intrahepatic cholestasis and intrahepatic cholestasis of pregnancy. Best Pract Res Clin Gastroenterol. 2010;24(5):541-53. https://doi.org/10.1016/j.bpg.2010.07.010
3. Gunaydin M, Bozkurter Cil AT. Progressive familial intrahepatic cholestasis: diagnosis, management, and treatment.

Hepat Med. 2018;10:95-104.
https://doi.org/10.2147/HMER.S137209
4. Felzen A, Verkade HJ. The spectrum of Progressive Familial Intrahepatic Cholestasis diseases: Update on pathophysiology and emerging treatments. Eur J Med Genet. 2021;64(11):104317.
https://doi.org/10.1016/j.ejmg.2021.104317
5. van Wessel DBE, Thompson RJ, Gonzales E, Jankowska I, Shneider BL, Sokal E, et al. Impact of Genotype, Serum Bile Acids, and Surgical Biliary Diversion on Native Liver Survival in FIC1 Deficiency. Hepatology. 2021;74(2):892-906.
https://doi.org/10.1002/hep.31787
6. Folvik G, Hilde O, Helge GO. Benign recurrent intrahepatic cholestasis: review and long-term follow-up of five cases. Scand J Gastroenterol. 2012;47(4):482-8.
https://doi.org/10.3109/00365521.2011.650191
7. De Vloo C, Nevens F. Cholestatic pruritus: an update. Acta Gastroenterol Belg. 2019;82(1):75-82.
8. Van Berge Henegouwen GP. Benign recurrent intrahepatic cholestasis and Byler's disease: one gene, two diseases? J Hepatol. 1996;25(3):395-7.
https://doi.org/10.1016/S0168-8278(96)80128-0
9. van Ooteghem NAM, Klomp LWJ, van Berge-Henegouwen GP, Houwen RHJ. Benign recurrent intrahepatic cholestasis progressing to progressive familial intrahepatic cholestasis: low GGT cholestasis is a clinical continuum. J Hepatol. 2002;36(3):439-43.
https://doi.org/10.1016/S0168-8278(01)00299-9
10. van Mil SW, Klomp LW, Bull LN, Houwen RH. FIC1 Disease: A Spectrum of Intrahepatic Cholestatic Disorders. Semin Liver Dis. 2001;21(04):535-44.
https://doi.org/10.1055/s-2001-19034
11. Amirneni S, Haep N, Gad MA, Soto-Gutierrez A, Squires JE, Florentino RM. Molecular overview of progressive familial intrahepatic cholestasis. World J Gastroenterol. 2020;26(47):7470-84.
https://doi.org/10.3748/wjg.v26.i47.7470
12. Andersen JP, Vestergaard AL, Mikkelsen SA, Mogensen LS, Chalat M, Molday RS. P4-ATPases as Phospholipid Flippases-Structure, Function, and Enigmas. Front Physiol. 2016;7:275.
https://doi.org/10.3389/fphys.2016.00275
13. Luketic VA, Shiffman ML. Benign recurrent intrahepatic cholestasis. Clin Liver Dis. 2004;8(1):133-149.
https://doi.org/10.1016/S1089-3261(03)00133-8
14. Crosigani A, Podda M, Bertolini E, Battezzati PM, Zuin M, Setchell KDR. Failure of ursodeoxycholic acid to prevent a cholestatic episode in a patient with benign recurrent intrahepatic cholestasis: A study of bile acid metabolism. Hepatology. 1991;13(6):1076-83.
https://doi.org/10.1002/hep.1840130612

https://doi.org/10.22516/25007440.1119

Case report

Colonic Cystic Pneumatosis as a Manifestation of Colorectal Lymphoma: Case Report and Literature Review

Juan Guillermo Cala-Noriega,[1*] Carlos E. Figueroa-Avendaño.[2]

OPEN ACCESS

Citation:
Cala-Noriega JG, Figueroa-Avendaño CE. Colonic Cystic Pneumatosis as a Manifestation of Colorectal Lymphoma: Case Report and Literature Review. Revista. colomb. Gastroenterol. 2024;39(3):328-331.
https://doi.org/10.22516/25007440.1119

[1] Specialist in General Surgery, Coloproctology Resident, Universidad del Rosario, School of Medicine and Health Sciences. Bogotá, Colombia.
[2] Coloproctologist, Coloproctology Service, Hospital Universitario Mayor Méderi. Bogotá, Colombia.

***Correspondence:** Juan Guillermo Cala-Noriega.
juang.cala@urosario.edu.co

Received: 25/07/2023
Accepted: 26/10/2023

Abstract

Intestinal pneumatosis is defined as the presence of gas within the intestinal wall. Its pathogenesis is not fully understood; it is idiopathic in 15% of cases and a secondary manifestation of gastrointestinal and non-gastrointestinal diseases in 85% of cases. In secondary cases, there is a wide range of etiologies, and treatment should be directed at the primary disease. Pneumatosis can present with pneumoperitoneum and does not necessarily require surgical management. This report presents the clinical case of a middle-aged male patient with abdominal pain, endoscopic and imaging findings of intestinal pneumatosis, and lesions consistent with colorectal lymphoma. Additionally, a literature review on this condition is provided.

Keywords

Intestinal Cystoid Pneumatosis.

INTRODUCTION

Intestinal pneumatosis is defined as the presence of gas within the intestinal wall, which can affect the small intestine, the colon, or any layer of the intestinal wall[(1)]. Its pathogenesis is not well understood; it is idiopathic in 15% of cases and serves as a secondary manifestation of gastrointestinal and non-gastrointestinal diseases in 85% of cases[(2)]. We report a case of colorectal lymphoma presenting with intestinal pneumatosis among its clinical, endoscopic, and imaging features. The patient was treated with the R-CHOP regimen, resulting in disease remission and clinical improvement.

CLINICAL CASE

The patient is a 59-year-old male, previously healthy, with no relevant personal or family medical history. He presented with a 30-day history of fatigue, weakness, generalized abdominal pain primarily in the right iliac fossa, up to 12 daily episodes of diarrhea, each with associated rectal bleeding, and a weight loss of six kilograms.

On admission, his hemodynamic parameters were normal, with documented generalized abdominal pain, most pronounced in the right iliac fossa, but without signs of peritoneal irritation. Admission tests revealed anemia (hemoglobin [Hb]: 8.1 g/dL) and hypoalbuminemia

© 2024 Asociación Colombiana de Gastroenterología

(2.6 g/dL). A total colonoscopy showed multiple solid masses in the cecum, sigmoid colon, and rectum, affecting the mucosa and appearing submucosal, ranging from 15 to 40 mm in size, friable and non-collapsible, surrounding a large, soft, 6-cm mucosal cyst that was compressible on biopsy forceps contact. Biopsies were taken from the solid lesions. The remainder of the colon also displayed multiple cystic lesions, with larger ones observed in the rectum (**Figure 1A**, **B**, and **C**).

Thoracic CT imaging revealed no lesions. Abdominal CT showed cecal wall thickening with a thickness of 16 mm and thickening of the right posterolateral rectal wall, reaching a thickness of 15 mm, with a clear image of pneumatosis at this level (**Figure 1D** and **E**). Adjacent pericolic lymphadenopathy was seen near the ascending and transverse colon, with diameters up to 10 mm, associated with some cystic lesions of the colonic and rectal walls. Gastric antrum thickening was also observed, prompting an esophagogastroduodenoscopy with endoscopic findings suggestive of gastric lymphoma, from which biopsies were taken. Histopathology and immunohistochemistry results were compatible with mantle cell lymphoma (blastoid variant) in the stomach, cecum, sigmoid, and rectum.

Treatment was initiated with the R-maxiCHOP regimen by the hematology-oncology service, resulting in a favorable response. The final assessment via positron emission tomography-computed tomography (PET-CT) showed a complete metabolic response, with no evidence of colonic cystic pneumatosis.

DISCUSSION

Intestinal pneumatosis is a condition of variable etiology characterized by the presence of gas within the intestinal submucosa or subserosa[3]. It was first described by Du Vernoi in 1783 and later named *pneumatosis cystoides intestinalis* by Mayers in 1825[4]. In 1952, Koss presented a comprehensive series of 213 cases of intestinal pneumatosis, characterizing the condition and concluding that it is 3.5 times more common in men than in women[2]. Its inci-

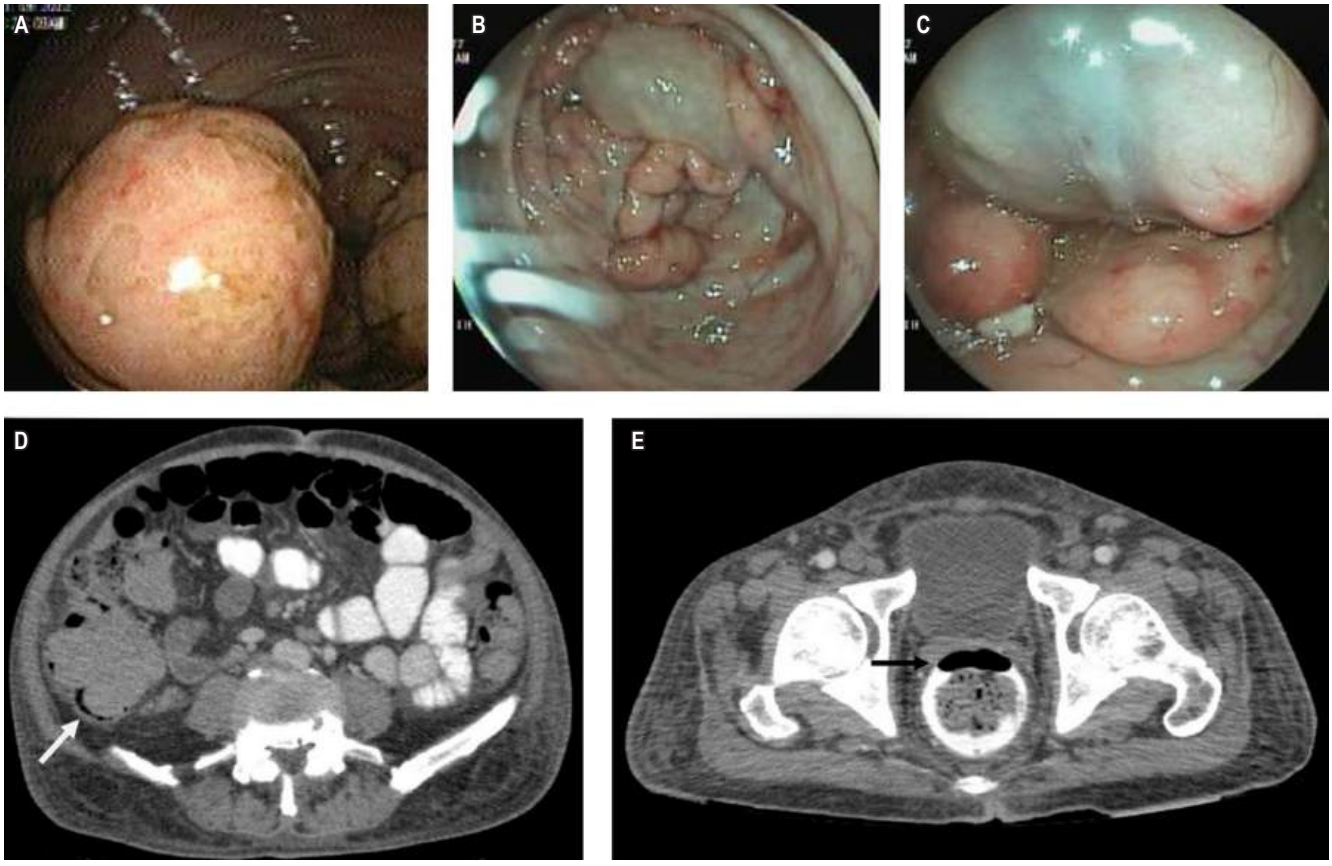

Figure 1. A. Ulcerated solid lesion. **B.** Cystic lesion surrounded by multiple solid lesions. **C.** Cystic lesion with pale blue mucosa compatible with colonic cystic pneumatosis. **D.** Cecum occupied by a solid mass with pneumatosis of its wall (white arrow). **E.** Pneumatosis image in the rectal wall (black arrow). Author's File.

dence remains unknown due to the asymptomatic course observed in a high number of patients[1].

In terms of etiology, 15% of intestinal pneumatosis cases are idiopathic, while 85% are secondary[2]. Various theories have been proposed to explain its pathogenesis. The mechanical theory suggests that gas dissects the intestinal wall through small mucosal lacerations or via the serosa, following the path of the mesenteric vasculature[5]. The bacterial theory posits that gas-producing bacteria reach the submucosa through small mucosal disruptions[6]. The biochemical theory supports the presence of pathogenic hydrogen-producing bacteria that increase intraluminal pressure due to excess gas, facilitating its migration into the submucosa, where it becomes trapped[7].

The diagnosis of intestinal pneumatosis is generally radiological and can be visualized on plain abdominal X-rays; however, tomography is more sensitive and can help document underlying conditions causing it[8]. Typical findings in colonoscopy include polypoid submucosal cysts covered by pale blue mucosa, which rapidly deflate upon puncture or biopsy[7]. Colonoscopy also allows for the identification of other mucosal lesions, such as polyps or tumors.

Most patients do not require specific treatment[3]. Patients presenting with intestinal pneumatosis alongside signs of peritonitis, metabolic acidosis, hyperlactatemia, or portal venous gas benefit from surgical exploration[9]. For patients who do not require urgent surgical intervention, management depends on symptom severity. Asymptomatic patients do not require treatment[7]. For patients with mild symptoms, antibiotics (such as metronidazole) and treatment of the underlying cause are recommended[10]. Oxygen supplementation and hyperbaric oxygen therapy have also been proposed to increase venous partial oxygen pressure, reduce partial pressure of other gases, and promote a diffusion gradient across the cyst wall. However, the precise dosage and duration required for complete resolution are not well defined[7,11]. Elemental diets have been used with relative success, aiming to alter the intestinal microbiota and inhibit gas-forming bacteria[7,12].

Lymphomas have been documented as an underlying cause of intestinal pneumatosis; however, most of these cases present with intra-abdominal complications that necessitate urgent surgical exploration, such as intussusception, stenosis, or free perforation due to colorectal lymphoma[13-16]. There are also limited reports of colonic cystic pneumatosis associated with lymphoma, which resolves after receiving specific quadruple therapy for lymphoma[16]. It remains unclear whether imaging should be repeated to document the resolution of intestinal pneumatosis, although some authors recommend it[17].

This case presents colonic cystic pneumatosis as a manifestation of gastrointestinal mantle cell lymphoma. Its significance lies in the fact that, in 85% of cases, pneumatosis is secondary to an underlying disease, necessitating a comprehensive patient evaluation. The colonic pneumatosis resolves once treatment for the underlying condition is provided.

CONCLUSIONS

- Intestinal cystic pneumatosis is a condition marked by gas deposits in various layers of the intestine and often reflects an underlying morbid condition.
- Diagnosis is generally radiological and should be supplemented with endoscopic evaluation, with the full clinical picture considered to guide treatment.
- Colonoscopy reveals submucosal cysts covered by pale blue mucosa that deflate upon puncture or biopsy.
- Reported etiologies include immunosuppression, medication associations, and gastrointestinal tract neoplasms, including lymphomas.
- Treatment options include oxygen supplementation, elemental diet, antibiotics, and addressing the underlying condition if identified.

REFERENCES

1. Heng Y, Schuffler MD, Haggitt RC, Rohrmann CA. Pneumatosis intestinalis: a review. Am J Gastroenterol. 1995;90(10):1747-58.
2. Koss LG. Abdominal gas cysts (pneumatosis cystoides intestinorum hominis); an analysis with a report of a case and a critical review of the literature. AMA Arch Pathol. 1952;53(6):523-49.
3. Wu LL, Yang YS, Dou Y, Liu QS. A systematic analysis of pneumatosis cystoids intestinalis. World J Gastroenterol. 2013;19(30):4973-8. https://doi.org/10.3748/wjg.v19.i30.4973
4. Du Vernoi JG. Anatomische Beobachtung der unter der äußeren und inneren Haut der Gedärme eingeschlossenen Luft. Phys Med Abhandl Acad Wissensch Petersb. 1783:2:182.
5. Pieterse AS, Leong AS, Rowland R. The mucosal changes and pathogenesis of pneumatosis cystoides intestinalis. Hum Pathol. 1985;16(7):683-8. https://doi.org/10.1016/S0046-8177(85)80152-0
6. Yale CE, Balish E, Wu JP. The bacterial etiology of pneumatosis cystoides intestinalis. Arch Surg. 1974;109(1):89-94. https://doi.org/10.1001/archsurg.1974.01360010067017

7. Johnson AM, Yen EF, Loftus EV, Pardi DS. Microscopic colitis, checkpoint inhibitor colitis, and other miscellaneous inflammatory and structural disorders of the colon. En: Wang TC, Camilleri M, Lebwohl B, Lok AS, Sandborn WJ, Wang KK, et al (editores). Yamada's Textbook of Gastroenterology. 7.ª edición. Wiley; 2022. p. 3154-73. https://doi.org/10.1002/9781119600206.ch66
8. Ihara E, Harada N, Motomura S, Chijiiwa Y. A new approach to Pneumatosis cystoides intestinalis by target air-enema CT. Am J Gastroenterol. 1998;93(7):1163-4. https://doi.org/10.1111/j.1572-0241.1998.354_q.x
9. Knechtle SJ, Davidoff AM, Rice RP. Pneumatosis intestinalis. Surgical management and clinical outcome. Ann Surg. 1990;212(2):160-5. https://doi.org/10.1097/00000658-199008000-00008
10. Tak PP, Van Duinen CM, Bun P, Eulderink F, Kreuning J, Gooszen HG, et al. Pneumatosis cystoides intestinalis in intestinal pseudoobstruction. Resolution after therapy with metronidazole. Dig Dis Sci. 1992;37(6):949-54. https://doi.org/10.1007/BF01300397
11. Masterson JS, Fratkin LB, Osler TR, Trapp WG. Treatment of pneumatosis cystoides intestinalis with hyperbaric oxygen. Ann Surg. 1978;187(3):245-7. https://doi.org/10.1097/00000658-197803000-00005
12. Johnston BT, McFarland RJ. Elemental diet in the treatment of pneumatosis coli. Scand J Gastroenterol. 1995;30(12):1224-7. https://doi.org/10.3109/00365529509101636
13. Liu T, Zhang S, Mao H. Gastrointestinal malignant neoplasms disguised as pneumatosis cystoids intestinalis: A case report and literature review. Medicine (Baltimore). 2017;96(51):e9410. https://doi.org/10.1097/MD.0000000000009410
14. Cho YM, Behrenbruch C, Smart P. Colonic lymphoma or pneumatosis coli: should I biopsy? ANZ J Surg. 2020;90(6):1198-1200. https://doi.org/10.1111/ans.15511
15. Mohd Rosli R, Raju D, Luck A, Raju S. B-cell lymphoma presenting as pneumatosis intestinalis: a case report. ANZ J Surg. 2014;84(11):892-3. https://doi.org/10.1111/ans.12750
16. O'Connell DJ, Thompson AJ. Pneumatosis coli in non-Hodgkins lymphoma. Br J Radiol. 1978;51(603):203-5. https://doi.org/10.1259/0007-1285-51-603-203
17. Höer J, Truong S, Virnich N, Füzesi L, Schumpelick V. Pneumatosis cystoides intestinalis: confirmation of diagnosis by endoscopic puncture a review of pathogenesis, associated disease and therapy and a new theory of cyst formation. Endoscopy. 1998;30(9):793-9. https://doi.org/10.1055/s-2007-1001424

https://doi.org/10.22516/25007440.1117

Case report

Liver Abscess Due to Fish Bone: Case Report

Annar Aileen Cuesta-Pertuz,[1*] Óscar Alberto Mosquera-López,[2] Isabel Cristina Palacios-Cuesta,[3] Jesús Alberto Mosquera-López,[4] Daniela Patricia De León-Valdés.[5]

OPEN ACCESS

Citation:
Cuesta-Pertuz AA, Mosquera-López OA, Palacios-Cuesta IC, Mosquera-López JA, De León-Valdés DP. Liver Abscess Due to Fish Bone: Case Report. Revista. colomb. Gastroenterol. 2024;39(3):332-336. https://doi.org/10.22516/25007440.1117

[1] Physician, Specialist in General Surgery, Diagnosticar S. A. S. Quibdó, Colombia.
[2] Physician, Radiologist, Specialist in Interventional Radiology, Imaging Diagnostics Unit, Diagnosticar S. A. S. Quibdó, Colombia.
[3] General Practitioner, Clínica Diagnosticar S. A. S. Quibdó, Colombia.
[4] Physician, Radiology and Diagnostic Imaging Resident, Universidad de La Sabana. Bogotá, Colombia.
[5] Physician, Specialist in General Surgery, Diagnosticar S. A. S. Quibdó, Colombia.

***Correspondence:** Annar Aileen Cuesta-Pertuz.
aileenqpert@gmail.com

Received: 24/07/2023
Accepted: 17/10/2023

Abstract

The presence of foreign bodies in the liver is an uncommon condition. This report details the case of a patient with a hepatic abscess caused by a fishbone, which migrated from the gastrointestinal tract. The clinical manifestations were nonspecific, making the timely diagnosis and early surgical intervention crucial in reducing hospital stay, the risk of complications, and mortality.

Keywords

General Surgery, Hepatology, Foreign Body Reaction.

INTRODUCTION

A liver abscess is defined as a collection of pus encapsulated by a membrane, resulting from an infection that causes destruction of the liver parenchyma and stroma[(1)]. The incidence in North America is 2.3 per 100,000 hospital admissions, while in Taiwan it is 275.4 per 100,000[(2)]. If not properly diagnosed and treated, this condition has a high rate of morbidity and mortality. The most significant predisposing factors for developing a liver abscess are diabetes *mellitus* (39.6%), gallbladder or biliary tract surgeries (21.3%), and chronic alcohol abuse (10.5%)[(3)].

Liver abscesses caused by foreign bodies, particularly fish bones, represent a potentially severe condition. It is essential to describe this case, characterized by an insidious clinical presentation, nonspecific symptoms, and an unclear history of foreign body ingestion, similar to cases reported in the literature. This case highlights the importance of early diagnosis and appropriate multidisciplinary management, which led to complete resolution of the disease in a short period. When the presence of a foreign body is not initially identified, treatment may be prolonged due to its persistence in the liver, causing abscess recurrence and necessitating multiple percutaneous or open drainage procedures.

© 2024 Asociación Colombiana de Gastroenterología

CASE REPORT

This case involves a 55-year-old male patient presenting with a one-year history of intermittent abdominal pain localized to the epigastric and left iliac fossa regions, without other associated symptoms. He denied having fever, jaundice, or ingesting any foreign body. His medical history included obesity, hypertension, and frequent alcohol consumption. He presented to our institution for an abdominal ultrasound, which identified a liver abscess in segments II and III containing a foreign body, along with inflammatory changes in the fat of the gastrohepatic omentum (**Figure 1**). Subsequently, an abdominal CT scan was requested to confirm these findings (**Figure 2**). The general surgery team opted for hospitalization to provide antibiotic therapy with intravenous ciprofloxacin 200 mg every 12 hours and metronidazole 500 mg every 8 hours. Admission laboratory tests indicated elevated acute-phase reactants (leukocytosis, mild neutrophilia, and C-reactive protein [CRP]), mild alteration in liver enzymes (aspartate aminotransferase [AST]: 52.3 U/L and alanine aminotransferase [ALT]: 23.3 U/L), with bilirubin levels, alkaline phosphatase, and coagulation times within normal limits.



Figure 1. Abdominal ultrasound showing a 3.7 cm linear echogenic structure consistent with a foreign body within, along with an abscess in the left liver lobe. Source: Department of Radiology, Clínica Diagnosticar Clinic. Quibdó, Chocó.

On the first day of hospitalization, an attempt was made to extract the foreign body percutaneously, which was unsuccessful. The patient was then taken for a laparotomy with intraoperative ultrasound to mark the abscess and locate the foreign body. The abscess was successfully drained, and the fish bone was removed (**Figures 3**, **4** and **5**) through a single incision in the liver with minimal bleeding. Hemostatic hepatorrhaphy was subsequently performed using chromic catgut suture with a BP1 atraumatic needle, and a drainage system was left in place. Cultures from the secretion isolated *Streptococcus constellatus*, a bacterium that is part of the oropharyngeal flora and was sensitive to the empirically initiated antibiotics. In-hospital antibiotic therapy was administered for five days, followed by outpatient treatment to complete a 21-day course. Prior to discharge, an ultrasound showed resolution of the liver abscess and recent postoperative changes in the left lobe (**Figure 6**).

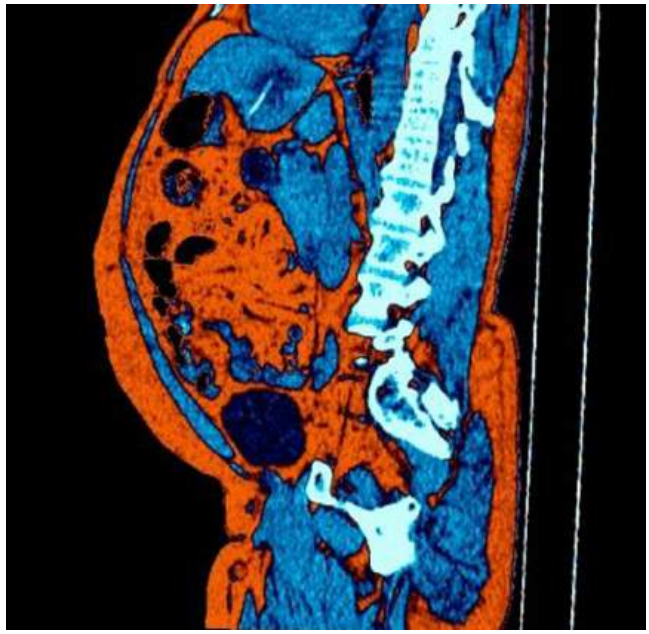

Figure 2. Abdominal CT scan, demonstrating a liver abscess in segments II and III, with a foreign body extending into the adjacent liver parenchyma. Source: Department of Radiology, Clínica Diagnosticar. Quibdó, Chocó.

DISCUSSION

A liver abscess is a collection of pus and cellular debris within the liver parenchyma due to parasitic, bacterial, or fungal colonization[4]. The incidence and mortality are more closely associated with bacterial abscesses, and these rates have declined since the introduction of percutaneous drainage, affecting 20% to 60% of cases[5], with rupture being the primary complication[4]. Currently, no studies in our region indicate its prevalence; however, due to sociocultural conditions, limited access to public services, and sanitation levels, the primary presentation of liver abscesses in Colombia is amebic[6]. Pyogenic abscesses have an incidence of 2.3 cases per 100,000 population[7]. The etiology is polymicrobial, with pathogens such as *Klebsiella pneumoniae*, *Escherichia coli*, and *Streptococcus* species (when

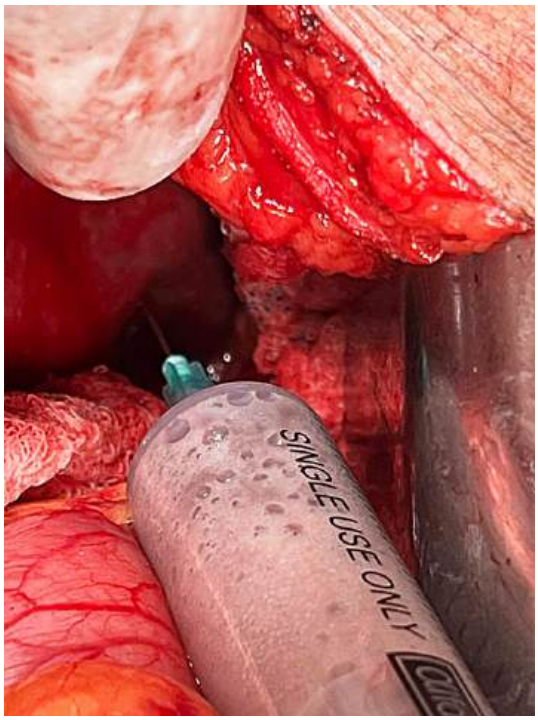

Figure 3. Liver abscess drainage. Source: Department of Surgery, Clínica Diagnosticar. Quibdó, Chocó.



Figure 4. Foreign body (fish bone) removal. Source: Department of Surgery, Clínica Diagnosticar. Quibdó, Chocó.



Figure 5. Foreign body (fish bone). Source: Department of Surgery, Clínica Diagnosticar. Quibdó, Chocó.



Figure 6. Postoperative liver ultrasound. Source: Department of Radiology, Clínica Diagnosticar. Quibdó, Chocó.

produced by foreign bodies[8,9]), including the *Anginosus group*, which has three representative species including *constellatus*, commonly found in oropharyngeal, upper gastrointestinal, and urinary tract flora[8]. While mortality from liver abscesses remains significant, recent studies report a substantial decline, with rates varying between 11% and 31%. Streptococcus is the most frequently isolated pathogen, although the etiologic agent remains unknown in about half of the cases[10]. Predisposing factors for pyogenic liver abscesses include diabetes *mellitus* (39.6% of cases), biliary tract interventions (21.3%), and chronic alcohol abuse (10.5% of cases)[3].

Liver abscesses due to foreign bodies are extremely rare and may result from the ingestion of materials like needles, chicken bones, and fish bones—the latter being the most common among adults[11]. The first case of liver abscess associated with an intrahepatic foreign body was reported in 1898[12], but liver abscesses specifically related to fish bones remain scarcely reported, limited to isolated case reports. Once a foreign body is ingested, the primary sites for penetration into the liver are the stomach and duodenum[13], where it typically lodges in the liver's left lobe[11]. Only 1% of accidental foreign body ingestion results in perforation[14], making these severe and unusual cases that pose diagnostic and therapeutic challenges. Symptoms may vary from one to three weeks[15,16] or extend over months or even years[11] and include nonspecific symptoms such as fever, upper abdominal quadrant pain, weight loss, vomiting, and anorexia[9]. Migration of a foreign body to the liver can remain asymptomatic for an extended period and is generally detected only once infection or abscess formation occurs. Therefore, diagnosis based on medical history and physical examination is challenging: suspicion is typically low due to both the patient's lack of awareness of foreign body ingestion and the nonspecific nature of symptoms, which can mimic other causes of abdominal pain, including renal abscess, subphrenic abscess, acute cholecystitis, acute appendicitis, cholangitis, pleurisy, lung abscess, and severe infectious diseases in general[10].

In the presence of a foreign body, the ideal treatment involves a combination of object removal, abscess drainage, and antibiotic therapy, as very few cases can be successfully managed with conservative approaches alone in this context[11,17,18]. Broad-spectrum antibiotic therapy should be initiated promptly and should not be delayed by awaiting culture results. The duration of antibiotic therapy should extend to a maximum of two weeks, followed by appropriate oral treatment for an additional four to six weeks[18].

Advances in combining surgical techniques and imaging have made it possible to use flexible-tip laparoscopic ultrasound in minimally invasive procedures, allowing for fewer incisions and high success rates with reduced tissue damage. In our case, laparotomy with intraoperative ultrasound marking was used due to local resource availability, yielding excellent results as only a single incision was required for abscess drainage and foreign body extraction[19-21].

CONCLUSION

The overall prognosis for patients with this type of abscess depends on comorbidities and the speed of diagnosis and treatment. For abscesses requiring multiple drainages or with atypical contents, the possibility of an associated foreign body should be considered to enable a timely and appropriate therapeutic approach with suitable surgical techniques, as in this case, to reduce mortality in these patients.

REFERENCES

1. Yu Y, Guo L, Hu C, Chen K. Spectral CT imaging in the differential diagnosis of necrotic hepatocellular carcinoma and hepatic abscess. Clin Radiol. 2014;69(12):e517-e524. https://doi.org/10.1016/j.crad.2014.08.018
2. Chen CH, Wu SS, Chang HC, Chang YJ. Initial presentations and final outcomes of primary pyogenic liver abscess: a cross-sectional study. BMC Gastroenterol. 2014;14:133. https://doi.org/10.1186/1471-230X-14-133
3. Lin ACM, Yeh DY, Hsu YH et al. Diagnosis of pyogenic liver abscess by abdominal ultrasonography in the emergency department. Emerg Med J. 2009;26(4):273-275. https://doi.org/10.1136/emj.2007.049254
4. Mavilia MG, Molina M, Wu GY. The Evolving Nature of Hepatic Abscess: A Review. J Clin Transl Hepatol. 2016;4(2):158-68. https://doi.org/10.14218/JCTH.2016.00004
5. Lodhi S, Sarwari AR, Muzammil M, Salam A, Smego RA. Features distinguishing amoebic from pyogenic liver abscess: a review of 577 adult cases. Trop Med Int Health. 2004;9(6):718-23. https://doi.org/10.1111/j.1365-3156.2004.01246.x
6. López MC, Quiroz DA, Pinilla AE. Diagnóstico de amebiasis intestinal y extraintestinal [Internet]. Acta Med Colomb. 2008;33(2):75-83 [consultado el 16 de septiembre de 2024]. Disponible en: https://www.actamedicacolombiana.com/ojs/index.php/actamed/article/view/1759

7. MacFadden DR, Penner TP, Gold WL. Persistent epigastric pain in an 80-year-old man. CMAJ. 2011;183(8):925-8. https://doi.org/10.1503/cmaj.101510
8. Mohanty S, Panigrahi MK, Turuk J, Dhal S. Liver Abscess due to Streptococcus constellatus in an Immunocompetent Adult: A Less Known Entity. J Natl Med Assoc. 2018;110(6):591-595. https://doi.org/10.1016/j.jnma.2018.03.006
9. Tsui BC, Mossey J: Occult liver abscess following clinically unsuspected ingestion of foreign bodies. Can J Gastroenterol. 1997;11(5):445-8. https://doi.org/10.1155/1997/815876
10. Bandeira-de-Mello RG, Bondar G, Schneider E, Wiener-Stensmann IC, Gressler JB, Kruel CRP. Pyogenic liver abscess secondary to foreign body (fish bone) treated by laparoscopy: A case report. Ann Hepatol. 2018;17(1):169-73. https://doi.org/10.5604/01.3001.0010.7550
11. Santos SA, Alberto SC, Cruz E, Pires E, Figueira T, Coimbra E, et al. Hepatic abscess induced by foreign body: case report and literature review. World J Gastroenterol. 2007;13(9):1466-70. https://doi.org/10.3748/wjg.v13.i9.1466
12. Lambert A. Abscess of the liver of unusual origin. NY Med J. 1898:177-78.
13. Chintamani, Singhal V, Lubhana P, Durkhere R, Bhandari S. Liver abscess secondary to a broken needle migration--a case report. BMC Surg. 2003;3:8. https://doi.org/10.1186/1471-2482-3-8
14. Hunter TB, Taljanovic MS. Foreign bodies. Radiographics. 2003;23(3):731-57. https://doi.org/10.1148/rg.233025137
15. Horii K, Yamazaki O, Matsuyama M, Higaki I, Kawai S, Sakaue Y. Successful treatment of a hepatic abscess that formed secondary to fish bone penetration by percutaneous transhepatic removal of the foreign body: report of a case. Surg Today 1999;29(9):922-926. https://doi.org/10.1007/BF02482788
16. Ndong A, Tendeng JN, Ndoye NA, Diao ML, Dieye A, Diallo AC, et al. Predictive risk factors for liver abscess rupture: A prospective study of 138 cases. Arch Clin Gastroenterol. 2020;6(1):1-5. https://doi.org/10.17352/2455-2283.000067
17. Webb WA. Management of foreign bodies of the upper gastrointestinal tract: update. Gastrointest Endosc. 1995;41(1):39-51. https://doi.org/10.1016/s0016-5107(95)70274-1
18. Reid-Lombardo KM, Khan S, Sclabas G. Hepatic cysts and liver abscess. Surg Clin North Am. 2010;90(4):679-97. https://doi.org/10.1016/j.suc.2010.04.004
19. Skjoldbye B, Brahe NE, Jess P, Nolsøe CP. Laparoskopisk ultralydskanning af lever, galdeveje og pancreas med styrbart lydhoved. Ugeskr Laeger. 1995;157(5):580-3.
20. Foley EF, Kolecki RV, Schirmer BD. The accuracy of laparoscopic ultrasound in the detection of colorectal cancer liver metastases. Am J Surg 1998;176(3):262-264. https://doi.org/10.1016/S0002-9610(98)00147-0
21. Salmon M, Doniger SJ. Ingested foreign bodies: A case series demonstrating a novel application of point-of-care ultrasonography in children. Pediatr Emerg Care. 2013;29(7):870-873. https://doi.org/10.1097/PEC.0b013e3182999ba3

https://doi.org/10.22516/25007440.1113

Case report

Blue Rubber Bleb Nevus Syndrome in the Colon, Tongue, and Supraglottic Region: Case Report

Fabián Eduardo Puentes-Manosalva,[1] Rubén Darío Londoño-López,[2*] Andrés Sánchez-Gil,[1] Lázaro Antonio Arango-Molano.[3]

OPEN ACCESS

Citation:
Puentes-Manosalva FE, Londoño-López RD, Sánchez-Gil A, Arango-Molano LA. Blue Rubber Bleb Nevus Syndrome in the Colon, Tongue, and Supraglottic Region: Case Report. Revista. colomb. Gastroenterol. 2024;39(3):337-343. https://doi.org/10.22516/25007440.1113

[1] Specialist in General Surgery, Subspecialist in Clinical-Surgical Gastroenterology. Professor in the Clinical-Surgical Gastroenterology Program, Universidad de Caldas. Manizales, Colombia.
[2] Specialist in General Surgery, Clinical-Surgical Gastroenterology Fellow, Universidad de Caldas. Manizales, Colombia.
[3] Specialist in General Surgery, Subspecialist in Clinical-Surgical Gastroenterology, Head of the Clinical-Surgical Gastroenterology Program, Universidad de Caldas. Manizales, Colombia.

***Correspondence:** Rubén Darío Londoño-López.
rudamed78@yahoo.es

Received: 24/07/2023
Accepted: 25/08/2023

Abstract

Blue Rubber Bleb Nevus Syndrome (BRBNS) is an extremely rare and likely hereditary condition characterized by the presence of numerous hemangiomatous lesions that are purplish, raised, and elastic, primarily affecting the skin and the digestive system. These lesions become prominent and rubbery to the touch. BRBNS can also affect other organs. Clinically, it may be asymptomatic or present with painful skin lesions, hyperhidrosis, abdominal pain, gastrointestinal bleeding, anemia, and hematuria, among other signs and symptoms. Treatment options include conservative management, pharmacological intervention, endoscopic procedures, or surgery. This report presents the clinical case of a 22-year-old woman with a history of BRBNS affecting the skin and lips but with no gastrointestinal symptoms. She is under dermatological follow-up and management. The patient was seen on an outpatient basis at the endoscopy unit of Unión de Cirujanos S.A.S. in Manizales, Colombia, at the Clinical-Surgical Gastroenterology Service of the Universidad de Caldas. An upper digestive endoscopy (EVDA) and ileocolonoscopy were performed to rule out the presence of similar lesions in the gastrointestinal tract. The EVDA revealed vascular, raised, rubbery lesions at the base of the tongue and in the supraglottic region, with no involvement of the esophagus, stomach, or duodenum. The ileocolonoscopy showed multiple vascular, raised lesions in the cecum, transverse colon, and descending colon.

Keywords

Blue Rubber Bleb Nevus Syndrome, colon, tongue, glottis.

INTRODUCTION

Blue rubber bleb nevus syndrome (BRBNS) is characterized by the formation of multiple vascular malformations and hemangiomas that can affect various organs, particularly the skin and gastrointestinal tract[(1)]. Although gastrointestinal BRBNS is the second most commonly affected site after the skin, it is rare, with the small intestine being the most frequently involved area, followed by the colon. It can present with gastrointestinal bleeding and anemia. BRBNS is usually diagnosed at birth or during childhood; however, it may also be identified in adulthood and can even present without cutaneous manifestations[(1,2)]. Other possible sites of involvement include the central nervous system (CNS), eyes, thyroid, kidneys, spleen, and extremities[(2)].

CLINICAL CASE

The patient is a 22-year-old woman with a history of blue rubber bleb nevus syndrome (BRBNS) affecting the skin throughout her body, including her lips (**Figure 1**). She was under dermatological follow-up without gastrointes-

tinal symptoms and was referred as an outpatient to the endoscopy unit at Unión de Cirujanos S.A.S. in Manizales, Colombia, part of the Clinical-Surgical Gastroenterology Service at the Universidad de Caldas, for an upper gastrointestinal endoscopy and colonoscopy to rule out similar lesions in the gastrointestinal tract.

Upper gastrointestinal endoscopy revealed BRBNS manifested as vascular lesions with a raised, nodular appearance, approximately 15 mm in size, at the base of the tongue (**Figure 2**) and in the supraglottic region (**Figure 3**), which restricted the mobility of the vocal folds. No lesions were observed in the esophagus, stomach, or duodenum.

Ileocolonoscopy demonstrated BRBNS with multiple vascular, nodular lesions measuring between three and five mm in the cecum (**Figure 4**), transverse colon, and descending colon (**Figure 5**). No lesions were observed in the remaining segments examined, including 15 cm of the distal ileum.

The patient is currently under clinical follow-up with dermatology, gastroenterology, and otolaryngology services.

DISCUSSION

Blue rubber bleb nevus syndrome (BRBNS) was first described by Gascoyen in 1860. However, William Bennett Bean later named the disease in 1958, and it is thus also referred to as *Bean syndrome*. BRBNS is an extremely rare and potentially hereditary condition, with an estimated incidence of 1 in 14,000 live births and only about 200 cases reported globally[2,4-6]. This syndrome is characterized by numerous hemangiomatous, violaceous, raised, and elastic lesions, primarily affecting the skin and digestive system.



Figure 1. BRBNS in the lip and skin. **A.** Upper lip and facial area. **B.** Neck. **C.** Chest. **D.** Wrist. Images from the files of Unión de Cirujanos S.A.S., Manizales, Colombia, Clinical-Surgical Gastroenterology Service, Universidad de Caldas.

These lesions are notable for their prominent, rubbery texture; they empty upon compression and rapidly refill once pressure is released, a key diagnostic sign[1,3,4]. Most cases are sporadic, although mutations in the TEK gene have been found to cause BRBNS with an autosomal dominant inheritance pattern linked to chromosome 9p, with a male predominance in a 2:1 ratio[2,4].

Skin lesions commonly allow for diagnosis during childhood, with only 4% of cases identified in adulthood; some cases have even been diagnosed in patients over 80 years old[2,3]. After the skin, the gastrointestinal tract is the second most affected region, primarily involving the small intestine, followed by the colon. However, lesions can appear in various locations from the tongue to the anus. BRBNS lesions may also affect other organs, including the central nervous system (CNS), eyes, thyroid, nasopharynx, larynx, trachea, lungs, pleura, heart, liver, pancreas, kidneys, spleen, peritoneum, urinary tract, skeletal muscle, and joints, among others[1-8].

BRBNS is classified into three types: type 1 presents as a large, deforming cavernous angioma that may obstruct vital tissue; type 2, the most common, appears as a "blue rub-



Figure 2. BRBNS at the base of the tongue. Image courtesy of Dr. Fabián Eduardo Puentes Manosalva, Unión de Cirujanos S.A.S., Manizales, Colombia, Clinical-Surgical Gastroenterology Service, Universidad de Caldas.



Figure 3. BRBNS in the supraglottic region. Image courtesy of Dr. Fabián Eduardo Puentes Manosalva, Unión de Cirujanos S.A.S., Manizales, Colombia, Clinical-Surgical Gastroenterology Service, Universidad de Caldas.



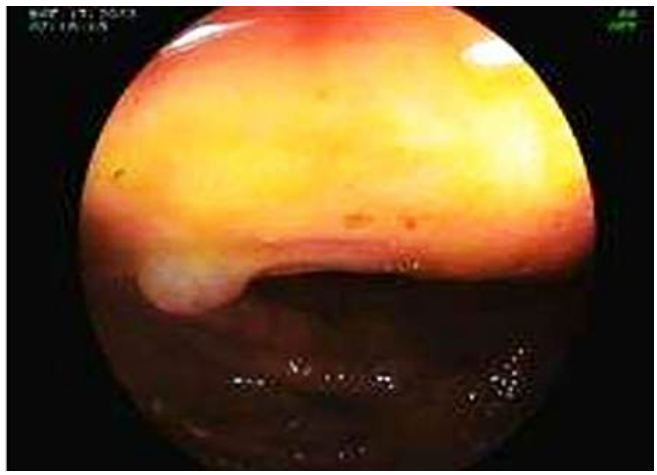

Figure 4. BRBNS in the cecum. Image courtesy of Dr. Fabián Eduardo Puentes Manosalva, Unión de Cirujanos S.A.S., Manizales, Colombia, Clinical-Surgical Gastroenterology Service, Universidad de Caldas.

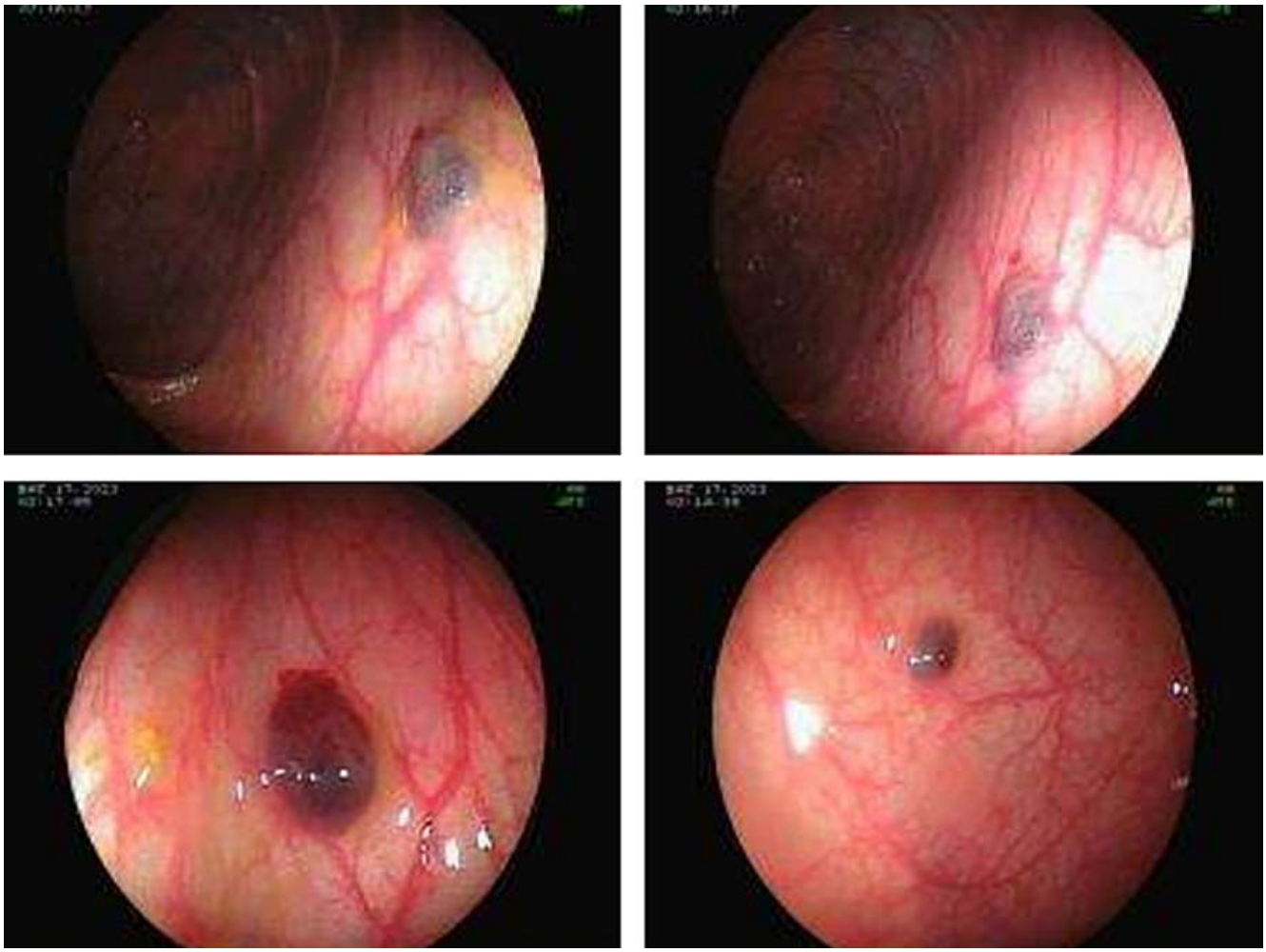

Figure 5. BRBNS in the transverse and descending colon. Images courtesy of Dr. Fabián Eduardo Puentes Manosalva, Unión de Cirujanos S.A.S., Manizales, Colombia, Clinical-Surgical Gastroenterology Service, Universidad de Caldas.

ber bleb" covered by thin, compressible skin that reappears upon releasing digital pressure; and type 3 includes irregular blue or black macules or papules that do not blanch with digital pressure[5,9]. Histologically, vascular malformations are evident without malignant changes, featuring dilated capillaries, flattened endothelium, connective tissue stroma, and a deficiency of smooth muscle cells[5,6].

Cutaneous lesions vary in size and number and are often asymptomatic, though they may occasionally be accompanied by pain and hyperhidrosis. Some deeper lesions can invade muscle, joints, and bone, potentially causing bone deformities, pathologic fractures, hemarthrosis, and early-onset osteoarthritis. When located outside the skin, lesions often produce symptoms specific to their site, such as abdominal pain, melena, hematochezia, rectal bleeding, anemia, hematuria, orbital malformations, intussusception, volvulus, intestinal ischemia, spinal cord compression, and others[2,9-12]. Oral lesions may present as superficial and deep angiomatoid tumors, commonly on the tongue, frequently causing pain[11]. Differential diagnoses primarily include Osler-Weber-Rendu syndrome, Klippel-Trénaunay syndrome, Maffucci syndrome, Von Hippel-Lindau syndrome, Sturge-Weber syndrome, Cobb syndrome, and multiple glomangiomas[11,13].

Diagnosis can be clinical, histopathological, and radiological. It can also be complemented with endoscopic examination, fecal occult blood testing, urinalysis, complete blood count, and iron kinetics studies. Lesions may be detected by Doppler ultrasound and computed tomography (CT), but magnetic resonance imaging (MRI) with

venous and arterial contrast and fat suppression offers superior visualization[6,7,9].

Since these are low-flow venous malformations, the possibility of thrombosis should be considered, identified by tenderness on palpation, warmth, and edema at the lesion sites. Splenoportal thrombosis with splenic infarction has also been reported. In addition to hemorrhage, other complications can arise, such as calcifications (phleboliths), and, in less frequent cases, consumption coagulopathy and thrombocytopenia[4,9,11,12].

Up to 97% of patients have cutaneous involvement; 87% may present involvement of more than one organ, 76% have gastrointestinal hemangiomas, and 13% may experience CNS involvement[9].

Morbidity and mortality depend on the extent and number of visceral lesions. Severe cases often present as major gastrointestinal bleeding. Gastrointestinal lesions in BRBNS may appear as multilobulated, nodular, pedunculated, sessile, ulcerated, angiomatoid lesions with a wine-red or violaceous color, raised above the mucosa, with a rough surface or even slightly depressed with central umbilication[3,12]. For a complete diagnosis, various endoscopic studies, including esophagogastroduodenoscopy, colonoscopy, enteroscopy, and capsule endoscopy, are very useful. Endoscopic ultrasound may also be used for lesions accessible to this technique, helping to determine if they are transmural, which guides endoscopic management[12].

A multidisciplinary approach is recommended for BRBNS to determine the extent of the disease and therapeutic plan. Treatment should be individualized based on the size, number, and location of the lesions. Surgical resection may be considered for cutaneous lesions, primarily for aesthetic purposes or if they are painful, especially for small superficial lesions between two and four cm that do not invade other structures. If these criteria are not met, preoperative embolization may be performed. Another management option is sclerotherapy, which induces thrombosis and necrosis of the malformation, ultrasound-guided cryoablation, or laser therapy[7,9,12].

Currently, there is no curative treatment. For gastrointestinal lesions, management is symptomatic and generally conservative, with iron supplementation or blood transfusions as needed. Specific endoscopic therapies are also possible, including sclerotherapy, rubber band ligation, argon plasma coagulation, electrocautery, cyanoacrylate injection, or surgery (such as segmental intestinal resections or colectomies). When gastrointestinal lesions are too extensive and uniformly distributed throughout the intestine, surgical resection is not feasible due to the risk of short bowel syndrome. If the lesions are not bleeding, BRBNS patients may be monitored clinically[4,9,10,12], as in the case of the patient presented in this article, who is under follow-up by dermatology, gastroenterology, and otolaryngology services.

Pharmacological management has also been described, involving drugs such as propranolol, corticosteroids, octreotide, and interferon-alpha. Additionally, with more promising results, sirolimus (rapamycin) has been used, an immunosuppressant that inhibits the mTOR (mammalian target of rapamycin) pathway. Due to its antineoplastic properties, which inhibit neovascularization and tumor cell proliferation, sirolimus has shown benefits in reducing the number and size of BRBNS lesions[9,10].

For patients requiring surgery under general anesthesia, airway management can be challenging when BRBNS lesions are present in the larynx or trachea, as seen in the patient presented here, who has BRBNS involvement in the supraglottic region and at the base of the tongue, posing risks of obstruction or bleeding at these sites. Therefore, it is crucial for the anesthesiologist to conduct a thorough preoperative assessment, ideally with consideration for a videolaryngoscope and, if necessary, a fiber-optic bronchoscope. Additionally, in patients with BRBNS lesions in the spinal canal, epidural anesthesia may lead to bleeding and hematoma formation if not carefully managed[8].

CONCLUSION

Blue rubber bleb nevus syndrome (BRBNS) is a rare condition characterized by multiple vascular malformations and hemangiomas affecting various organs, primarily the skin and gastrointestinal tract. With only around 200 cases reported worldwide, we consider it highly relevant to contribute this case to the medical literature in Colombia, where we have identified a patient with BRBNS presenting not only cutaneous involvement but also lesions in the colon, supraglottic region, and at the base of the tongue.

BRBNS may be asymptomatic or present with painful cutaneous lesions with hyperhidrosis, bone deformities, hemarthrosis, abdominal pain, melena, hematochezia, rectal bleeding, anemia, hematuria, and other symptoms. Evaluation can be supplemented with endoscopic examination, fecal occult blood testing, urinalysis, complete blood count, and iron kinetics. Imaging studies such as Doppler ultrasound, CT, and MRI are also useful. A multidisciplinary approach is recommended to assess the extent of the disease and establish a therapeutic plan. Currently, there is no curative treatment. For gastrointestinal lesions, management is generally conservative and symptomatic, as in the case of the patient presented here, who is under follow-up by dermatology, gastroenterology, and otolaryngology services. Iron supplementation or blood transfusions may be required if necessary. In some cases, endoscopic or surgical

intervention may be offered, where the potential presence of BRBNS lesions in the larynx or trachea should be considered. In this case, the patient has BRBNS involvement in the supraglottic region and at the base of the tongue, presenting a risk of obstruction or bleeding at these sites, which poses a challenge for the anesthesiologist. Among pharmacological options, sirolimus has shown the most promising results.

Conflict of Interest

The authors declare no conflicts of interest for this article.

REFERENCES

1. Blanco-Velasco G, Zamarripa-Mottú R, Solórzano-Pineda OM, Murcio-Pérez E, Hernández-Mondragón OV. Blue rubber bleb nevus syndrome in geriatric patients. Rev Gastroenterol Mex (Engl Ed). 2020;85(2):215-216. https://doi.org/10.1016/j.rgmx.2019.03.004
2. Laube R, Rickard M, Lee AU. Gastrointestinal: Small intestinal blue rubber bleb nevus syndrome. J Gastroenterol Hepatol. 2021;36(10):2637. https://doi.org/10.1111/jgh.15422
3. Matas JL, Asteinza M, Loscos JM, Fernández S, Ramírez-Armengol JA, Díaz-Rubio M. Síndrome del nevus gomoso azul (blue rubber bleb nevus) diagnosticado por cápsula endoscópica. Rev Esp Enferm Dig. 2006;98(7):555-6. https://doi.org/10.4321/S1130-01082006000700011
4. Solano-Iturri G, Blanco-Sampascual S, García-Jiménez N, Díaz-Roca AB, Orive-Cura V. Síndrome del nevus azul. Una rara entidad. Gac Med Bilbao 2011;108(4):117-119. https://doi.org/10.1016/j.gmb.2011.06.005
5. López-Ugalde MV, Cazares-Méndez MJ, Vivar-Aquino LD, Cadena-León JF, Cervantes-Bustamante R, Zárate-Mondragón F, et al. Síndrome de nevos azules ahulados: reporte de un caso. Rev Gastroenterol Mex. 2012;77(4):216-9. https://doi.org/10.1016/j.rgmx.2012.05.003
6. Jaramillo CI, Vélez A, Molina V. Síndrome de los nevus azules cauchosos. Rev Asoc Colomb Dermatol Cir Dematol. 1999;7(3):242-244.
7. Triana GA, Valencia S, Forero PA. Manifestaciones radiológicas del síndrome del nevus azul. Presentación de caso. Rev Colomb Radiol. 2021;32(2):5569-5572. https://doi.org/10.53903/01212095.138
8. Aizawa M, Ishihara S, Yokoyama T. Anesthetic considerations for blue rubber bleb nevus syndrome: a case report. JA Clin Rep. 2019;5(1):83. https://doi.org/10.1186/s40981-019-0304-4
9. Tibaduiza MF, Ton CM, Múnera MS, Plaza M. Síndrome de nevus azules cauchosos: reporte de un caso familiar. Rev Asoc Colomb Dermatol Cir Dematol. 2022;30(3):204-208. https://doi.org/10.29176/2590843X.1649
10. Ferrés L, Knöpfel N, Salinas JA, Martín A. Rapamycin in the treatment of blue rubber bleb nevus syndrome. Actas Dermosifiliogr 2015;106(2):137-152. https://doi.org/10.1016/j.adengl.2014.12.006
11. Coral A, Ávalos V, Fragoso R, Cuairán V. Síndrome *blue rubber bleb nevus*. Reporte de un caso: manejo estomatológico. Oral. 2015;16(52):1297-1300.
12. Gutiérrez I, León R, López T, Márquez JL. Aportación de las nuevas técnicas endoscópicas al síndrome del nevus azul. RAPD Online. 2013;36(3):190-194.
13. Kido M, Nakamura K, Kuwahara T, Yasui Y, Okajima H, Kurose N, et al. Arteriovenous malformation that caused prolapse of the colon and was treated surgically in an infant: a case report. Surg Case Rep. 2020;6(1):67. https://doi.org/10.1186/s40792-020-00824-x

https://doi.org/10.22516/25007440.1110

Case report

A Forgotten Cause of Recurrent Abdominal Pain: Case Report

Carlos Mauricio Martínez-Montalvo,[1*] David José Ramírez-Daza,[2] Laura Catalina Gutiérrez-Rueda,[3] David Felipe Olarte-Parra,[4] Laura Otálora-González.[4]

OPEN ACCESS

Citation:
Martínez-Montalvo CM, Ramírez-Daza DJ, Gutiérrez-Rueda LC, Olarte-Parra DF, Otálora-González L. A Forgotten Cause of Recurrent Abdominal Pain: Case Report. Revista. colomb. Gastroenterol. 2024;39(3):344-349. https://doi.org/10.22516/25007440.1110

[1] Internist, Universidad del Rosario. Gastroenterology Fellow, Universidad Nacional de Colombia. Bogotá, Colombia. General Practitioner, Hospital San Juan de Dios. Ituango, Antioquia, Colombia.
[2] Internist, Universidad del Rosario. Fundación Cardioinfantil, La Cardio. Bogotá, Colombia.
[3] Internist, Universidad del Rosario, Hospital Universitario Mayor Méderi. Bogotá, Colombia.
[4] Medical Student, Universidad del Rosario. Bogotá, Colombia.

***Correspondence:** Carlos Mauricio Martínez-Montalvo.
carlitos220792@gmail.com

Received: 21/07/2023
Accepted: 25/09/2024

Abstract

Introduction: Porphyrias are enzymatic disorders of heme synthesis. Acute hepatic porphyrias (AHP) presents with acute neurovisceral symptoms such as abdominal pain, nausea, vomiting, constipation, muscle weakness, neuropathy, tachycardia, and hypertension. 5-aminolevulinic acid dehydratase (ALAD) deficiency is a rare autosomal recessive disorder that results in little or no elevation of porphobilinogen but elevates urinary 5-aminolevulinic acid and coproporphyrin III. There are no records of this type of porphyria in Colombia. Acute management requires comprehensive care, ranging from hemotherapy to liver transplantation. **Case Presentation:** A 24-year-old man with no prior medical history presented with a recurrent and acute episode of abdominal pain associated with changes in urine color, skin lesions, diarrhea, and dysregulation of body temperature. Initial paraclinical workup ruled out common causes of recurrent abdominal pain, with a negative porphobilinogen test, but further testing revealed elevated 5-aminolevulinic acid, confirming the diagnosis of ALAD porphyria. The patient showed improvement with hemotherapy and remission of acute kidney injury. A possible distractor associated with interstitial nephritis and skin manifestations related to nonsteroidal anti-inflammatory drug (NSAID) use was documented. **Conclusions:** ALAD porphyria and all acute hepatic porphyrias should be considered in any patient presenting with unexplained recurrent severe abdominal pain and neuropathy. Despite their relative rarity and complexity, most porphyrias can be easily defined and diagnosed. A common cause of diagnostic delay is the failure to consider porphyria in the differential diagnosis on time. There is still much to learn about ALAD porphyria.

Keywords

Hepatic porphyria, hemin, abdominal pain.

INTRODUCTION

Porphyrias are disorders of heme synthesis involving either inherited or acquired enzyme deficiencies, resulting in an overproduction of heme precursors[1,2]. Heme is an essential molecule that performs a wide range of functions necessary for aerobic life as a cofactor in hemoproteins[3,4].

Porphyrias are classified into acute hepatic porphyrias (AHP) and photosensitive porphyrias. AHPs result from hepatic overproduction of porphyrin precursors, aminolevulinic acid (ALA), and porphobilinogen (PBG), and include acute intermittent porphyria (AIP), variegate porphyria (VP), hereditary coproporphyria (HCP), and 5-aminolevulinate dehydratase deficiency porphyria (ALAD-P). Clinical manifestations are characterized by acute neurovisceral symptoms, such as abdominal pain, nausea, vomiting, constipation, muscle weakness, neuropathy, tachycardia, and hypertension[5]. Symptomatic AHPs affect approximately 1 in 100,000 patients; however, it is estimated that there is a diagnostic delay of more than 15 years from initial presentation[5].

ALAD deficiency is a rare autosomal recessive disorder (with only eight documented cases worldwide) in which

© 2024 Asociación Colombiana de Gastroenterología

enzyme activity is less than 3% of normal[6,7], resulting in little or no elevation of PBG but marked increases in urinary ALA and coproporphyrin III[7]. No cases of this type of porphyria have been documented in Colombia.

The initial approach for an acute porphyria episode is a multidisciplinary management strategy ranging from hospitalization to intensive care, depending on the severity of presentation. Key management principles include avoidance of triggering factors, caloric supplementation, and often hematotherapy[5,8], with liver transplantation as a last resort[8]. Long-term complications include liver disease (cirrhosis and hepatocellular carcinoma), hypertension, and chronic kidney disease.

This case report presents a clinical phenotype of ALAD deficiency porphyria with a history of urine discoloration and recurrent abdominal pain. The initial diagnostic approach was diverted due to a suspected diagnosis of paroxysmal nocturnal hemoglobinuria, further complicated by cutaneous manifestations and interstitial nephritis likely associated with the patient's intake of nonsteroidal anti-inflammatory drugs (NSAIDs) for symptom management. Mutation confirmation was not possible due to discontinuation of follow-up by the patient, but this case contributes to the literature by providing an approach to diagnostic testing and a review of relevant studies.

CASE DESCRIPTION

This case involves a 24-year-old male with no significant medical, toxicological, family, or perinatal history. He presented with a four-day clinical course characterized by severe epigastric and bilateral lumbar pain, described as stabbing and rated 10/10 on the visual analog scale (VAS). These symptoms were associated with changes in urine color (**Figure 1**), pruritic skin lesions, loose stools, emesis episodes, and a documented fever of 38.7°C.

Initial evaluation recorded normal vital signs, diffuse abdominal tenderness on palpation without masses, organomegaly, or peritoneal irritation. Erythematous-edematous pruritic plaques with central pallor were observed, primarily affecting the upper limbs and trunk (**Figure 2**).

Initial laboratory findings showed elevated nitrogenous waste, consistent with acute kidney injury (AKI) classified as KDIGO stage III, a slight increase in lactate dehydrogenase (**Table 1**), and a diffuse increase in liver echogenicity on abdominal ultrasound.

Subsequently, during a follow-up interview, the patient reported outpatient management for recurrent abdominal pain occurring every three months, for which he had self-medicated with N-butylscopolamine bromide and diclofenac without clinical improvement. His recent diclofenac use had increased over the past four days, with an approximate daily dose of 300-400 mg. Outpatient studies included abdominal imaging, which showed no abnormalities, normal PBG levels, a negative autoimmune profile, and negative infectious disease testing, including for human immunodeficiency virus (HIV), hepatotropic viruses, and rapid plasma reagin (RPR). Additionally, electrophoresis and immunofixation were negative, although flow cytometry detected paroxysmal nocturnal hemoglobinuria (PNH) clones in monocytes (12.9%), granulocytes (12.5%), and erythroid cells (1.2%). Given the abdominal pain, acute kidney injury (AKI), and urine discoloration, an episode of PNH with secondary abdominal-renal thrombotic events was initially considered as a diagnostic impression. However, this was ruled out due to the low clinical significance of the small PNH clone populations and the absence of a clinical phenotype consistent with PNH.



Figure 1. Urine discoloration observed in the patient. Source: Author's File.

Due to persistent renal impairment without indications for urgent dialysis, but with reduced urine density and polyuria, a renal biopsy was performed. Histopathology revealed tubulointerstitial nephritis without glomerular involvement or chronic changes. The patient experienced a stationary clinical course with persistent symptoms of limiting visceral pain, associated with somnolence and neuropathy manifesting as dysesthesias in the extremities and tongue. Given the intermittent and temporally related nature of symptoms, as well as a reported association with physical and emotional stress and alcohol intake, additional



Figure 2. Pruritic skin lesions presenting as erythematous-edematous plaques with central pallor, predominantly on the upper limbs and trunk. Source: Author's File.

inpatient studies were conducted. The reports showed elevated urinary ALAD levels, normal porphobilinogen, and elevated 24-hour urinary porphyrins. This clinical presentation was considered compatible with a probable phenotype of ALAD porphyria, leading to treatment initiation with dextrose solution and subsequent administration of human hemin at 4 mg/kg/day (260 mg) via infusion for three days. Improvement was observed in both the reported symptoms and follow-up laboratory values, including a gradual reduction in nitrogenous waste.

The skin manifestations were interpreted as likely related to NSAID-induced skin toxicity or a gastrointestinal infectious agent, and were treated with ampicillin-sulbactam for five days. However, due to spontaneous resolution within 24 hours of admission, a skin biopsy was not pursued. The patient did not continue follow-up, and due to administrative constraints, the mutation panel needed to confirm the type of porphyria could not be completed. Consequently, the case was managed as a probable ALAD porphyria phenotype with initial diagnostic distractions, no PNH phenotype, and complications from NSAID overuse.

DISCUSSION

Acute hepatic porphyrias (AHP) are rare, with estimated prevalence rates of five per 100,000 people[3]. Among these, ALAD deficiency is the rarest form, with only eight cases documented in the literature, and is the least understood type of porphyria[8], with no cases reported in Colombia. The ALAD gene is located on chromosome 9q34 and catalyzes the condensation of two ALA molecules to form PBG[8]. Its mutation, an autosomal recessive disorder, results in enzyme activity of less than 10%. All individuals affected by this mutation experience severe disease onset early in life[3], with all reported cases being male, as is true for this patient, who has had intermittent symptoms since the age of 13.

Clinically, AHPs manifest as intermittent, progressive, colicky abdominal pain radiating to the lumbar region and extremities, along with nausea, vomiting, urine discoloration, and constipation[5,6]. However, diarrhea can sometimes occur[8], as in this case. ALA, PBG, and other hepatic heme precursors can cross the blood-brain barrier, exerting agonistic and antagonistic effects on gamma-aminobutyric acid (GABA) receptors in the central and peripheral nervous systems, leading to delirium, confusion, neuropathies, muscle weakness, seizures, tetraparesis, and respiratory arrest[3,5]. Physical examination may reveal tachycardia and hypertension due to sympathetic hyperactivity during acute attacks[6,7]. These episodes may also be associated with hyponatremia and hypomagnesemia, attributed to a combination of hypovolemia and syndrome of inappropri-

Table 1. Laboratory Report

Laboratory Tests	Patient Values	Reference Values	Unit of Measure
Lactate dehydrogenase	510.31	120-246	U/L
Chloride	102	98-107	mmol/L
Sodium	137	136-145	mmol/L
Potassium	4.32	3.5-5.1	mmol/L
Prothrombin time	10.50	9.9-11.8	s
INR	0.98	0.90-1.15	mg/dL
Partial thromboplastin time	28.7	25.0-31.3	s
Blood urea nitrogen	55.52	9-23	mg/dL
Alkaline phosphatase	94.84	46-116	U/L
Glucose	71	74-106	mg/dL
Total bilirubin	0.61	0.3-1.2	mg/dL
Direct bilirubin	0.24	0-10	mg/dL
Indirect bilirubin	0.37		mg/dL
Glutamic-oxalacetic transaminase	27.95	<34	
Creatinine	11.24	0.6-1.1	
Haptoglobin	138.9	40-280	
Parathyroid hormone	200.1	18.5-88	
Antinuclear antibodies	Negativo		
Anti-DNA antibodies	Negativo		
Hepatitis B	<0.10	0-50	
Hepatitis C antibody	0.08	0-1.0	
HIV 1/2 antibodies	Negativo		
Cardiolipin IgM antibodies	10.543	<20	
Cardiolipin IgG antibodies	1.927	<20	
β_2 glycoprotein IgM	6.537	0-20	
β_2 glycoprotein IgG	1.927	0-20	
Myeloperoxidase	1.6	<20	
δ-aminolevulinic acid	14.1	1-7	

DNA: deoxyribonucleic acid; IgG: immunoglobulin G; IgM: immunoglobulin M; INR: international normalized ratio; HIV: human immunodeficiency virus. Author's own research.

ate antidiuretic hormone secretion. Given its incomplete penetrance, triggering factors—such as excessive alcohol intake, smoking, drug use, fasting, or starvation—are necessary and likely act directly to increase hepatic ALA synthase-1 (ALAS1) mRNA levels, which is rate-limiting in heme production, thereby creating a vicious cycle[3].

Renal disease associated with porphyria can occur in approximately 59% of patients, with an annual decline in glomerular filtration rate of around 1 mL/min per 1.73 m^2. Literature suggests that causes may include endoplasmic reticulum stress mediated by ALA and PBG, apoptosis, and phenotypic changes in proximal tubular epithelial cells leading to renal injury, as well as the action of a variant of the human peptide transporter 2 expressed by proximal tubular cells that mediates ALA reabsorption[3]. Due to the deterioration in renal function, a renal biopsy was performed on this patient, which reported tubulointerstitial nephritis, considered multifactorial: the effect of porphyria combined primarily with chronic NSAID use, with an increase in consumption prior to admission. Liver enzymes may be elevated in 13% of patients during acute attacks, and while cases of cirrhosis have been reported, the cause of elevated liver enzymes and hepatic fibrosis remains poorly understood; thus, abnormal liver enzymes should prompt diagnostic evaluation for alternative etiologies[6].

The diagnosis of symptomatic AHP requires biochemical testing, specifically showing significantly elevated ALA and PBG levels in urine or plasma, except in ALAD porphyria, where PBG levels do not rise significantly[5,8], as was the case with this patient. It is essential to note that, as precursors of porphyrins, ALA and PBG are not included in standard porphyrin tests. Once biochemical testing indicates ALAD porphyria, confirmation can be achieved through genetic testing with gene sequencing; however, it is not recommended for initial screening[6] as it is unnecessary for diagnosis[9]. Genetic testing is, however, valuable for family studies and identifying previously unknown mutations[9]. In this patient's case, diagnostic challenges included a history of paroxysmal nocturnal hemoglobinuria (PNH), which initially led to distraction from considering ALAD porphyria. Although flow cytometry showed positive PNH clones, these were low-quality and lacked a clinical phenotype of the disease, making PNH diagnosis less probable. Additionally, the skin manifestations, initially interpreted as potential NSAID toxicity, further distracted from an early consideration of ALAD porphyria.

Acute management of AHP involves strict avoidance of porphyrinogenic drugs and triggering factors (such as acute illnesses or infections, physical or psychological stress, excessive alcohol intake, and smoking), intensive care monitoring, caloric support (300 grams of glucose per day), effective

pain management, electrolyte correction, and often hematotherapy[5,6]. With early intravenous heme administration, patients begin to improve within 48 hours due to decreased ALAS1 expression[4,5]. The acute phase may involve hyponatremia and hypomagnesemia, attributed to a combination of hypovolemia and syndrome of inappropriate antidiuretic hormone secretion. For seizures associated with AHP, benzodiazepines are considered relatively safe, and levetiracetam is regarded as a safe option[6]. In complex cases, therapeutic options include givosiran, a small interfering RNA that neutralizes excess ALAS1 mRNA in hepatocytes, with liver transplant as a last-resort option[5].

Differential diagnoses should exclude other AHPs (via PBG measurement), lead poisoning, and hereditary tyrosinemia type 1. In this case, lead poisoning was ruled out due to the absence of anemia, basophilic stippling on peripheral smear, and a "lead line" (bluish pigmentation at the gum line and teeth), along with a detailed history ruling out exposure to lead[5].

AHPs are now considered chronic conditions with a significant negative impact on physical and emotional health, resulting in a reduced quality of life[4]. They pose an increased risk of long-term complications, including hepatocellular carcinoma (HCC) and chronic kidney disease[6], requiring annual screening for these complications.

CONCLUSIONS

It is essential to recognize the clinical phenotype to accurately interpret porphyria tests; even if initial tests are negative, further evaluation should be pursued to consider a potential phenotype, such as ALAD porphyria. The impact of neurovisceral manifestations often leads to the concomitant use of analgesic medications that may cause toxicity and should always be considered in patients with these conditions. Despite their relative rarity and complexity, most porphyrias can be readily defined and diagnosed. One of the most common causes of diagnostic delay is failing to consider this entity promptly in differential diagnoses. Much remains to be learned about ALAD porphyria.

Ethical Approval and Participant Consent

This report was approved by the patient and their family.

Consent for Publication

Written informed consent was obtained from the patient for the publication of this case report and the accompanying images.

Data and Material Availability

Data sharing is not applicable to this article as no datasets were generated or analyzed during the current study.

Conflict of Interest

The authors declared no competing interests.

Funding Sources

The authors received no financial support.

Author Contributions

All authors analyzed and interpreted the patient data, wrote the manuscript, reviewed and interpreted the imaging, and contributed to manuscript preparation. All authors read and approved the final manuscript.

REFERENCES

1. Bissell DM, Anderson KE, Bonkovsky HL. Porphyria. N Engl J Med. 2017;377(9):862–72. https://doi.org/10.1056/NEJMra1608634
2. Gerischer LM, Scheibe F, Nümann A, Köhnlein M, Stölzel U, Meisel A. Acute porphyrias - A neurological perspective. Brain Behav. 2021;11(11):e2389. https://doi.org/10.1002/brb3.2389
3. Bonkovsky HL, Dixon N, Rudnick S. Pathogenesis and clinical features of the acute hepatic porphyrias (AHPs). Mol Genet Metab. 2019;128(3):213–8. https://doi.org/10.1016/j.ymgme.2019.03.002
4. de Souza PVS, Badia BML, Farias IB, Pinto WBVR, Oliveira ASB. Acute Hepatic Porphyria: Pathophysiological Basis of Neuromuscular Manifestations. Front Neurosci. 2021;15:715523. https://doi.org/10.3389/fnins.2021.715523
5. Stölzel U, Doss MO, Schuppan D. Clinical guide and update on porphyrias. Gastroenterology. 2019;157(2):365-381.e4. https://doi.org/10.1053/j.gastro.2019.04.050
6. Wang B, Bonkovsky HL, Lim JK, Balwani M. AGA clinical practice update on diagnosis and management of acute hepatic porphyrias: Expert review. Gastroenterology. 2023;164(3):484–91. https://doi.org/10.1053/j.gastro.2022.11.034

7. Wang B, Rudnick S, Cengia B, Bonkovsky HL. Acute hepatic porphyrias: Review and recent progress. Hepatol Commun. 2019;3(2):193–206. https://doi.org/10.1002/hep4.1297
8. Anderson KE, Lobo R, Salazar D, Schloetter M, Spitzer G, White AL, et al. Biochemical diagnosis of acute hepatic porphyria: Updated expert recommendations for primary care physicians. Am J Med Sci. 2021;362(2):113–21. https://doi.org/10.1016/j.amjms.2021.03.004
9. Rigor J, Pinto SA, Martins-Mendes D. Porphyrias: A clinically based approach. Eur J Intern Med. 2019;67:24–9. https://doi.org/10.1016/j.ejim.2019.06.014

https://doi.org/10.22516/25007440.1108

Case report

Response to Cetuximab in Squamous Cell Carcinoma of the Anal Canal After Multiple Lines of Chemotherapy and Immunotherapy

Javier Mauricio Segovia,[1] Sergio Osorio,[2] Erick Andrés Cantor,[1] Luis Eduardo Pino,[1] Henry Alexánder Vargas,[3] John Alejandro Murillo-Silva,[4*] Iván Camilo Triana,[5] Valentina Navas-Cardona.[6]

OPEN ACCESS

Citation:
Segovia JM, Osorio S, Cantor EA, Pino LE, Vargas HA, Murillo-Silva JA, Triana IC, Navas-Cardona V. Response to Cetuximab in Squamous Cell Carcinoma of the Anal Canal After Multiple Lines of Chemotherapy and Immunotherapy. Revista. colomb. Gastroenterol. 2024;39(3):350-355. https://doi.org/10.22516/25007440.1108

[1] Hematologist and Clinical Oncologist, Department of Internal Medicine, ICCAL. Fundación Santa Fe de Bogotá. Bogotá. Bogotá, Colombia.
[2] Oncology Fellow, Department of Internal Medicine, ICCAL. Fundación Santa Fe de Bogotá. Bogotá. Bogotá, Colombia.
[3] Clinical Oncologist, Department of Internal Medicine, ICCAL. Fundación Santa Fe de Bogotá. Bogotá. Bogotá, Colombia.
[4] Rural Practicum in Oncology, Department of Internal Medicine, Fundación Santa Fe de Bogotá. Bogotá, Colombia.
[5] Internal Medicine Resident, Department of Internal Medicine, Fundación Santa Fe de Bogotá. Bogotá, Colombia.
[6] Rural Practicum in Gastroenterology, Department of Internal Medicine, Fundación Santa Fe de Bogotá. Bogotá, Colombia.

***Correspondence:** John Alejandro Murillo-Silva.
john.murillo789@hotmail.com

Received: 21/07/2023
Accepted: 04/12/2023

CC BY NC ND

Abstract

Primary anal cancer accounts for 1% to 3% of gastrointestinal cancers. The most common histology is squamous cell carcinoma, with an incidence of 0.5 to 2 per 100,000 people. The main risk factor is infection with the human papillomavirus, particularly subtypes 16 and 18, which represent 85% to 93% of cases.

Treatment and prognosis depend on the stage of the tumor. Localized tumors can be treated with curative surgery, but locally advanced stages require a combination of chemotherapy and radiation. Advanced-stage tumors (IIIC and IV) have a poor prognosis even with chemotherapy. In recent years, immunotherapy and targeted therapies have shown promise in improving survival for patients with advanced, recurrent, or difficult-to-treat disease.

We present the case of a 69-year-old woman with moderately differentiated squamous cell carcinoma (T2N1M0, stage IIIA) of the anal canal who, after treatment with chemoradiotherapy and checkpoint inhibitors and subsequent disease progression, received targeted therapy (cetuximab) and achieved complete remission with a sustained response for over 18 months.

This case highlights the challenges of treating advanced anal cancer and the potential benefits of targeted therapy, particularly cetuximab, in achieving long-term responses. Further research and large-scale studies are needed to determine the role of targeted therapy and immunotherapy in the treatment of anal canal cancer.

Keywords

Squamous cell carcinoma, cetuximab, chemotherapy, immunotherapy, treatment.

INTRODUCTION

Primary anal canal cancer is a rare condition, accounting for 1% to 3% of all gastrointestinal cancers[1,2]. The most common histological type is squamous cell carcinoma, with an incidence of approximately 0.5 to 2 cases per 100,000 inhabitants. The primary risk factor is infection with the human papillomavirus (HPV), which is responsible for 85% to 93% of all cases, particularly subtypes HPV 16 and 18[2].

Symptoms are nonspecific, including rectal bleeding, pain, and itching, which are associated with a delayed diagnosis. Digital rectal examination is an effective and low-cost method for detecting these lesions, and a definitive diagnosis should be made via biopsy. Studies, including pelvic

© 2024 Asociación Colombiana de Gastroenterología

magnetic resonance imaging with a protocol for the anus, allow for locoregional evaluation and staging, in addition to chest and abdominal CT scans to assess distant extension.

Neoplasms of the anal canal have a prognosis related to tumor staging. Localized stages can be treated with curative surgery; however, in locally advanced stages, the treatment consists of concurrent chemotherapy and radiotherapy with curative intent[3]. Tumors in advanced stages (IIIC and IV) have a poor prognosis, even with chemotherapy management.

In the last 10 years, both immunotherapy and targeted treatments with checkpoint inhibitors have generated new therapeutic perspectives, improving the life expectancy of patients in the context of advanced, recurrent, or refractory disease to conventional treatments.

CASE DESCRIPTION

This case involves a female patient from Bogotá, Colombia, with a history of hypothyroidism on hormone replacement therapy, who, at the age of 69, presented to Fundación Santafé de Bogotá with a clinical picture of several months' duration, characterized by anal pain and changes in the characteristics of her stools. She was evaluated in the emergency department, where a pelvic magnetic resonance imaging scan with an anal protocol was requested. The results reported irregular and transmural thickening of the anal canal walls on the left side, between the 12 o'clock and 6 o'clock positions, with involvement of the external anal sphincter extending to the dentate line and measuring 40 mm in length. Additionally, two prominent lymph nodes were identified in the left internal iliac chain, measuring approximately 11 x 17 mm in diameter, and in the left external iliac chain, measuring 14 x 11 mm (**Figure 1**), which showed a moderate pattern of diffusion restriction with suspicious characteristics (09/03/2019). Contrast-enhanced CT scans of the chest and abdomen were performed, revealing no abnormalities suggestive of metastatic disease, and a biopsy of the described lesion was conducted.

The diagnosis of moderately differentiated keratinizing squamous cell carcinoma of the anal canal with involvement of the distal rectum was confirmed; T2N1M0 (stage IIIA) by September 2019, with immunohistochemistry reporting a programmed cell death ligand 1 (PD-L1) combined positive score (CPS) of 10 points. The patient was referred to the oncology service, and definitive management for locally advanced disease was defined using the Nigro regimen, which consisted of intensity-modulated radiation therapy (IMRT) with a total dose of 50.4 Gy delivered in 1.8 Gy fractions, along with concurrent mitomycin and capecitabine during the radiation treatment days.

Three weeks of treatment were completed, but local toxicity to the radiation therapy led to suspension of treatment. A follow-up pelvic magnetic resonance imaging was performed four months after treatment cessation, which reported persistent irregular thickening of the anal canal walls on the left side, between the 12 o'clock and 6 o'clock positions, with involvement of the internal sphincter, intersphincteric space, external sphincter, and dentate line measuring approximately 35 mm (compared to 40 mm in the previous study), with involvement of the perianal fat and the posterior wall of the adjacent vagina. Compared to the prior study, these findings showed a moderate decrease in the vascularization pattern, with no evidence of lymph nodes or adenopathy in the left inguinal region.



Figure 1. Initial magnetic resonance imaging showing lesions consistent with anal cancer in a locally advanced stage. Source: Author's File.

She was presented in a multidisciplinary meeting with the coloproctology service, and it was determined that an abdominoperineal resection with colostomy would be performed. The procedure was carried out in March 2020, with a pathological report of the surgical specimen indicating ypT4, ypN1a, compatible with the absence of clinical response, leading to a decision for strict follow-up and observation.

In October 2020, a re-evaluation was conducted using a positron emission tomography-computed tomography (PET-CT), which revealed an increase in the density of the left paraaortic retroperitoneal fat, with a hypermetabolic image approximately 15 mm in size and a maximum standardized uptake value (SUV) of 7.32, related to surgical sutures, near the inferior mesenteric vessels, likely tumor-related, with no other pathological findings (**Figure 2**).

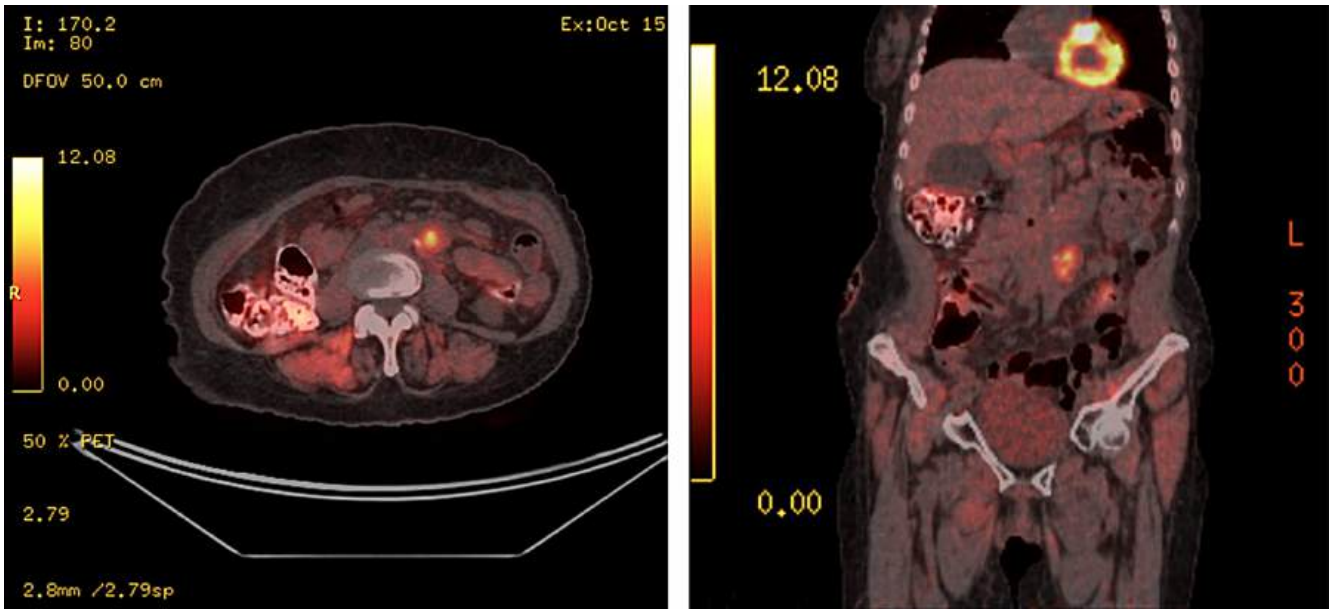

Figure 2. Follow-up positron emission tomography (PET) demonstrating disease progression. Source: Author's File.

Locoregional progression was considered, and treatment was initiated with systemic chemotherapy, adjusting the doses of paclitaxel and carboplatin to 85% (80 mg/m^2). Treatment began in October 2020, and after three cycles of chemotherapy, a pelvic magnetic resonance imaging was performed in December 2020, showing evidence of a solid nodular lesion in the left paraaortic retroperitoneum measuring approximately 15 x 21 mm, with a metastatic neoplastic appearance, located at the level of the distal bifurcation of the abdominal aorta and at the level of the L4 vertebral body. Compared to the previous CT study, this lesion exerted greater compressive effect on the ipsilateral ureter, causing proximal renal obstruction with mild to moderate hydronephrosis.

This was considered a progression of the disease, and a second-line treatment with capecitabine and oxaliplatin was proposed, which began in December 2020. After administering the third cycle, she was presented in a multidisciplinary meeting, where it was determined that, based on the initial pathological report with a CPS of 10, she would benefit from immunotherapy. Pembrolizumab treatment was initiated in February 2021, but she managed to receive only one cycle due to medication availability. Subsequently, the treatment was switched to nivolumab starting in February 2021.

In June 2021, the patient consulted the emergency department due to inflammatory changes in the lower limbs and bilateral edema. A magnetic resonance imaging was conducted, which reported a solid tubular-shaped lesion with lobulated contours, measuring 75 mm in its largest diameter, with intermediate signal in T2-weighted sequences, exhibiting restriction in diffusion-weighted sequences and heterogeneous enhancement post-contrast. This lesion was located adjacent to the right ischiopubic ramus and was associated with adenopathies containing heterogeneous material, likely necrotic, in the right inguinal region (25 mm in diameter). Additionally, she had a known neoplastic lesion in the left retroperitoneum, with significant fibrotic changes and proximal urethral prominence.

The patient was considered to be experiencing disease progression; therefore, she was again presented in a tumor board meeting, where it was decided to initiate treatment with cetuximab as monotherapy in August 2021, given the expression of epidermal growth factor receptor (EGFR) in this type of tumor. The initial dose was set at 400 mg/m^2, followed by 250 mg/m^2 every two weeks until unacceptable toxicity occurred.

During the follow-up, the patient demonstrated adequate tolerance to the treatment, with no need for dose adjustments; however, due to the patient's overall condition, irinotecan was not added to the regimen. No unacceptable toxicity or need for dose adjustment has been reported to date. A PET-CT re-evaluation was conducted in February 2022, six months after the initiation of treatment, which showed evidence of a complete response with no metabolically active lesions in the abdominal and pelvic regions. The management continued with a second re-evaluation PET-CT in February 2023 (**Figure 3**), which indicated no

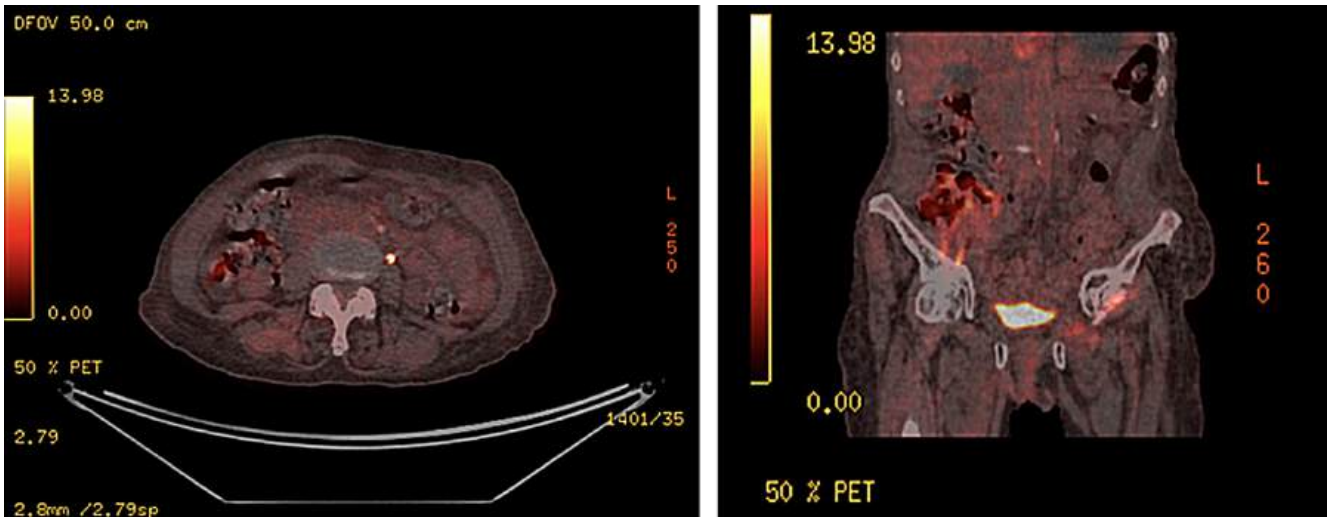

Figure 3. PET re-evaluation after 18 months of treatment showing sustained complete response. Source: Author's File.

evidence of metabolic activity suggesting residual or persistent tumor and clinically noted improvement in pelvic symptoms, limb edema, and general symptoms after more than 18 months of treatment with cetuximab.

Currently, the patient is under oncology follow-up with maintained response, reduction of inflammatory changes, and adequate healing in the genital region (**Figure 4**), with acceptable toxicity and good symptom control.

DISCUSSION

This report presents the case of a patient with chemotherapy-resistant squamous cell carcinoma of the anal canal, with a pathological report positive for PD-L1 by CPS, who, after multiple lines of management and surgical treatment, was determined to receive immunotherapy without achieving the expected responses supported by the relevant studies.

The literature supports the use of cetuximab in tumors with overexpression of the EGFR receptor in scenarios such as squamous cell carcinomas of the head and neck and lung, among others, with promising responses. Furthermore, universal expression of EGFR is known in anal squamous cell carcinoma, as well as the absence of KRAS gene mutations, making the use of this medication plausible in anal squamous cell carcinoma[4].

Current studies of systemic chemotherapy based on platinum, fluoropyrimidine, and mitomycin show overall survival rates between 5 and 21 months[2,4]. The efficacy of cetuximab as monotherapy or in combination with chemotherapy or immunotherapy presents variable results in case reports and retrospective case series, with progression-free survival of 5, 7, 8, and even 10 months[5-8]. A retrospective case series involving 17 patients who received cetuximab as a second or third line of treatment for metastatic disease reported that 35% of patients experienced a reduction in tumor size, 41% had disease progression, and 24% had stable disease, with no patients achieving a complete response. Among the patients who achieved a partial response or stable disease, the median overall survival was 33.8 months, and the median progression-free survival was 12.7 months[9].

In the current case, after several lines of management without adequate responses and with rapid progressions, a sustained complete response has been achieved for more than 18 months, with an appropriate quality of life, proper healing, and control of symptoms related to the primary tumor. This result even exceeds the findings of overall survival and progression-free survival in other studies that use targeted therapy either as a single agent or in combination, such as in the *CARACAS trial*, where patients who received the combination of avelumab and cetuximab achieved a median overall survival of 12.8 months and a median progression-free survival of two months after a median follow-up of 26.7 months[10].



Figure 4. Progression of genital lesions before initiation of cetuximab therapy to the current status. Source: Author's File.

REFERENCES

1. Young AN, Jacob E, Willauer P, Smucker L, Monzon R, Oceguera L. Anal Cancer. Surg Clin North Am. 2020;100(3):629-34. https://doi.org/10.1016/j.suc.2020.02.007
2. Rao S, Guren MG, Khan K, Brown G, Renehan AG, Steigen SE, et al. Anal cancer: ESMO Clinical Practice Guidelines for diagnosis, treatment and follow-up. Ann Oncol. 2021;32(9):1087-100. https://doi.org/10.1016/j.annonc.2021.06.015
3. Durot C, Dohan A, Boudiaf M, Servois V, Soyer P, Hoeffel C. Cancer of the Anal Canal: Diagnosis, Staging and Follow-Up with MRI. Korean J Radiol. 2017;18(6):946-56. https://doi.org/10.3348/kjr.2017.18.6.946
4. Eng C, Messick C, Glynne-Jones R. The Management and Prevention of Anal Squamous Cell Carcinoma. Am Soc

Clin Oncol Educ Book. 2019;39(39):216-25. https://doi.org/10.1200/EDBK_237433
5. Khawandanah M, Baxley A, Pant S. Recurrent metastatic anal cancer treated with modified paclitaxel, ifosfamide, and cisplatin and third-line mitomycin/cetuximab. J Oncol Pharm Pract. 2015;21(3):232-7. https://doi.org/10.1177/1078155214526268
6. Saif MW, Kontny E, Syrigos KN, Shahrokni A. The Role of EGFR Inhibitors in the Treatment of Metastatic Anal Canal Carcinoma: A Case Series. J Oncol. 2011;2011:125467. https://doi.org/10.1155/2011/125467
7. Lukan N, Ströbel P, Willer A, Kripp M, Dinter D, Mai S, et al. Cetuximab-based treatment of metastatic anal cancer: correlation of response with KRAS mutational status. Oncology. 2009;77(5):293-9. https://doi.org/10.1159/000259615
8. Phan LK, Hoff PM. Evidence of clinical activity for cetuximab combined with irinotecan in a patient with refractory anal canal squamous-cell carcinoma: report of a case. Dis Colon Rectum. 2007;50(3):395-8. https://doi.org/10.1007/s10350-006-0786-9
9. Rogers JE, Ohinata A, Silva NN, Mehdizadeh A, Eng C. Epidermal growth factor receptor inhibition in metastatic anal cancer. Anticancer Drugs. 2016;27(8):804-8. https://doi.org/10.1097/CAD.0000000000000383
10. Lonardi S, Prete AA, Morano F, Messina M, Formica V, Corsi DC, et al. Randomized phase II trial of avelumab alone or in combination with cetuximab for patients with previously treated, locally advanced, or metastatic squamous cell anal carcinoma: the CARACAS study. J Immunother Cancer. 2021;9(11):e002996. https://doi.org/10.1136/jitc-2021-002996

https://doi.org/10.22516/25007440.1233

Analysis of additional risk factors for liver fibrosis in diabetic patients with end-stage chronic kidney disease

Jazmín Medalit Lázaro-Sotelo.[1*]

OPEN ACCESS

Citation:
Lázaro-Sotelo JM. Analysis of additional risk factors for liver fibrosis in diabetic patients with end-stage chronic kidney disease. Revista. colomb. Gastroenterol. 2024;39(3):356-357. https://doi.org/10.22516/25007440.1233

[1] Undergraduate Student, School of Human Medicine, Universidad Privada San Juan Bautista. Ica, Peru.

***Correspondence:** Jazmín Medalit Lázaro-Sotelo. lazarojazmin03@gmail.com

Received: 10/06/2024
Accepted: 12/06/2024

Dear Editor,

I would like to provide a contrast to the article by Ismael Yepes-Barreto and colleagues, *Risk Factors for Liver Fibrosis in Diabetic Patients with End-Stage Chronic Kidney Disease*, published in your journal. In their article, they stated that "several associated factors were identified, such as a history of cerebrovascular disease, peripheral vascular disease, body mass index (BMI), total cholesterol, glycosylated hemoglobin, sodium, and aspartate aminotransferase (AST). However, no significant relationship was found between the NAFLD score and the APRI index with the presence of hepatic fibrosis, "suggesting the influence of other factors". The statistical analysis of the data did not include risk factors such as smoking and alcoholism, which are associated with the development of hepatic fibrosis in patients with end-stage chronic kidney disease. Therefore, it would be necessary to include these variables in the study.

It is important to understand these risk factors due to their influence on the development of these diseases, as these habits are not only closely related to the onset of these pathologies but can also exacerbate their effects on health. For example, concerning the influence on the development of diabetes, Rebekka Aarsand and colleagues, in *Tobacco and Diabetes*, indicate that nicotine, a highly toxic component of tobacco smoke, alters the function and quantity of β-cells. This impacts insulin production and glucose regulation, significantly contributing to the development of type 2 diabetes[(1)].

According to Kenji Ito and colleagues, in *The Role of Smoking in the New Onset of Chronic Kidney Disease in a Japanese Population without Previous Chronic Kidney Disease: The Iki Epidemiological Study on Atherosclerosis and Chronic Kidney Disease (ISSA-CKD)*, it was noted that smoking increases the risk of new onset chronic kidney disease. The analysis shows that smokers under 50 years of age had a significantly higher risk ratio than non-smokers, with a ratio of 2.55 and a 95% confidence interval (CI)[(2)]. Similarly, Ayako Matsumoto and colleagues, in their article *Smoking and Progression of Renal Dysfunction: A Longitudinal Cohort Study*, indicate that smoking has a negative effect on the progression of chronic kidney disease and is considered the second most relevant factor for deterioration[(3)]. Additionally, Mahitha Lampimukhi and colleagues, in *A Review of the Incidence and Risk Factors Associated with the Development of Hepatocellular Carcinoma*, state that "heavy smoking causes hepatic accumulation of excess iron, which is the cause of fibrosis and HCC", particularly in Asian countries[(4)].

Regarding the factor of alcoholism, Pietro Vairo and colleagues, in their article *Nutritional Support for Alcoholic Liver Disease*, point out that metabolic syndromes,

© 2024 Asociación Colombiana de Gastroenterología

including diabetes, significantly contribute to the development of hepatic fibrosis. Alcohol increases hepatic gluconeogenesis and glycogenolysis and inhibits insulin secretion, which promotes diabetes *mellitus*. Studies on metabolic-associated fatty liver disease (MAFLD) show that alcohol and metabolic abnormalities are independent factors that worsen hepatic fibrosis. Continuous alcohol consumption and high levels of inflammatory cytokines activate stellate cells, leading to progressive fibrosis[5].

Furthermore, Marija Dukic and her colleagues, in their article *Alcohol, Inflammation, and Microbiota in Alcoholic Liver Disease*, state that excessive alcohol consumption is a significant socioeconomic and health risk factor in today's population. Alcoholic liver disease (ALD) is a multimodal spectrum that includes alcoholic fatty liver disease (AFL) and alcoholic steatohepatitis (ASH), which can lead to hepatic fibrosis and cirrhosis. They conclude that ALD may represent a chronic condition that slowly progresses toward terminal liver damage[6].

Therefore, it is crucial to address this modifiable factor, as alcohol consumption may have played an important role not only in the development of chronic kidney disease but also in the onset of hepatic fibrosis, exacerbating both conditions.

Finally, we sincerely thank the authors for their valuable contributions to medical research. Their work in identifying risk factors for hepatic fibrosis in diabetic patients with end-stage chronic kidney disease is essential for improving knowledge and clinical outcomes. We believe that this study will inspire further research and promote more effective clinical interventions.

REFERENCES

1. Organización Mundial de la Salud. Tabaco y diabetes - Resúmenes de conocimientos de la OMS sobre el tabaco [Internet]. OPS/OMS; 2024 [consultado el 16 de mayo de 2024]. Disponible en: https://www.paho.org/es/documentos/tabaco-diabetes-resumenes-conocimientos-oms-sobre-tabaco
2. Feng L, Chen C, Xiong X, Wang X, Li X, Kuang Q, et al. PS-MPs promotes the progression of inflammation and fibrosis in diabetic nephropathy through NLRP3/Caspase-1 and TGF-β1/Smad2/3 signaling pathways. Ecotoxicol Environ Saf. 2024:273:116102. https://doi.org/10.1016/j.ecoenv.2024.116102
3. Matsumoto A, Nagasawa Y, Yamamoto R, Shinzawa M, Yamazaki H, Shojima K, et al. Cigarette smoking and progression of kidney dysfunction: a longitudinal cohort study. Clin Exp Nephrol. 2024;28(8):793-802. https://doi.org/10.1007/s10157-024-02487-6
4. Lampimukhi M, Qassim T, Venu R, Pakhala N, Mylavarapu S, Perera T, et al. A Review of Incidence and Related Risk Factors in the Development of Hepatocellular Carcinoma. Cureus. 2023;15(11):e49429. https://doi.org/10.7759/cureus.49429
5. Tadokoro T, Morishita A, Himoto T, Masaki T. Nutritional Support for Alcoholic Liver Disease. Nutrients. 2023;15(6):1360. https://doi.org/10.3390/nu15061360
6. Dukić M, Radonjić T, Jovanović I, Zdravković M, Todorović Z, Kraišnik N, et al. Alcohol, Inflammation, and Microbiota in Alcoholic Liver Disease. Int J Mol Sci. 2023;24(4):3735. https://doi.org/10.3390/ijms24043735

Reply to the letter to the editor

Ismael Yepes-Barreto,[1*] Diana Romero,[2] Jorge Coronado-Daza.[3]

OPEN ACCESS

Citation:
Yepes-Barreto I, Romero D, Coronado-Daza J. Reply to the letter to the editor. Revista. colomb. Gastroenterol. 2024;39(3):358. https://doi.org/10.22516/25007440.1267

[1] Physician and PhD. Associate Professor, Universidad de Cartagena. Cartagena, Colombia.
[2] Internist, Clínica San Rafael. Pereira, Colombia.
[3] Nephrologist Internist, MSc, PhD. Full Professor, Universidad de Cartagena. Cartagena, Colombia.

***Correspondence:** Ismael Yepes-Barreto
ismayep@yahoo.com

Received: 08/08/2024
Accepted: 10/08/2024

Dear Editor,

Regarding the letter to the editor about our article, *Risk Factors for Liver Fibrosis in Diabetic Patients with End-Stage Chronic Kidney Disease*[(1)], we would like to make the following points:

As highlighted in your letter, alcohol and tobacco are potential contributors to the progression of both chronic liver and kidney diseases. Our study collected data cross-sectionally from a group of patients enrolled in a chronic dialysis program, who were under multidisciplinary medical care. At the time of data collection, reported alcohol and tobacco use among these patients was nil. This finding may be attributed to the continuous healthcare provided, which emphasizes healthy lifestyle habits and highlights the potentially deleterious effects of these habits on their underlying health conditions. As a result, the patients may have ceased alcohol and tobacco use well before their inclusion in the study.

We did not consider it appropriate to gather this information retrospectively due to the challenge of accurately measuring exposure levels and the additional risk of reporting bias if patients felt they might be judged by healthcare personnel for disclosing substance use. The absence of this information in our study does not reflect a disregard for the potential impact of alcohol and tobacco on the progression of liver disease. Instead, it is due to the study's methodological design, which precluded a precise examination of this association.

We appreciate your comments and will take them into consideration for future research in this area.

REFERENCE

1. Yepes-Barreto I, Romero-Flórez D, Coronado-Daza J. Factores de riesgo para fibrosis hepática en pacientes diabéticos con enfermedad renal crónica terminal. Revista colomb Gastroenterol. 2023;38(3):278–289. https://doi.org/10.22516/25007440.1061

© 2024 Asociación Colombiana de Gastroenterología